This is a digital copy of a book that was preserved for generations on library shelves before it was carefully scanned by Google as part of a project to make the world's books discoverable online.

It has survived long enough for the copyright to expire and the book to enter the public domain. A public domain book is one that was never subject to copyright or whose legal copyright term has expired. Whether a book is in the public domain may vary country to country. Public domain books are our gateways to the past, representing a wealth of history, culture and knowledge that's often difficult to discover.

Marks, notations and other marginalia present in the original volume will appear in this file - a reminder of this book's long journey from the publisher to a library and finally to you.

Usage guidelines

Google is proud to partner with libraries to digitize public domain materials and make them widely accessible. Public domain books belong to the public and we are merely their custodians. Nevertheless, this work is expensive, so in order to keep providing this resource, we have taken steps to prevent abuse by commercial parties, including placing technical restrictions on automated querying.

We also ask that you:

+ *Make non-commercial use of the files* We designed Google Book Search for use by individuals, and we request that you use these files for personal, non-commercial purposes.
+ *Refrain from automated querying* Do not send automated queries of any sort to Google's system: If you are conducting research on machine translation, optical character recognition or other areas where access to a large amount of text is helpful, please contact us. We encourage the use of public domain materials for these purposes and may be able to help.
+ *Maintain attribution* The Google "watermark" you see on each file is essential for informing people about this project and helping them find additional materials through Google Book Search. Please do not remove it.
+ *Keep it legal* Whatever your use, remember that you are responsible for ensuring that what you are doing is legal. Do not assume that just because we believe a book is in the public domain for users in the United States, that the work is also in the public domain for users in other countries. Whether a book is still in copyright varies from country to country, and we can't offer guidance on whether any specific use of any specific book is allowed. Please do not assume that a book's appearance in Google Book Search means it can be used in any manner anywhere in the world. Copyright infringement liability can be quite severe.

About Google Book Search

Google's mission is to organize the world's information and to make it universally accessible and useful. Google Book Search helps readers discover the world's books while helping authors and publishers reach new audiences. You can search through the full text of this book on the web at `http://books.google.com/`

B 3 9015 00212 221 9
University of Michigan – BUHR

Digitized by Google



Digitized by Google

610.5
P3
S7
L8t
S-S

Digitized by Google

Digitized by Google

12351

TRANSACTIONS

LIBRARY OF THE UNIVERSITY OF ARKANSAS

OF THE

PATHOLOGICAL SOCIETY OF LONDON.

VOLUME TWENTY-SECOND.

COMPRISING THE REPORT OF THE PROCEEDINGS FOR THE SESSION 1870-71.

LONDON:
PRINTED FOR THE SOCIETY BY J. E. ADLARD, BARTHOLOMEW CLOSE.
1871.

Digitized by Google

THE present publication, being the Twenty-second Volume of Transactions, constitutes the Twenty-fifth published Annual Report of the Pathological Society's Proceedings.

The COUNCIL think it right to repeat, that the exhibitors are alone responsible for the descriptions given of the Specimens exhibited by them, the only change made in the Reports furnished by the authors being such verbal alterations as were absolutely necessary.

53, BERNERS STREET, OXFORD STREET;
October, 1871.

Digitized by Google

TABLE OF CONTENTS

OF VOLUME XXII.

	PAGE
Lists of Presidents and of Officers and Members during the Session 1870-71	iv—xxvi
List of Specimens Exhibited during the Session 1870-71	xxvii
List of Specimens reported on by the Committee on Morbid Growths	xxxviii
List of Plates	xxxix
List of Woodcuts	xli
Report of the Committee on Lardaceous Disease	1
Diseases, etc., of the Nervous System	13
Diseases, etc., of the Organs of Respiration	33
Diseases, etc., of the Organs of Circulation	85
Diseases, etc., of the Organs of Digestion	128
Diseases, etc., of the Genito-Urinary Organs	171
Diseases, etc., of the Osseous System	188
Diseases, etc., of the Organs of Special Sense	218
Tumours	229
Diseases, etc., of the Ductless Glands	274
Diseases, etc., of the Skin	305
Miscellaneous Specimens	320
Specimens from the Lower Animals	347
Index	355

Digitized by Google

Presidents of the Society.

ELECTED

1846 CHARLES J. B. WILLIAMS, M.D. F.R.S.
1848 CHARLES ASTON KEY.
1850 PETER MERE LATHAM, M.D.
1852 CÆSAR H. HAWKINS, F.R.S.
1853 BENJAMIN GUY BABINGTON, M.D., F.R.S.
1855 JAMES MONCRIEFF ARNOTT, F.R.S.
1857 SIR THOMAS WATSON, BART., M.D., F.R.S.
1859 SIR WILLIAM FERGUSSON, BART., F.R.S.
1861 JAMES COPLAND, M.D., F.R.S.
1863 PRESCOTT G. HEWETT.
1865 THOMAS BEVILL PEACOCK, M.D.
1867 JOHN SIMON, D.C.L., F.R.S.
1869 RICHARD QUAIN, M.D., F.R.S.

Digitized by Google

OFFICERS AND COUNCIL

OF THE

Pathological Society of London,

ELECTED AT

THE GENERAL MEETING, JANUARY 3RD, 1871.

President.

JOHN HILTON, F.R.S.

Vice-Presidents.

EDWARDS CRISP, M.D.
HERBERT DAVIES, M.D.
RICHARD QUAIN, M.D., F.R.S.
SAMUEL WILKS, M.D., F.R.S.
JOHN COOPER FORSTER.
JOHN GAY.
TIMOTHY HOLMES.
JOHN SIMON, D.C.L., F.R.S.

Treasurer.

CHARLES MURCHISON, M.D., LL.D., F.R.S.

Council.

FRANCIS E. ANSTIE, M.D.
H. CHARLTON BASTIAN, M.D., F.R.S.
WILLIAM H. BROADBENT, M.D.
WILLIAM CAYLEY, M.D.
WILLIAM CHOLMELEY, M.D.
WILLIAM SELBY CHURCH, M.D.
CHARLES HILTON FAGGE, M.D.
THOMAS H. GREEN, M.D.
WILLIAM MARCET, M.D., F.R.S.
ROBERT MARTIN, M.D.
FREDERICK ROBINSON, M.D.
THOMAS J. ASHTON.
JOHN COUPER.
JOHN CROFT.
ARTHUR E. DURHAM.
GEORGE LAWSON.
CHARLES F. MAUNDER.
THOMAS PICKERING PICK.
WILLIAM POTTS.
WILLIAM SQUIRE.

Honorary Secretaries.

WILLIAM HOWSHIP DICKINSON, M.D.
JOHN WHITAKER HULKE, F.R.S.

Trustees.

THOS. BEVILL PEACOCK, M.D.
RICHARD QUAIN, M.D.
GEORGE POLLOCK.

Digitized by Google

Digitized by Google

*** *Members are requested to indicate to the Secretaries corrections when necessary.*

LIST OF MEMBERS OF THE SOCIETY.

Honorary Members.

ANDRAL, G., M.D., late Professor in the Faculty of Medicine, Paris.

ARNOTT, JAMES MONCRIEFF, F.R.S., Chapel House, Lady Bank, Fifeshire.

BERNARD, CLAUDE, M.D., Professor of Physiology in the Faculty of Medicine, Paris.

BILLROTH, THEODOR, M.D., Professor of Surgery in the University of Vienna.

BRUECKE, ERNST, M.D., Professor of Physiology in the University of Vienna.

CRUVEILHIER, J. C., M.D., late Professor in the Faculty of Medicine, Paris.

HELMHOLTZ, H., M.D., Professor of Physiology in the University of Heidelberg.

HENLE, J., M.D., Professor of Anatomy and Physiology in the University of Göttingen.

LOUIS, P. C. A., M.D., Honorary Physician to the Hôtel-Dieu, 8, Rue Menars, Paris.

LUDWIG, C., M.D., Professor of Physiology in the University of Leipzig.

ROKITANSKY, CARL, M.D., Professor of Pathological Anatomy in the University of Vienna.

STOKES, WILLIAM, M.D., D.C.L., LL.D., F.R.S., M.R.I.A., Regius Professor of Physic in the University of Dublin, Physician in Ordinary to the Queen in Ireland.

VIRCHOW, RUDOLF, M.D., Professor of Pathological Anatomy in the University of Berlin.

VOGEL, JULIUS, M.D., Professor of Pathological Anatomy in the University of Halle.

EXPLANATION OF ABBREVIATIONS.

O. M.—Original Member.
Pres.—President.
T.—Treasurer.
V.-P.—Vice-President.
S.—Secretary.
C.—Member of Council.

Those marked thus (†) have paid Composition Fee for Annual Subscriptions.
Those marked thus (‡) have paid Composition Fee for Transactions.

GENERAL LIST OF MEMBERS.

Elected

1858 ACLAND, HENRY WENTWORTH, M.D., F.R.S., Physician to the Radcliffe Infirmary, Oxford.

‡1866 ADAMS, ARTHUR BAYLEY.

1869 ADAMS, JAMES EDWARD, Assistant Surgeon to the London Hospital, 10, Finsbury-circus, E.C.

Digitized by Google

Elected

O. M. ADAMS, WILLIAM, Surgeon to the Royal Orthopædic Hospital, 5, Henrietta-street, Cavendish-square, W. (C. 1851-4. V.-P. 1867-9.)

1859 ADAMS, WILLIAM, 37, Harrington-square, N.W.

1848 AIKIN, CHARLES A., 7, Clifton-place, Sussex-square, Hyde-park, W. (C. 1864-6.)

1871 AIR, A. CUMMINGS, 33, Lorrimore-square, Walworth, S.E.

1869 ALLBUTT, THOMAS CLIFFORD, M.D., Physician to the Leeds General Infirmary, 38, Park-square, Leeds.

1868 ANDERSON, J. FORD, M.D., 28, Buckland-crescent, Belsize-park, N.W.

1859 ANDREW, EDWIN, M.D., Windsor-house, Castle-street, Shrewsbury.

1863 ANDREW, JAMES, M.D., Physician to St. Bartholomew's Hospital, 22, Harley-street, W. (C. 1868-70.)

1858 ANSTIE, FRANCIS E., M.D. (C.), Assistant-Physician to the Westminster Hospital, 16, Wimpole-street, W. (C. 1869-71.)

1866 ARNOTT, HENRY, Assistant-Surgeon to St. Thomas's Hospital, 6, Nottingham-place, Marylebone-road, W.

1851 ASHTON, T. J. (C.), Consulting Surgeon to the St. Marylebone Infirmary, 31, Cavendish-square, W. (C. 1871.)

1858 AVENT, NICHOLAS.

1863 BAGSHAWE, FREDERICK, M.A., M.D., 16, Warrior-square, Hastings.

1864 BAKER, WILLIAM MORRANT, Assistant-Surgeon to, and Lecturer on Physiology and Warden of the College at, St. Bartholomew's Hospital, E.C.

‡1856 BALDING, DANIEL BARLEY, Royston, Herts.

1850 BALLARD, THOMAS, M.D., 10, Southwick-place, Hyde-park, W. (C. 1859-61.)

1851 BARCLAY, A. WHYTE, M.D., Physician to St. George's Hospital, 23A, Bruton-street, Berkeley-square, W. (C. 1858-61.)

1871 BARNES, ROBERT, M.D., Obstetric Physician to St. Thomas's Hospital; 31, Grosvenor-street, W.

1853 BARTLETT, WILLIAM, Surgeon to the Kensington Dispensary, Ladbroke Lodge, Ladbroke-square, Notting-hill, W.

1862 BARRATT, JOSEPH GILLMAN, M.D., Accoucheur to the St. George's and St. James's Dispensary, 8, Cleveland-gardens, Bayswater, W.

1853 BARWELL, RICHARD, Surgeon to the Charing Cross Hospital, 32, George-street, Hanover-square, W. (C. 1862-4.)

1867 BASAN, HORACE, L.R.C.P. Ed., Prebyn, Bedford.

1857 BASHAM, WILLIAM R., M.D., Physician to the Westminster Hospital, 17, Chester-street, Belgrave-square, S.W.

1861 BASTIAN, H. CHARLTON, M.A., M.D., F.R.S. (C.), Professor of Pathological Anatomy in University College, and Physician to University College Hospital, 20, Queen Anne-street, W. (C. 1869-71.)

1870 BÄUMLER, CHRISTIAN G. H., M.D., 10, Finsbury-place-north, E.C.

1871 BAXTER, EVAN BUCHANAN, M.D., King's College, Strand, W.C.

Digitized by Google

Elected

1852 BEALE, LIONEL S., M.B., F.R.S., Physician to King's College Hospital, 61, Grosvenor-street, W. (C. 1858-9.)

1856 BEALEY, ADAM, M.D., M.A., Birch-lea, Harrogate.

1870 BECK, MARCUS, M.S., Surgeon to the St. George's and St. James's Dispensary, 30, Wimpole-street, Cavendish-square, W.

1853 BECK, THOMAS SNOW, M.D., F.R.S., 7, Portland-place, W.

1865 BEEBY, WALTER, M.D., Bromley, Kent.

1865 BEIGEL, HERMANN, M.D., Physician for the Department of Skin Diseases at the Charing Cross Hospital, and Physician to the St. Pancras Dispensary, 39, Queen's-road, Brownswood-park, N.

1865 BELLAMY, EDWARD, Surgeon to the St. George's and St. James's Dispensary, Assistant-Surgeon to the Charing Cross Hospital, 59, Margaret-street, Cavendish-square, W.

1847 BENNET, JAMES HENRY, M.D., Weybridge, Surrey.

O. M. BENNETT, JAMES RISDON, M.D. (formerly V.-P.), Consulting Physician to St. Thomas's Hospital, and to the City of London Hospital for Diseases of the Chest, 15, Finsbury-square, E.C. (C. 1846-8. V.-P. 1856-9.)

‡1856 BICKERSTETH, EDWARD R., Surgeon to the Liverpool Royal Infirmary, 2, Rodney-street, Liverpool.

1850 BIRKETT, EDMUND LLOYD, M.D., Physician to the City of London Hospital for Diseases of the Chest, 48, Russell-square, W.C. (C. 1856-7.)

O. M. BIRKETT, JOHN, Surgeon to Guy's Hospital, 59, Green-street, Grosvenor-square, W. (C. 1851. V.-P. 1860-2.)

1865 BISSHOPP, JAMES, Cheshunt, Herts.

1853 BLACK, CORNELIUS, M.D., Physician to the Chesterfield Dispensary, St. Mary's-gate, Chesterfield.

1850 BLAGDEN, ROBERT, Stroud, Gloucestershire.

1863 BLANCHET, JEAN B., M.D., M.S., Montreal, Quebec, Canada.

1869 BOURNE, WALTER, M.D.

1861 BOWER, RICHARD NORRIS, 14, Doughty-street, Mecklenburg-square, W.C.

1851 BOWMAN, WILLIAM, F.R.S., Surgeon to the Royal Ophthalmic Hospital, 5, Clifford-street, Bond-street, W. (C. 1855-6.)

1863 BRAINE, FRANCIS WOODHOUSE, 56, Maddox-street, Hanover-square, W.

‡1867 BRIDGEWATER, THOMAS, M.B. Lond., Harrow-on-the-hill, Middlesex.

1868 BRIGHT, G. C., M.B., 8, Southwick-crescent, Hyde-park, W.

1857 BRISCOE, JOHN, 12, Broad-street, Oxford.

†1851 BRISTOWE, JOHN S., M.D., Physician to, and Lecturer on Pathology at, St. Thomas's Hospital, 11, Old Burlington-street, W. (C. 1854-8. S. 1861-4. C. 1865-7. V.-P. 1868-70.)

1860 BROADBENT, WILLIAM HENRY, M.D. Lond. (C.), Assistant-Physician to St. Mary's Hospital, and Physician to the London Fever Hospital, 44 Seymour-street, Portman-square, W. (C. 1871.)

1852 BRODHURST, BERNARD E., Orthopædic Surgeon to St. George's Hospital, and Assistant-Surgeon to the Royal Orthopædic Hospital, 20, Grosvenor-street, W. (C. 1862-4.)

Digitized by Google

Elected

1863 BRODIE, GEORGE BERNARD, M.D., 56, Curzon-street, May-fair, W.

1846 BROOKE, CHARLES, M.B., F.R.S., Consulting Surgeon to the Westminster Hospital, 16, Fitzroy-square, W. (C. 1853-5. V.-P. 1864-5.)

1865 BROWN, AUGUSTUS, M.D., 30, Belitha-villas, Barnsbury-park, N.

1866 BROWNE, J. LENNOX, 41, Welbeck-street, Cavendish-square, W.

O. M. BROWNE, JOSEPH HULLETT, M.D., Physician to the St. Pancras Royal General Dispensary, 55, Gordon-square, W.C. (C. 1859-60.)

1855 BRYANT, THOMAS, Surgeon to Guy's Hospital, 2, Finsbury-square, E.C. (C. 1863-6.)

1854 BUCHANAN, GEORGE, M.D., Medical Inspector to the Privy Council, 24, Nottingham-place, Marylebone-road, W. (C. 1864-6.)

1862 BUCHANAN, ALBERT, M.B. Lond., 382, Camden-road, N.

1858 BUDD, GEORGE, M.D., F.R.S., Ashleigh, Barnstaple. (C. 1862-4.)

1860 BURTON, ALFRED, 13, Dover-street, Piccadilly, W.

1853 BURTON, JOHN M., Lee-park-lodge, Lee, Kent.

O. M. BUSK, GEORGE, F.R.S. (late V.-P.), Consulting Surgeon to the "Dreadnought" Hospital for Seamen, Greenwich, 32, Harley-street, Cavendish-square, W. (C. 1846-8. V.-P. 1858-60.)

1866 BUTT, WILLIAM FREDERICK, 12, South-street, Park-lane, W.

1856 BUZZARD, THOMAS, M.D., Physician to the National Hospital for the Epileptic and Paralysed, 56, Grosvenor-street, W. (C. 1869-70.)

1856 CALLENDER, G. W., F.R.S., Surgeon to St. Bartholomew's Hospital, 47, Queen Anne-street, Cavendish-square, W. (C. 1865-9.)

‡1863 CAMPBELL, CHARLES, M.D., Kingston, Jamaica [Agent: Mr. H. K. Lewis, 136, Gower-street].

†O.M. CAMPS, WILLIAM, M.D. (C. 1856-9.)

1850 CANTON, EDWIN, Surgeon to the Charing Cross Hospital, 30, Montague-place, Russell-square, W.C. (C. 1853-4.)

‡1855 CARPENTER, ALFRED, M.D., High-street, Croydon.

1848 CARPENTER, WILLIAM GUEST, Amersham, Bucks.

1871 CARTER, CHARLES HENRY, M.B., B.S. Lond., Curator of Museum, University College, 57, Welbeck-street, Cavendish-square, W.

1855 CARTER, H. V., M.D., Professor of Anatomy and Physiology, Grant Medical College, Bombay.

†1868 CAVAFY, JOHN, M.B., Lecturer on Physiological Histology at St. George's Hospital, 13, Arlington-street, Piccadilly, W.

1864 CAY, CHARLES VIDLER, Coldstream Guards, Wrexham Park, Slough.

1863 CAYLEY, WILLIAM, M.D. (C.), Assistant-Physician to, and Lecturer on Pathological Anatomy and Histology at, the Middlesex Hospital, 58, Welbeck-street, Cavendish-square, W. (C. 1870-1).

1869 CHAFFERS, EDWARD, Keighley, Yorkshire.

1849 CHALK, WILLIAM OLIVER, 3, Nottingham-terrace, Regent's-park, N.W. (C. 1856-7.)

1867 CHATER, SIDNEY, 18, St. Helen's-place, E.C.

Digitized by Google

Elected

1870 CHEADLE, WALTER BUTLER, M.D., Assistant-Physician to St. Mary's Hospital, 2, Hyde-park-place, Cumberland-gate, W.

O. M. CHEVERS, NORMAN, M.D., India. (C. 1848.)

‡1858 CHILD, GILBERT W., The Elms, Great Missenden, Bucks.

1855 CHOLMELEY, WILLIAM, M.D. (C.), Physician to the Great Northern Hospital, 40, Russell-square, W.C. (C. 1871.)

1871 CHRISTIE, THOMAS BEATH, M.D., Superintendent of the Royal India Asylum, Ealing, Middlesex.

1865 CHURCH, WILLIAM SELBY, M.D. (C.), Assistant-Physician to St. Bartholomew's Hospital, 2, Upper George-street, Bryanston-square, W. (C. 1871.)

†1868 CHURCHILL, F., M.B., Surgeon to the Westminster General Dispensary, 19A, Great George-street, Westminster, S.W.

1861 CLAPTON, EDWARD, M.D., Physician to St. Thomas's Hospital, 10A, St. Thomas's-street, Southwark, S.E.

1854 CLARK, ANDREW, M.D., Physician to the London Hospital, 16, Cavendish-square, W. (C. 1862-5.)

1865 CLARKE, JACOB LOCKHART, M.D., F.R.S, 60, Warwick-street, Belgravia, S.W. (C. 1868-70.)

1850 CLARKE, JOHN, M.D., Obstetric Physician to St. George's Hospital, and Physician-Accoucheur to the General Lying-in Hospital, 42, Hertford-street, May-fair, W. (C. 1858.)

1867 CLARKE, WILLIAM FAIRLIE, M.A., Assistant-Surgeon to Charing Cross Hospital, and to the Central London Ophthalmic Hospital, 1, Curzon-street, May-fair, W.

‡1865 COATES, CHARLES, M.D., Physician to the Bath United General Hospital, 10, Circus, Bath.

O. M. COCK, EDWARD, Consulting Surgeon to Guy's Hospital, 36, Dean-street South, Tooley-street, S.E. (C. 1846-8. V.-P. 1856.)

1858 COCKERTON, RICHARD, Surgeon to the Kensington Dispensary, 83, Cornwall-gardens, Queen's Gate, W.

1856 COCKLE, JOHN, M.D., M.A., Physician to the Royal Free Hospital, 7, Suffolk-place, Pall Mall, S.W.

O. M. COHEN, DANIEL WHITAKER, M.D., South-bank, North Down-lane, Bideford, Devon.

1866 COLES, GEORGE CHARLES, Surgeon to the Infirmary for Epilepsy and Paralysis, 20, Great Coram-street, Russell-square, W.C.

1869 COLLEY, J. N. C. DAVIES, M.B., Assistant-Surgeon to Guy's Hospital, S.E.

1868 CONNOR, JAMES HENTHORNE TODD, St. John's-hill, Battersea Rise, S.W.

1858 COOKE, ROBERT THOMAS, Surgeon to the Scarborough Dispensary, 15, St. Nicholas Cliff, Scarborough, Yorkshire.

1867 COOKE, T. C. WREDEN, Surgeon to the Cancer Hospital, 76, Upper Berkeley-street, W.

1866 COOMBS, ROWLAND HILL, Mill-street, Bedford.

1851 COOPER, WILLIAM WHITE, Consulting Ophthalmic Surgeon to St. Mary's Hospital, 19, Berkeley-square, W. (C. 1860-2.)

Digitized by Google

Elected

1853 CORNISH, WILLIAM ROBERT, Madras.

1859 COULSON, WALTER J., Surgeon to the Lock Hospital, 29, St. James's-place, S.W.

O. M. COULSON, WILLIAM, Consulting Surgeon to St. Mary's Hospital, 1, Chester-terrace, Regent's-park, W. (C. 1850-3. V.-P. 1862-3.)

†1861 COUPER, JOHN (C.), Surgeon to the London Hospital, 80, Grosvenor-street, Grosvenor-square, W. (C. 1870-1.)

O. M. CRISP, EDWARDS, M.D. (V.P.), 29, Beaufort-street, Chelsea, S.W. (C. 1846-7. V.-P. 1870-1.)

1848 CRITCHETT, GEORGE, Surgeon to the Royal London Ophthalmic Hospital, Moorfields, 21, Harley-street, W. (S. 1849. C. 1851, 1858-9. V.-P. 1866-7.)

1856 CROFT, JOHN (C.), Surgeon to St. Thomas's Hospital, 61, Brook-street, Grosvenor-square, W. (C. 1870-1.)

‡1866 CROMARTY, JAMES PATTISON, Civil Surgeon, Tavoy, Burmah. [Agents: Messrs. FERGUSSON & Co., 77, Clive-street, Calcutta.]

1861 CROSBY, THOMAS BOOR, M.D., 21, Gordon-square, W.C.

1854 CROSS, ROBERT, M.D., Physician to the Brewer's-court Dispensary, 42, Craven-street, Strand, W.C.

1864 CRUCKNELL, HENRY, M.B., Physician to the Royal Infirmary for Diseases of the Chest, City-road, 58, Welbeck-street, Cavendish-square, W.

1871 CUMBERBATCH, ELKIN, St. Bartholomew's Hospital.

1858 CUMBERBATCH, LAURENCE T., M.D., 25, Cadogan-place, Sloane-street, S.W.

1855 CURLING, THOMAS BLIZARD, F.R.S., Consulting Surgeon to the London Hospital, 39, Grosvenor-street, W. (C. 1857-60. V.-P. 1866-8.

‡1865 CURRAN, WILLIAM, M.D., Assistant-Surgeon, 88th Regiment (Connaught Rangers), Ramel Pindie, India. [Agent: Mr. H. K. Lewis, 136, Gower-street.]

1863 DANE, THOMAS, 24, New Finchley-road, N.W.

O. M. DAVIES, HERBERT, M.D. (V.-P.), Consulting Physician to the Infirmary for Asthma, &c., and Physician to the London Hospital, 23, Finsbury-square, E.C. (C. 1849-50. V.-P. 1871.)

1847 DAVIS, JOHN HALL, M.D., Physician-Accoucheur to the Middlesex Hospital, and to the Royal Maternity Charity, 24, Harley-street, Cavendish-square, W. (C. 1852-3.)

‡1859 DAVIS, FRANCIS WILLIAM, R.N., 11 and 12, Love-lane, Aldermanbury, E.C.

1867 DAVY, RICHARD, Assistant-Surgeon to the Westminster Hospital, 33, Welbeck-street, Cavendish-square, W.

O. M. DAY, GEORGE E., M.D., F.R.S., Emeritus Professor of Medicine in the University of St. Andrew's, Furzewell House, Torquay. (C. 1846-7.)

1866 DAY, WILLIAM HENRY, M.D., Physician to the Samaritan Free Hospital, and to the Margaret-street Infirmary for Consumption, 10, Manchester-square, W.

Digitized by Google

Elected

1865 De Morgan, Campbell, F.R.S., Surgeon to the Middlesex Hospital, 29, Seymour-street, Portman-square, W. (C. 1867-9.)

1863 Devereux, Daniel, Tewkesbury.

1856 Dick, H., M.D., 59, Wimpole-street, Cavendish-square, W.

1871 Dickinson, Edward Harriman, M.B., St. George's Hospital, S.W.

1858 Dickinson, William Howship, M.D. (Hon. Secretary), Physician to the Hospital for Sick Children, Assistant-Physician and Lecturer on Pathology to St. George's Hospital, 11, Chesterfield-street, May-fair, W. (C. 1866-8. S. 1869-71.)

1868 Dickson, John Thompson, M.B., B.A., Lecturer on Mental Diseases at Guy's Hospital; 59, Queen Anne-street, W.

O. M. Dixon, James, Consulting Surgeon to the Royal Ophthalmic Hospital, Moorfields, 29, Lower Seymour-street, Portman-square, W. (C. 1852-6. V.-P. 1860-2.)

1870 Donkin, Arthur Scott, M.D., Physician to the Sunderland Infirmary and Dispensary, 30, Villiers-street, Sunderland.

†1866 Down, John Langdon H., M.D., Physician to the London Hospital, 39, Welbeck-street, Cavendish-square, W.

1866 Drewry, George Overend, M.D., Walsall, Stafford.

1865 Duckworth, Dyce, M.D., Assistant-Physician to St. Bartholomew's Hospital, 11, Grafton-street, Bond-street, W.

1863 Dudfield, Thomas Orme, M.D., 8, Upper Phillimore-place, Kensington, W.

1847 Dudgeon, Robert E., M.D., 53, Montagu-square, W.

1852 Duff, George, M.D., High-street, Elgin.

1865 Duffin, Alfred Baynard, M.D., Physician to King's College Hospital, 18, Devonshire-street, Portland-place, W.

1868 Duke, Oliver Thomas, M.B., India.

1871 Dukes, Clement, M.B., B.S., Horton-crescent, Rugby.

1861 Dunn, Robert William, 13, Surrey-street, Strand, W.C.

1865 Du Pasquier, Claudius Francis, Surgeon Apothecary to the Queen, 62, Pall Mall, S.W.

1858 Durham, Arthur Edward (C.), Assistant-Surgeon to Guy's Hospital, 82, Brook-street, Grosvenor-square, W. (C. 1869-71.)

1848 Eden, Thomas E., Surgeon-Dentist to the Farringdon General Dispensary, Auckland-house, Lower Norwood, Surrey, S.E.

1867 Edis, Arthur W., M.D., Assistant-Physician to the Hospital for Women, 23, Sackville-street, Piccadilly, W.

1867 Ellis, James, M.D., 2, Langton-villas, St. John's-road, Blackheath, S.E.

1847 Ellis, James, Sudbrook-park, Richmond, Surrey. [Agent: Mr. Tweedie, 337, Strand.]

1846 Erichsen, John, Surgeon to University College Hospital, 6, Cavendish-place, Cavendish-square, W. (C. 1849-51. V.-P. 1863-4.)

1853 Evans, Conway, M.D., 5, Tavistock-street, Covent-garden. (C. 1867-8.)

‡1859 Ewens, John, Barton Lodge, Cerne Abbas, Dorset.

Digitized by Google

Elected

1864 Fagge, Charles Hilton, M.D. (C.), Assistant-Physician to Guy's Hospital, 11, St. Thomas's-street, Southwark, S.E. (C. 1870-71.)

1862 Farquharson, Robert, M.D.

1863 Fenwick, Samuel, M.D., Assistant-Physician to the London Hospital, 29, Harley-street, W.

1848 Fergusson, Sir William, Bart., F.R.S., Surgeon to King's College Hospital, 16, George-street, Hanover-square, W. (C. 1849-50. V.-P. 1851-8. *Pres.* 1859-60. V.-P. 1861.)

1846 Fincham, George T., M.D., Physician to the Westminster Hospital, 13, Belgrave-road, S.W. (C. 1855.)

1870 Fish, John Crockett, M.B., Physician to the Royal Hospital for Diseases of the Chest, City-road, 92, Wimpole-street, W.

1854 Fisher, W. Webster, M.D., Downing Professor of Medicine, Cambridge.

1859 Fisher, Alexander, M.D., Assistant-Surgeon, R.N., Her Majesty's Ship "Endymion."

1855 Flower, William H., F.R.S., Conservator of the Museum, Royal College of Surgeons; 39, Lincoln's-inn-fields, W.C. (C. 1862-4.)

1852 Forbes, J. Gregory, 82, Oxford-terrace, Hyde-park, W. (C. 1860-3).

1850 Foreman, Robert Clifton, M.D., Resident Physician to the Asylum for Imbecile Children of the Upper Classes, Church-hill House, Brighton.

†O.M. Forster, John Cooper (V.-P.), Surgeon to Guy's Hospital, 29, Upper Grosvenor-street. (C. 1857-8. V.-P. 1871.)

‡1866 Foster, Balthazar Walter, M.D., Physician to the General Hospital, Birmingham, 4, Old-square, Birmingham.

1866 Foster, John B., 23, Welbeck-street, W.

1862 Fox, Wilson, M.D., Professor of Clinical Medicine in University College, and Physician to University College Hospital, 67, Grosvenor-street, W. (C. 1868-70.)

1865 Fox, W. Tilbury, M.D., Physician to the Skin Department of University College Hospital, 43, Sackville-street, Piccadilly, W.

1858 Francis, Charles Richard, M.B., Bengal Medical Establishment, Indian Army.

O. M. Frere, J. C.

1864 Frodsham, John Mill, M.D., Streatham.

1846 Fuller, Henry W., M.D., Physician to St. George's Hospital, 13, Manchester-square, W. (C. 1853-4.)

1868 Fyfe, Andrew, M.D., 42, Montpellier-square, Brompton, S.W.

‡1858 Gairdner, William Tennant, M.D., Professor of Medicine in the University of Glasgow, 225, St. Vincent-street, Glasgow.

1870 Galton, Edmund H., Springfield House, Brixton-hill, S.W.

1870 Galton, John H., M.D., Hove Oak Villa, Thicket-road, Upper Norwood. S.E.

1855 Gamgee, Joseph Sampson, Surgeon to the Queen's Hospital, Birmingham, 20, Broad-street, Birmingham.

Digitized by Google

Elected

1855 GAMGEE, J.

1846 GARROD, ALFRED BARING, M.D., F.R.S., Physician to King's College Hospital, 11, Harley-street, Cavendish-square, W. (C. 1851. V.-P. 1863-5.)

1858 GASCOYEN, GEORGE GREEN, Surgeon to the Lock Hospital, and Assistant-Surgeon to, and joint Lecturer on Surgery at, St. Mary's Hospital, 48, Queen Anne-street, Cavendish-square, W.

1856 GASKOIN, GEORGE, 7, Westbourne-park, Paddington, W.

O. M. GAY, JOHN (V.-P.), Senior Surgeon to the Great Northern Hospital, 10, Finsbury-place South, E.C. (C. 1852-4. V.-P. 1870-1.)

1853 GIBBON, SEPTIMUS, M.D., 11, Finsbury-place South, E.C.

‡1858 GODFREY, BENJAMIN, M.D., Carlton-house, Enfield.

1855 GOODFELLOW, STEPHEN JENNINGS, M.D., Physician to the Middlesex Hospital, 5, Savile-row, Burlington-gardens, W. (C. 1863-5.)

1870 GOULD, FRANKLIN, M.D., 26, Charlotte-street, Bedford-square, W.C.

1870 GOWERS, WILLIAM RICHARD, M.D., 32, Mornington-crescent, N.W.

1858 GOWLLAND, PETER Y., Surgeon to St. Mark's Hospital, 34, Finsbury-square, E.C.

1847 GREAM, GEORGE T., M.D., 2, Upper Brook-street, Grosvenor-square, W. (C. 1866-8.)

1867 GREEN, THOMAS H., M.D. (C.), Assistant-Physician to Charing Cross Hospital, 74, Wimpole-street, W. (C. 1871.)

1856 GREENHALGH, ROBERT, M.D., Physician-Accoucheur to St. Bartholomew's Hospital, 77, Grosvenor-street, W.

‡1855 GREENHILL, WILLIAM ALEXANDER, M.D., Carlisle-parade, Hastings.

1863 GREENHOW, EDWARD HEADLAM, M.D., F.R.S., Physician to the Middlesex Hospital, 14A, Manchester-square, W. (C. 1867-9.)

1861 GUENEAU DE MUSSY, HENRI, M.D., 55, Wimpole-street, Cavendish-square, W.

1863 GULL, WILLIAM WITHEY, M.D., F.R.S., 74, Brook-street, Grosvenor-square, W.

1851 HACON, E. DENNIS, 249, Mare-street, Hackney, N.E.

†1852 HALLEY, ALEXANDER, M.D., 16, Harley-street, Cavendish-square, W.

1848 HARE, CHARLES JOHN, M.D., 57, Brook-street, Grosvenor-square, W. (C. 1852-4.)

†1856 HARLEY, GEORGE, M.D., F.R.S., 25, Harley-street, Cavendish-square, W. (C. 1862-5.)

1863 HARLING, ROBERT DAWSON, M.D. Lond., 16, Seymour-street, Portman-square, W.

†1858 HART, ERNEST, 42, Harley-street, W. (C. 1867-8).

†1859 HASTINGS, CECIL WILLIAM, M.B., 13, Queen Anne-street, Cavendish-square, W.

1870 HAWARD, JOHN WARRINGTON, 46, Queen Anne-street, Cavendish-square, W.

Digitized by Google

Elected

O. M. HAWKINS, CÆSAR H., F.R.S., Consulting Surgeon to St. George's Hospital, 26, Grosvenor-street, W. (V.-P. 1846-51. *Pres.* 1852-3.)

1857 HAWKSLEY, THOMAS, M.D., Physician to the Margaret-street Dispensary for Consumption, 6, Brook-street, Hanover-square, W.

1869 HAY, THOMAS BELL, L.R.C.P. Ed., 43, Caledonian-road, N.

1856 HEATH, CHRISTOPHER, Surgeon to University College Hospital, 9, Cavendish-place, Cavendish-square, W. (C. 1866-7.)

1869 HENSLEY, PHILIP H., M.B., 4, Henrietta-street, Cavendish-square, W.

‡1868 HESLOP, THOMAS P., M.D., Physician to the Children's Hospital, Birmingham.

O. M. HEWETT, PRESCOTT G., Surgeon to St. George's Hospital, 1, Chesterfield-street, May-fair, W. (C. 1846-52. V.-P. 1854-7. *Pres.* 1863-4. V.-P. 1865-8.)

1855 HEWITT, GRAILY, M.D., Obstetric Physician to University College Hospital, 36, Berkeley-square, W. (C. 1865-7).

1864 HICKMAN, WILLIAM, M.B., Surgeon to the Samaritan Free Hospital, and to the Western General Dispensary, 1, Dorset-square, N.W.

1868 HILL, JOHN DANIEL, Surgeon to the Royal Free Hospital, and Assistant-Surgeon to the Royal Orthopædic Hospital, 17, Guilford-street, Russell-square, W.C.

1860 HILL, M. BERKELEY, M.B., Assistant-Surgeon to University College Hospital, and Surgeon for Out-Patients to the Lock Hospital, 14, Weymouth-street, Portland-place, W.

1867 HILL, SAMUEL, M.D., 22, Mecklenburg-square, W.C.

O. M. HILLMAN, WILLIAM AUGUSTUS, 1, Argyll-street, Regent-street, W. (C. 1856-8.)

†O.M. HILTON, JOHN, F.R.S. (PRESIDENT), Consulting Surgeon to Guy's Hospital, 10, New Broad-street, E.C. (C. 1848-50. V.-P. 1863-4. *Pres.* 1871.)

1855 HINTON, JAMES, Aural Surgeon to Guy's Hospital, 18, Savile-row, W. (C. 1869-70.)

1852 HOGG, JABEZ, Surgeon to the Westminster Ophthalmic Hospital, 1, Bedford-square, W.C. (C. 1860-2.)

1847 HOLMAN, H. MARTIN, M.D., Hurstpierpoint, Sussex.

1854 HOLMES, TIMOTHY (V.-P.), Surgeon-in-Chief to the Metropolitan Police, Surgeon to St. George's Hospital, 31, Clarges-street, Piccadilly, W. (C. 1862-3. S. 1864-7. C. 1868. V.-P. 1869-71.)

1850 HOLT, BARNARD WIGHT, Senior Surgeon to the Westminster Hospital, 14, Savile-row, W. (C. 1853.)

O. M. HOLTHOUSE, CARSTEN, Surgeon to, and Lecturer on Surgery at, the Westminster Hospital, 3, George-street, Hanover-square, W. (C. 1852-4.)

1864 HOOD, WHARTON P., M.D., 65, Upper Berkeley-street, Portman-square, W.

1865 HOOPER, JOHN HARWARD, M.B., Auckland, New Zealand.

1870 HOPE, WILLIAM, M.B., 5, Bolton-row, May-fair, W.

Digitized by Google

Elected

1850 Hobb, Henry A., Surgeon to the Bristol Royal Infirmary, 31, Park-street, Bristol.

1866 Howard, Edward, M.D., Oaklands, Penge, Surrey.

†1856 Hudson, John, M.D., 11, Cork-street, Bond-street, W.

1854 Hulke, John Whitaker, F.R.S. (Hon. Secretary), Surgeon to the Middlesex Hospital, and Surgeon to the Royal London Ophthalmic Hospital, 10, Old Burlington-street, W. (C. 1863-5. S. 1868-71.)

1854 Hulme, Edward Charles, Ophthalmic Surgeon to the Great Northern Hospital, Woodbridge-road, Guildford.

1853 Humby, Edwin, M.D., 83, Hamilton-terrace, St. John's-wood, N.W.

1866 Hunter, Charles, 30, Wilton-place, Belgrave-square, S.W.

1852 Hutchinson, Jonathan, Surgeon to the London Hospital, and to the Royal London Ophthalmic Hospital, Moorfields, 4, Finsbury-circus, E.C. (C. 1856-9.)

1865 Jackson, J. Hughlings, M.D., Physician to the London Hospital, Physician to the National Hospital for the Paralysed and Epileptic, 3, Manchester-square, W.

1859 Jackson, Thomas Carr, Surgeon to the Great Northern Hospital, 3, Weymouth-street, Portland-place, W.

‡1853 Jardine, John Lee, Capel, near Dorking, Surrey.

1847 Jay, Edward, 112, Park-street, Grosvenor-square, W.

O. M. Jenner, Sir William, Bart., M.D., D.C.L., F.R.S., Physician to University College Hospital, 63, Brook-street, Grosvenor-square, W. (C. 1850-3. V.-P. 1862-4.)

1861 Jephson, John Holmes, M.D., Physician to the Great Northern Hospital, 22, Connaught-square, Hyde Park, W.

1866 Jessop, Thomas Richard, 31, Park-square, Leeds.

1854 Johnson, Athol A. W., 20, Regency-square, Brighton.

1855 Johnson, Edward, M.D., 19, Cavendish-place, Cavendish-square, W.

O. M. Johnson, George, M.D., Physician to King's College Hospital, 11, Savile-row, W. (C. 1846-50. V.-P. 1863-4.)

†O.M. Jones, Henry Bence, M.D., F.R.S., Consulting Physician to St. George's Hospital, 84, Brook-st., Grosvenor-sq., W. (C. 1846-50. V.-P. 1851-7.)

1853 Jones, Sydney, M.B., Assistant-Surgeon to St. Thomas's Hospital, 10*b*, St. Thomas's-street, Southwark, S.E. (C. 1864-6.)

1862 Jones, Thomas, M.D., Assistant-Physician to the Victoria Hospital for Sick Children, 28, Chapel-street, Belgrave-square, S.W.

1858 Jones, William Price, M.D., Claremont-road, Surbiton, Kingston.

1860 Jones, Walter, College-yard, Worcester.

1867 Kelly, Charles, M.D., Curator of the Museum at King's College, and Assistant-Physician to King's College Hospital, 94, Wimpole-street, W.

1846 Kent, Thomas J., 60, St. James's-street, S.W.

1852 Kershaw, W. Wayland, M.D., Kingston-on-Thames.

Digitized by Google

Elected

1859 Kiallmark, Henry Walter, 66, Prince's-square, Bayswater, W.

1867 King, Edwin Holborow, 18, Stratford-place, Oxford-street, W.

1871 King, Robert, M.B., Resident Medical Officer, Middlesex Hospital, 30, Weymouth-street.

1852 Kingdon, J. Abernethy, Surgeon to the City Dispensary, and to the City of London Truss Society, 2, New Bank-buildings, Lothbury, E.C.

‡1856 Kingsley, Henry, M.D.. Physician to the Stratford Infirmary, Stratford-on-Avon, Warwickshire.

‡1865 Lanchester, Henry Thomas, M.D., 53, High-street, Croydon.

1851 Langmore, John C., M.B., 12, Sussex-gdns., Hyde-pk., W. (C. 1858-61.)

1865 Langton, John, Assistant-Surgeon to St. Bartholomew's Hospital, 18, Harley-street, Cavendish-square, W.

1869 Larcher, O., M.D. Par., 97, Rue de Passy, Paris.

1849 Latham, Peter Mere, M.D. (formerly President), late Physician to St. Bartholomew's Hospital, Torquay. (*Pres.* 1850-1. V.-P. 1852-3.)

1867 Lawrence, Henry Cripps, Registrar, Queen Charlotte's Lying-in Hospital, Marylebone-road, 158, Queen's-road, Bayswater, W.

1853 Lawrence, Henry John Hughes, Assistant-Surgeon, Grenadier Guards; Hospital, Rochester-row, Westminster, S.W.

1859 Lawson, George (C.), Assistant-Surgeon to the Middlesex Hospital, and Surgeon to the Royal London Ophthalmic Hospital, Moorfields, 12, Harley-street, Cavendish-square, W. (C. 1870-1.)

1865 Leach, Harry, Resident Medical Officer, "Dreadnought" Hospital for Seamen, Greenwich.

1857 Leared, Arthur, M.D., Physician to the Great Northern Hospital, 12, Old Burlington-street, W.

1852 Lee, Henry, Surgeon to St. George's Hospital, 9, Savile-row, W. (C. 1860-2.)

1867 Lees, Joseph, M.D., Demonstrator of Anatomy at St. Thomas's Hospital, 112, Walworth-road, S.E.

1868 Legg, John Wickham, M.D., Physician to the Casualty Department, St. Bartholomew's Hospital, 8, Old Cavendish-street, W.

1852 Leggatt, Alfred, 13, William-street, Lowndes-square, S.W. (C. 1866-7).

1865 Leighton, Edmund Thomas, M.B., 42, Bedford-row, Holborn, W.C.

‡1867 Leudet, T., M.D. Par., Professor of Clinical Medicine, Rouen, France. [M. Kliensieck, Libraire, Rue de Lille, 11, Rouen, per Messrs. Longman.]

1861 Lichtenberg, George, M.D., 47, Finsbury-square, E.C.

1848 Little, William John, M.D., 71, Brook-street, Grosvenor-square, W. (C. 1851-2. V.-P. 1856-9.)

†1862 Little, Louis S., China.

1863 Liveing, Robert, M.D., Assistant-Physician to the Middlesex Hospital, 14, Manchester-square, W.

‡1860 Lund, George, M.D.

Digitized by Google

Elected

1871 MacCormac, William, Assistant-Surgeon to St. Thomas's Hospital, 13, Harley-street, W.

1858 Mackay, Allan Douglas, M.B., Stony-Stratford, Bucks.

1870 Mackenzie, George Welland, 15, Hans-place, Sloane-street, S.W.

1870 Mackenzie, John, M.D., Staff Assistant-Surgeon, Army.

1870 Mackenzie, John T., Bombay, India [East India United Service Club, 14, St. James's-square.]

1864 Mackenzie, Morell, M.D., Assistant-Physician to the London Hospital 13, Weymouth-street, Portland-place, W.

1865 MacLaurin, H. N., M.D.

1857 Marcet, William, M.D., F.R.S. (C.), 1, Place Massena, Nice. (C. 1869-71.)

1868 Marsh, F. Howard, Assistant-Surgeon to the Hospital for Sick Children, Demonstrator of Anatomy at St. Bartholomew's Hospital, 38, Guilford-street, Russell-square, W.C.

1846 Marshall, John, F.R.S., Surgeon to University College Hospital, 10, Savile-row, W. (C. 1861.)

‡1861 Martin, John, Cambridge House, Portsmouth.

1869 Martin, John Henry C. Erridge, M.D., Cambridge House, Portsmouth.

1856 Martin, Robert, M.D. (C.), 51, Queen Anne-street, Cavendish-square, W. (C. 1871.)

1852 Martyn, Samuel, M.D., Physician to the Bristol General Hospital, 8, Buckingham-villas, Clifton, Bristol.

1860 Mason, Francis, Assistant-Surgeon to St. Thomas's Hospital, 10, Conduit-street, Regent-street, W.

1867 Mason, Philip Brookes, Burton-on-Trent.

†1858 Maunder, Charles F. (C.), Surgeon to the London Hospital, 29, New Broad-street, E.C. (C. 1869-71.)

‡1852 May, George, Jun., M.B., Surgeon, Royal Berkshire Hospital, Reading.

1859 Messer, John Cockburn, M.D., Assistant-Surgeon, R.N., Her Majesty's Ship "Edinburgh," Queensferry, N.B.

‡1867 Mickley, Arthur George, M.B.., House Surgeon, General Hospital, Nottingham.

1866 Mickley, George, M.A., M.B., Three Counties Asylum, near Arlesey, Bedfordshire.

†1859 Montefiore, Nathaniel, 36, Hyde-park-gardens, W.

1861 Morehead, Charles, M.D., 59, Melville-street, Edinburgh.

1847 Morgan, John, 3, Sussex-place, Hyde-park-gardens, W. (C. 1856-8.)

1869 Morris, Henry, M.A., M.B., Assistant-Surgeon to the Middlesex Hospital, 19, Bedford-Square, W.C.

1860 Moxon, Walter, M.D., Assistant-Physician to Guy's Hospital, 6, Finsbury-circus, E.C. (C. 1868-70.)

1854 Murchison, Charles, M.D., LL.D. Edinb., F.R.S. (Treasurer), Physician to, and Lecturer on Medicine at, St. Thomas's Hospital, and Consulting Physician to the London Fever Hospital, 79, Wimpole-street, W. (C. 1859-62. S. 1865-8. T. 1869-71.)

Digitized by Google

Elected

1867 MURRAY, JOHN, M.D., Assistant-Physician to the Middlesex Hospital; Assistant-Physician to the Hospital for Sick Children, 40, Bryanston-street, Portman-square, W.

1864 MYERS, ARTHUR B. R., Coldstream Guards' Hospital, Vincent-square, Westminster, S.W.

1865 NEWMAN, WILLIAM, M.D., Stamford, Lincolnshire.

1868 NICHOLLS, JAMES, M.D., Chelmsford, Essex.

1865 NICOLL, CHARLES R., M.D., Resident Medical Officer to the Charter House, 17, Charter-house-square, E.C.

1864 NORTON, ARTHUR T., Assistant-Surgeon to St. Mary's Hospital, 6, Wimpole-street, Cavendish-square, W.

1856 NUNN, THOMAS WILLIAM, Surgeon to the Middlesex Hospital, 8, Stratford-place, Oxford-street, W. (C. 1864-6.)

1871 NUNNELEY, FREDERICK BARHAM, M.D., Assistant-Physician to the City of London Hospital for Diseases of the Chest, Assistant-Physician to the Hospital for Sick Children, 28, Harley-street, Cavendish-square.

1850 OGLE, JOHN W., M.D., Physician to St. George's Hospital, 30, Cavendish-square, W. (C. 1855-6. S. 1857-60. C. 1861-3. V.-P. 1865-8.)

‡1856 OLDFIELD, EDMUND, Boscomb Lodge, 45, Finchley-road.

1860 ORANGE, WILLIAM, M.D., Broadmoor, Berkshire.

1865 OWLES, JAMES ALLDEN, M.D., 204, Burlington-street, Liverpool.

1870 PAGET, SIR JAMES, Bart., F.R.S., D.C.L., Consulting Surgeon to St. Bartholomew's Hospital, 1, Harewood-place, Hanover-square, W.

1853 PARKINSON, GEORGE, 50, Brook-street, Grosvenor-square, W.

1854 PART, JAMES, M.D., 89, Camden-road, Camden-town, N.W.

O. M. PARTRIDGE, RICHARD, F.R.S., Consulting Surgeon to King's College Hospital, 17, New-street, Spring-gardens, S.W. (C. 1846-7. V.-P. 1848-52.)

1865 PAVY, FREDERICK WILLIAM, M.D., F.R.S., Physician to Guy's Hospital, 35, Grosvenor-street, W.

1868 PAYNE, JOSEPH FRANK, B.A., M.B., Assistant-Physician to St. Thomas's Hospital, 50, Green-street, Park-lane, W.

O. M. PEACOCK, THOMAS BEVILL, M.D., Physician to St. Thomas's Hospital, and Physician to the City of London Hospital for Diseases of the Chest 20, Finsbury-circus, E.C. (C. 1846-9. S. 1850-1. V.-P. 1852-6. C. 1858-61. *Pres.* 1865-6. V.-P., 1867-70.)

1870 PEARSE, GEORGE E. LEGGE, Assistant-Surgeon to the Westminster Hospital, 52, Maddox-street, W.

1863 PEARSON, DAVID R., M.D., 23, Upper Phillimore-place, Kensington, W.

1871 PHILLIPS, CHARLES DOUGLAS F., M.D., 107, Lancaster-gate, W.

1866 PHILLIPS, JOHN JONES, M.D., Assistant-Obstetric-Physician to Guy's Hospital, and Assistant-Physician to the Hospital for Sick Children, 26, Finsbury-square, E.C.

Digitized by Google

Elected

1863 PICK, THOMAS PICKERING (C.), Assistant-Surgeon to, and Joint Lecturer on Surgery at, St. George's Hospital, 7, South Eaton-place, S.W. (C. 1870-71.)

1867 PITT, EDWARD G., Cowley-villas, Leytonstone.

1863 PLAYFAIR, W. S., M.D., Assistant-Physician for the Diseases of Women and Children, King's College Hospital, 5, Curzon-street, Mayfair, W.

O. M. POLAND, ALFRED, Surgeon to Guy's Hospital, 48, Finsbury-circus, E.C. (C. 1850-2.)

1862 POLLOCK, ARTHUR JULIUS, M.D., Physician to Charing Cross Hospital, 85, Harley-street, Cavendish-square, W.

1867 POLLOCK, EDWARD J.

1846 POLLOCK, GEORGE D., Surgeon to St. George's Hospital, 36, Grosvenor-street, W. (S. 1850-3. C. 1854-6. V.-P. 1863-5.)

1850 POLLOCK, JAMES EDWARD, M.D., Physician to the Hospital for Consumption and Diseases of the Chest, Brompton, 52, Upper Brook-street, W. (C. 1862-4.)

1870 POORE, GEORGE VIVIAN, M.B., 30, Wimpole-street, W.

1854 POTTS, WILLIAM (C.), 12, North Audley-street, Grosvenor-square, W. (C. 1870-1.)

1866 POWELL, RICHARD DOUGLAS, M.D., Assistant-Physician to the Hospital for Consumption, Brompton, Assistant-Physician to Charing Cross Hospital, 15, Henrietta-street, Cavendish-square, W.

1865 POWER, HENRY, M.B., Ophthalmic Surgeon to St. Bartholomew's Hospital, 45, Seymour-street, Portman-square, W.

1856 PRIESTLEY, WILLIAM OVEREND, M.D., Physician for the Diseases of Women and Children to King's College Hospital, Consulting Physician-Accoucheur to the St. Marylebone Infirmary, 17, Hertford-street, May-fair, W.

†1848 PURNELL, JOHN JAMES, Surgeon to the Royal General Dispensary, Woodlands, Streatham-hill, S.W. (C. 1858-61.)

O. M. QUAIN, RICHARD, M.D., F.R.S. (V.-P.), Physician to the Hospital for Consumption and Diseases of the Chest, Brompton, 67, Harley-street, Cavendish-square, W. (C. 1846-51. S. 1852-6. T. 1857-68. *Pres.* 1869-70. V.-P. 1871.)

1859 RADCLIFFE, CHARLES BLAND, M.D., Physician to the Westminster Hospital, 25, Cavendish-square, W.

1857 RAMSKILL, J. SPENCE, M.D., Physician to the London Hospital, Physician to the National Hospital for the Paralysed and Epileptic, 5, St. Helen's-place, Bishopsgate-street, E.C.

1848 RANDALL, JOHN, M.D., Medical Officer, St. Marylebone Infirmary, 35, Nottingham-place, W. (C. 1864-6.)

1857 RANKE, HENRY, M.D., Munich.

1865 RASCH, ADOLPHUS A., M.D., Physician to the German Hospital Eastern Dispensary, 7, South-street, Finsbury-square, E.C.

Digitized by Google

Elected

1870 RAY, EDWARD REYNOLDS, Dulwich.

1871 RAYNER, HENRY, M.D., Bethlehem Royal Hospital, Lambeth-road, S.E.

1858 REED, FREDERICK GEORGE, M.D., 46, Hertford-street, May-fair, W.

1866 REEVES, HENRY ALBERT, Assistant-Surgeon to the London Hospital, 36, Gordon-square, W.C.

1866 RENDLE, JAMES DAVY, M.D., Medical Officer to the Government Convict Prison, Brixton; Park-hill, Clapham-park, S.W.

1854 REYNOLDS, J. RUSSELL, M.D., F.R.S., Physician to University College Hospital, 38, Grosvenor-street, W. (C. 1868-9.)

O. M. RIDGE, JOSEPH, M.D., 39, Dorset-square, N.W. (C. 1853-4.)

1866 RIVINGTON, WALTER, M.S. Lond., Surgeon to the London Hospital, 22, Finsbury-square, E.C.

1863 ROBERTS, ARTHUR, 30, Kensington-square, W.

‡1865 ROBERTS, DAVID LLOYD, M.D., Surgeon to St. Mary's Hospital, Manchester, 23, St. John's-street, Manchester.

1856 ROBERTS, JOHN HENRY, 20, New Finchley-road, St. John's-wood, N.W.

1863 ROBINSON, CHARLES, F.R.C.P. Edinb., 11, Montagu-street, Portman-square, W.

1859 ROBINSON, FREDERICK, M.D. (C.), Surgeon Major, 1st Battalion, Scots Fusilier Guards, 47, Lupus-street, St. George's-square, S.W. (C. 1871.)

1856 ROBINSON, THOMAS, M.D., 35, Lamb's Conduit-street, W.C.

1865 ROGERS, GEORGE HENRY, 14, Old Burlington-street, W.

1858 ROLLESTON, GEORGE, M.D., F.R.S., Park Grange, Oxford.

1858 ROSE, HENRY COOPER, M.D., Surgeon to the Hampstead Dispensary, High-street, Hampstead.

1858 ROUSE, JAMES, Assistant-Surgeon to St. George's Hospital, 2, Wilton-street, Grosvenor-place, S.W.

1869 RUTHERFORD, WILLIAM, M.D., Professor of Physiology, in King's College, London; 12, Upper Berkeley-street, Portman-square, W.

1853 SALTER, JAMES A., M.B., F.R.S, Dental Surgeon to Guy's Hospital, 17, New Broad-street, City, E.C. (C. 1861-3.)

1852 SANDERSON, HUGH JAMES, M.D., Physician to the Hospital for Women, 26, Upper Berkeley-street, Portman-square, W.

1854 SANDERSON, JOHN BURDON, M.D., F.R.S., Professor of Practical Physiology at University College, 49, Queen Anne-street, Cavendish-square, W. (C. 1864-7.)

‡1847 SANKEY, W. H. OCTAVIUS, M.D., Sandywell-park, near Cheltenham. (C. 1855.)

1858 SCHULHOF, MAURICE, M.D., 46, Brook-street, W.

1854 SCOTT, JOHN, Surgeon to the Hospital for Women, Soho-square, 49, Harley-street, Cavendish-square, W.

‡1847 SEATON, EDWARD C., M.D., Rochester-house, Surbiton. (C. 1859-61.)

Digitized by Google

Elected

1857 SEDGWICK, WILLIAM, Surgeon to the Marylebone Provident Dispensary, 12, Park-place, Upper Baker-street, N.W.

1852 SEMPLE, ROBERT HUNTER, M.D., Physician to the Bloomsbury Dispensary, 8, Torrington-square, W.C. (C. 1859-61.)

O. M. SHAW, ALEXANDER, Consulting Surgeon to the Middlesex Hospital, 40, Abbey-road West, Kilburn, N.W. (C. 1848-51. V.-P. 1852. T. 1853-6. C. 1858. V.-P 1859-62.)

1856 SHILLITOE, BUXTON, Surgeon to the Great Northern Hospital, and to the Lock Hospital, 34, Finsbury-circus, E.C.

1855 SIBLEY, SEPTIMUS W., 12, New Burlington-street, W. (C. 1863-5.)

1849 SIBSON, FRANCIS, M.D., F.R.S. (late V.-P.), Consulting Physician to St. Mary's Hospital, 59, Brook-street, Grosvenor-square, W. (C. 1856-7. V.-P. 1866-9.)

1847 SIEVEKING, EDWARD H., M.D. (late V.-P.), Physician to St. Mary's Hospital, 17, Manchester-square, W. (C. 1854-7. V.-P. 1864-5.)

O. M. SIMON, JOHN, F.R.S., D.C.L. (V.-P.), Surgeon to St. Thomas's Hospital, 8, Richmond-terrace, Whitehall, and 40, Kensington-square, W. (C. 1846-8. V.-P. 1855-9. *Pres.* 1867-8. V.-P. 1869-71.)

1866 SIMS, FRANCIS MANLEY BOLDERO, Assistant-Surgeon to the Hospital for Diseases of the Skin, and Surgeon to the St. George's Dispensary, 25, Half-moon-street, Piccadilly, W.

1865 SIMS, J. MARION, M.D., 267, Madison-avenue, New York.

O. M. SMITH, EBENEZER PYE, Mare-street, Hackney, N.E. (C. 1848-9.)

1863 SMITH, HENRY, Surgeon to King's College Hospital, 82, Wimpole-street, Cavendish-square, W.

1866 SMITH, HEYWOOD, M.B., Assistant-Physician to the Hospital for Women, 2, Portugal-street, Grosvenor-square, W.

1865 SMITH, PHILIP HENRY PYE, M.D., Assistant-Physician to Guy's Hospital, 31, Finsbury-square, E.C.

1846 SMITH, PROTHEROE, M.D., Physician to the Hospital for Women, 42, Park-street, Grosvenor-square, W.

1869 SMITH, ROBERT SHINGLETON, M.D., Royal Infirmary, Bristol.

1856 SMITH, SPENCER, Surgeon to St. Mary's Hospital, 9, Queen Anne-street, Cavendish-square, W.

1856 SMITH, THOMAS, Assistant-Surgeon to St. Bartholomew's Hospital, 5, Stratford-place, Oxford-street, W. (C. 1867-9.)

1866 SMITH, WILLIAM, Melbourne, Australia.

1870 SMITH, WILLIAM JOHNSON, Assistant-Surgeon, Seamen's Hospital Society, Dreadnought, Greenwich.

1869 SMITH, WILLIAM WILBERFORCE, 20, Bishop's-road, Paddington, W.

1870 SNOW, WILLIAM VICARY, M.D., Richmond-gardens, Bournemouth.

1868 SOUTHEY, REGINALD, M.D., Physician to St. Bartholomew's Hospital, 6, Harley-street, Cavendish-square, W.

1866 SPOONER, CHARLES, Professor and Principal in the Royal Veterinary College, Great College-street, Camden Town, N.W.

1868 SPRY, GEORGE FREDERICK, M.D., Assistant-Surgeon, 2nd Life Guards, Cavalry Barracks, Windsor.

Digitized by Google

Elected

1866 Squarey, Charles Edward, M.B., Assistant-Physician to the Hospital for Women, 13, Upper Wimpole-street, W.

1855 Squire, William (C.), 6, Orchard-street, Portman-square, W. (C. 1870-1.)

1861 Squire, Alexander Balmanno, 9, Weymouth-street, Portland-place, W.

1854 Stewart, William Edward, Surgeon to St. Marylebone Provident Dispensary, 12, Weymouth-street, Portland-place, W.

1863 Stone, William Domett, M.D., 31, Myddelton-square, E.C.

†1853 Streatfeild, J. F., Surgeon to the Royal London Ophthalmic Hospital, Moorfields, 15, Upper Brook-street, W.

1863 Sturges, Octavius, M.D., Assistant-Physician to the Westminster Hospital, 85, Wimpole-street, W.

1864 Sutton, Henry G., M.B., Assistant-Physician to the London Hospital, 9, Finsbury-square, E.C.

‡1867 Swain, William Paul, 20, Ker-street, Devonport.

‡1857 Symonds, Frederick, Surgeon to the Radcliffe Infirmary, 35, Beaumont-street, Oxford.

1870 Tait, Robert Lawson, 7, Waterloo-street, Birmingham.

O. M. Tamplin, R. W., Surgeon to the Royal Orthopædic Hospital, 33, Old Burlington-street, W.

‡1856 Tapp, W. Denning, Hillside-house, Hatherley-road, Cheltenham.

1864 Tatham, John, M.D., 1, Wilton-place, Knightsbridge, S.W.

1870 Tay, Waren, Assistant-Surgeon to, and Demonstrator of Practical Anatomy at, the London Hospital, 10, Finsbury-pavement.

1861 Teevan, William Frederic, Surgeon to the West London Hospital, 10, Portman-square, W.

1870 Thomas, John Davies, M.B., University College Hospital.

1852 Thompson, Sir Henry, Knt., Surgeon to University College Hospital, 35, Wimpole-street, Cavendish-square, W. (S. 1859-63. C. 1865-7. V.-P. 1868-70.)

‡1861 Thompson, Joseph, Surgeon to the Nottingham General Hospital, Oxford-street, Nottingham.

1867 Thompson, Reginald Edward, M.D., Assistant-Physician to the Hospital for Consumption, Brompton, 21, South-street, Park-lane, W.

1865 Thorowgood, J. C., M.D., 61, Welbeck-street, W.

1867 Thudichum, John L. W., M.D., 3, Pembroke-road, Kensington, W.

1856 Tomes, J., F.R.S., Surgeon-Dentist to the Middlesex Hospital, 37, Cavendish-square, W. (C. 1867-9.)

1864 Tonge, Morris, M.D., Harrow-on-the-Hill, Middlesex.

1867 Trimen, Henry, M.B., 71, Guilford-street, Russell-square, W.C.

1851 Trotter, John W., Assistant-Surgeon, Coldstream Guards' Hospital, Vincent-square, Westminster, S.W., and the Tower. (C. 1865-9.)

1859 Truman, Edwin Thomas, Surgeon-Dentist in Ordinary to Her Majesty's Household, 23, Old Burlington-street, W.

Digitized by Google

Elected

1867 TUCKWELL, HENRY MATTHEWS, M.D., Physician to the Radcliffe Infirmary, Holywell, Oxford.

1858 TUDOR, JOHN, Dorsetshire, Dorset.

1853 TULLOCH, JAMES S., M.D., 1, Pembridge-place, Bayswater, W.

1863 TURNER, JAMES SMITH, 30, Margaret-street, Cavendish-square, W.

1858 TURTLE, FREDERICK, Clifton-lodge, Woodford, Essex.

1854 VASEY, CHARLES, Surgeon-Dentist to St. George's Hospital, 5, Cavendish-place, Cavendish-square, W.

1867 VENNING, EDGCOMBE, Assistant-Surgeon, 1st Life Guards, Knightsbridge Barracks, and 24, Belgrave-square, S.W.

1865 VERNON, BOWATER JOHN, Ophthalmic Surgeon to St. Bartholomew's Hospital, 44A, Wimpole-street, Cavendish-square, W.

1868 VINCENT, OSMAN, 23, Devonshire-street, Portland-place, W.

†1867 WAGSTAFFE, WILLIAM WARWICK, B.A., Resident Assistant-Surgeon to St. Thomas's Hospital.

O. M. WAITE, CHARLES D., M.D., Senior Physician to the Westminster General Dispensary, 3, Old Burlington-street, W.

1865 WALKER, JOSEPH, 22, Grosvenor-street, Grosvenor-square, W.

1859 WALTERS, JOHN, M.D., Assistant-Surgeon attached to Second Battalion, 17th Regiment.

1847 WARD, T. OGIER, M.D., 11, Place de la Mare, Caen. (C. 1851-3.)

1858 WARDELL, JOHN RICHARD, M.D., 4, Belmont, Tunbridge Wells.

1855 WATSON, SIR THOMAS, Bart., M.D., F.R.S., 16, Henrietta-street, Cavendish-square, W. (*Pres.* 1857-8. V.-P. 1859-63.)

1865 WATSON, W. SPENCER, Surgeon to the Great Northern Hospital; Surgeon to the Royal South London Ophthalmic and to the Central London Ophthalmic Hospitals, 7, Henrietta-street, Cavendish-square, W.

1860 WAY, JOHN, M.D., 4, Eaton-square, S.W.

1867 WEBB, FRANCIS C., M.D., Physician to the Great Northern Hospital, 22, Woburn-place, Russell-square, W.C.

†1858 WEBER, HERMANN, M.D., Physician to the German Hospital, 10, Grosvenor-street, Grosvenor-square, W. (C. 1867-70.)

1864 WELCH, THOMAS DAVIES, M.D., Physician to the Kent and Canterbury Hospital, Canterbury, Kent.

1861 WELLS, JOHN SOELBERG, Ophthalmic Surgeon to King's College Hospital, and Assistant-Surgeon to the Royal London Ophthalmic Hospital, 16, Savile-row, W.

1853 WELLS, THOMAS SPENCER, Surgeon to the Samaritan Free Hospital for Women and Children, 3, Upper Grosvenor-street, W. (C. 1865-8.)

1851 WEST, CHARLES, M.D., Physician to the Hospital for Sick Children, 61, Wimpole-street, Cavendish-square, W. (C. 1856-7.)

1867 WHIPHAM, THOMAS TILLYER, M.B., 37, Green-street, Grosvenor-square, W.

Digitized by Google

Elected

1869 WHIPPLE, JOHN H. C., M.D., Coldstream Guards' Hospital, Vincent-square, Westminster, S.W.

1859 WHITE, FREDERICK, 20, Oxford-terrace, Hyde-park, W.

†1868 WHITEHEAD, WALTER, 248, Oxford-road, Manchester.

1870 WICKSTEED, FRANCIS WILLIAM, Walthamstow, Essex.

1867 WILCOX, RICHARD WILSON, Temple-square, Aylesbury, Bucks.

1869 WILKIN, JOHN F., Roxby House, Folkestone, Kent.

1864 WILKS, ALFRED G. P., M.A., M.B., Wyndham House, Ryde, Isle of Wight.

1855 WILKS, SAMUEL, M.D., F.R.S. (V.-P.), Physician to Guy's Hospital, 77, Grosvenor-street, W. (C. 1857-60. V.-P. 1869-71.)

1869 WILLIAMS, ALBERT, M.B., 4, York-terrace, Dartmouth-road, Sydenham, S.E.

O. M. WILLIAMS, C. J. B., M.D., F.R.S., Consulting-Physician to the Hospital for Consumption and Diseases of the Chest, Brompton, 49, Upper Brook-street, Grosvenor-square, W. (*Pres.* 1846-7. V.-P. 1848-52. C. 1853-5. V.-P. 1858-61).

‡1858 WILLIAMS, CHARLES, Assistant-Surgeon to the Norfolk and Norwich Hospital, 9, Prince of Wales-road, Norwich.

1866 WILLIAMS, CHARLES THEODORE, M.B., Physician to the Hospital for Consumption and Diseases of the Chest, Brompton, 78, Park-street, Grosvenor-square, W.

1864 WILLIAMS, W. RHYS, M.D., Bethlehem Royal Hospital, Lambeth-road, S.E.

1863 WILLIS, FRANCIS, M.B., Braceborough, Stamford.

1867 WILLOUGHBY, EDWARD FRANCIS, M.B., 2, Marquess-road, Canonbury, N.

1859 WILSON, EDWARD THOMAS, M.B., Montpellier-terrace, Cheltenham.

1859 WILSON, ROBERT JAMES, F.R.C.P. Ed., 7, Warrior-square, St. Leonard's-on-Sea.

1863 WILTSHIRE, ALFRED, M.D., 57, Wimpole-street, Cavendish-square, W.

‡1861 WINDSOR, THOMAS, Surgeon to the Salford Royal Hospital, 65, Piccadilly, Manchester.

1865 WITHERBY, WILLIAM H., M.D., Coombe, Croydon.

1850 WOOD, JOHN, F.R.S., Surgeon to King's College Hospital, 68, Wimpole street, W. (C. 1857-9.)

1854 WOOD, WILLIAM, M.D., Physician to St. Luke's Hospital, 99, Harley-street, W.

1865 WORKMAN, CHARLES JOHN, M.D., Teignmouth.

1863 WORLEY, WILLIAM CHARLES, 1, New North-road, Hoxton, N.

1859 WOTTON, WILLIAM GORDON, King's Langley, Herts.

1852 WRIGHT, EDWARD JOHN, 169, Clapham-road, S.W.

1867 WYATT, JOHN, Surgeon-Major, Coldstream Guards' Hospital, Vincent-square, Westminster, S.W.

1869 WYMAN, W. S., M.D., Westlands, Upper Richmond-road, Putney, S.W.

1869 YEO, J. BURNEY, M.D., 60, St. James's-street, Piccadilly, S.W.

Digitized by Google

LIST OF SPECIMENS AND REPORTS

BROUGHT BEFORE THE SOCIETY DURING THE SESSION 1870-71.

PAGE

REPORT OF THE COMMITTEE ON LARDACEOUS DISEASE
By WILLIAM MARCET, SAMUEL WILKS, J. S. BRISTOWE
J. ANDREW, and W. HOWSHIP DICKINSON 1

I.—DISEASES, ETC., OF THE NERVOUS SYSTEM.

1. Embolism of the left middle cerebral artery of more than six weeks' standing; yellow induration of the corpus striatum, with surrounding white softening
By C. HILTON FAGGE, M.D. 13
2. Spinal cord from a case of motor ataxy
By E. HEADLAM GREENHOW, M.D. 14
3. Spindle-celled sarcoma connected with the posterior tibial nerve . . . . . By MARCUS BECK 18
4. Atrophy of the cerebellum By EDWARD CLAPTON, M.D. 20
5. Venous vascular tumour of cerebrum . By H. MORRIS 22
6. Case of paralysis agitans . By C. MURCHISON, M.D. 24
7. On the changes of the spinal cord in tetanus
By T. CLIFFORD-ALLBUTT, M.D. 27
Report
By J. LOCKHART CLARKE and W. HOWSHIP DICKINSON 31

Digitized by Google

II.—DISEASES, ETC., OF THE ORGANS OF RESPIRATION.

PAGE

1. Constriction of the trachea; syphilitic deposits in the liver and kidney By Morell Mackenzie, M.D. 33
2. Case of diphtheria, with extension of the membrane to the bronchial tubes . By C. Murchison, M.D. 35
3. Aneurism of a branch of the pulmonary artery in a phthisical lung . . . By T. Henry Green, M.D. 37
4. Peculiar pneumonia in a syphilitic subject By Walter Moxon, M.D. 38
5. Some cases illustrating the pathology of fatal hæmoptysis in advanced phthisis By R. Douglas Powell, M.D. 41
6. Case to show identity of gray and yellow tubercles By Walter Moxon, M.D. 66
7. Lymphadenoma of the mediastinum and kidneys By C. Murchison, M.D. 68
8. Intra-thoracic growth; enlarged thymus, &c.; Hodgkin's disease or lymph adenoma By James Risdon Bennett, M.D. 70
9. Secondary scirrhous, or fibro-cancerous, infiltration of connective tissue of lung, &c.; primary cancer of mamma removed By J. Risdon Bennett, M.D. 76

   Report By J. S. Bristowe and Thos. B. Pick for *Committee on Morbid Growths* 82

10. Peculiar sputum . . By Walter Whitehead 82

    Report By R. Douglas Powell and Henry Arnott 84

III.—DISEASES, ETC., OF THE ORGANS OF CIRCULATION.

1. Cases of malformation of the heart By T. B. Peacock, M.D. 85
2. Malformation of the heart; transposition of the great vessels; cyanosis . . . By C. Kelly, M.D. 92

Digitized by Google

PAGE

3. Malformed heart; defective septum ventriculorum
By C. Kelly, M.D. 95

4. Sacculated aneurism of the arch of the aorta, simulating aneurism of the innominate artery
By Christopher Heath 95

5. Aneurism of the thoracic aorta; cured popliteal aneurism
By John Croft 100

6. Aneurism of the arch of the aorta bursting into the œsophagus . . By C. Theodore Williams, M.D. 102

7. Aneurism of abdominal aorta which had burst behind the peritoneum and subsequently into the peritoneal cavity
By H. Morris, for Mr. Shout, of Petworth 104

8. Aneurism of the coronary artery
By Edwards Crisp, M.D. 106

9. Double subclavio-axillary aneurism; ligature of the subclavian on the right side; death from double bronchitis and pulmonary congestion . . . By John Gay 111

10. Dissecting aneurism of the first portion of the arch of the aorta . . . . . By T. Whipham, M.B. 113

11. Rupture of aorta; tumour of brain
By John Hawkes, M.D. 115

Report
By W. Howship Dickinson and R. Douglas Powell 116

12. A case of pleurisy with hæmothorax, complicated by ulceration of the tricuspid valve, and consequent destruction of many of the chordæ tendineæ
By T. Whipham, M.B. 117

13. Case of sudden death from embolism of the carotid and vertebral arteries; chorea and old mitral disease
By C. Murchison, M.D. 119

14. Fibrous tumour of the heart . By W. W. Wagstaffe 121

15. Cancerous growths on endocardium, in liver, lymphatic glands, and body of vertebræ; organized thrombus, perhaps cancerous, in iliac vein By J. F. Payne, M.B. 125

Digitized by Google

IV.—DISEASES, ETC., OF THE ORGANS OF DIGESTION.

(A) TONGUE AND DIGESTIVE CANAL.

PAGE

1. Cancer of the tongue and simple stricture of the œsophagus By EDWARDS CRISP, M.D. 128
2. Cancer of the œsophagus, with a fistulous opening into the trachea By EDWARD HEADLAM GREENHOW, M.D. 129
3. Cancer involving pharynx, larynx, neighbouring lymphatic glands, and lungs . . By J. S. BRISTOWE, M.D. 132
4. Cancer of œsophagus; employment of stomach-pump; free communication between œsophagus and trachea; death by perforation of common carotid; paralysis of left vocal cord . . . By J. S. BRISTOWE, M.D. 134
5. Cancer of stomach, liver, lungs, lymphatics of the thorax, with involvement of the left recurrent laryngeal, and paralysis of the left side of the larynx By J. S. BRISTOWE, M.D. 137
6. Case of gout in the stomach (?) and phlegmonous colitis By W. MOXON, M.D. 139
7. Fatal hæmorrhage from simple ulcer of the stomach By E. CRISP, M.D. 141
8. Recent specimens of acute dysentery from Sedan By JOHN MURRAY, M.D. 142
9. Case of enteric fever with constipated bowels, proving fatal by intestinal hæmorrhage on the twenty-seventh day . . . . By C. MURCHISON, M.D. 144
10. Concretions in the appendix vermiformis, causing ulceration, perforation, and fatal peritonitis By C. MURCHISON, M.D. 146
11. Polypus of rectum . . . . By J. W. HULKE 146
12. Direct inguinal hernia in the female . By W. SQUIRE 148
13. Strangulated femoral hernia; reduction en masse By HENRY MORRIS, M.B. 148

Digitized by Google

(B) DISEASES, ETC., OF THE LIVER.

PAGE

14. Biliary fistula in the abdominal parietes discharging bile By C. MURCHISON, M.D. 152
15. Sequel of a case in which gall-stones were discharged by a fistulous opening through the abdominal parietes By C. MURCHISON, M.D. 154
16. Case in which a biliary calculus was passed from the umbilicus . . . By DYCE DUCKWORTH, M.D. 157
17. Fistulous communication between the gall-bladder and colon By C. MURCHISON, M.D. 158
18. Jaundice from gall-stones, followed by acute atrophy of the liver, with puriform deposits By C. MURCHISON, M.D. 159
19. Malformation of the gall-bladder and hepatic duct By H. H. CRUCKNELL, M.B. 163
20. Columnar epithelioma of the liver By T. WHIPHAM, M.B. 164

Report By WM. CAYLEY and HENRY ARNOTT for *Committee on Morbid Growths* 169

V.—DISEASES, ETC., OF THE GENITO-URINARY ORGANS.

(A) KIDNEYS, BLADDER, ETC.

1. Cyst connected with the left kidney, associated with medullary cancer of the liver, lungs, and left kidney By HENRY MORRIS, M.B., for Mr. MORRIS, of Petworth 171
2. Encephaloid disease of the kidneys By JOHN W. TROTTER 173
3. Unnatural extension of kidney By HEYWOOD SMITH, M.B. 174
4. Atrophied kidneys, causing fatal uræmia, in a youth aged eighteen . . . . By C. MURCHISON, M.D. 177

Digitized by Google

(B) MALE GENITAL ORGANS.

PAGE

5. Cancer of an imperfectly descended testicle, with greatly thickened peritoneum . . By HENRY ARNOTT 182
6. Scrotal tumour; hæmorrhage into subcutaneous cellular tissue, with great subsequent inflammatory thickening of the surrounding parts . . By HENRY ARNOTT 184

(C) FEMALE GENITAL ORGANS.

7. Procidentia uteri with ovarian cyst By CHRISTOPHER HEATH 186

VI.—DISEASES, ETC., OF THE OSSEOUS SYSTEM.

1. Ulceration of the transverse ligament, in consequence of caries of the vertebræ; dislocation of the head forwards; extravasation of blood beneath the arachnoid of the brain and spinal cord . By T. WHIPHAM, M.B. 188
2. Caries of the vertebra, with dislocation of the axis By R. DOUGLAS POWELL, M.D., for Dr. QUAIN 192
3. Fibroma springing from inferior costa of scapula and aponeurosis of subscapular muscle . By JOHN D. HILL 194
4. Congenital dislocation of wrist . By JAMES E. ADAMS 197
5. Destructive and reparative processes in two hip-joints By RICHARD DAVY 198
6. Necrosis of the patella . . . By C. KELLY, M.D. 198
7. Gunshot injuries of bone By W. MACCORMAC, introduced by Dr. QUAIN 199
8. Large and multiple exostoses of the skull with hyperostosis . . . . . By JAMES E. ADAMS 204
9. Fracture of head of radius . . By JAMES E. ADAMS 205
10. Osteo-colloid cancer of the skeleton By W. MOXON, M.D. 206

Digitized by Google

PAGE

Report By J. S. Bristowe and W. S. Church for *Committee on Morbid Growths* 210

11. Myeloid tumour of the head of the tibia By Marcus Beck 210

12. Medullary sarcoma of fibula . By H. Morris, M.B. 212

Report By J. B. Sanderson and T. Henry Green for *Committee on Morbid Growths* 214

13. Malignant osteoid tumour of fibula By Henry Arnott 214

VII.—DISEASES, ETC., OF THE ORGANS OF SPECIAL SENSE.

1. A case of gliomatous disease of the eyeball, with secondary deposits in the periosteum of the facial and cranial bones. With specimens and drawings By Spencer Watson 218

2. Demonstrations of diseases of the eye By R. Liebreich, introduced by Dr. Dickinson 221

3. A case of bony deposit in the eye associated with a peculiar deposit on the cornea By W. Spencer Watson 225

4. A case of bony deposit in the eye, the result of injury and cause of sympathetic ophthalmia By W. Spencer Watson 226

5. An ivory exostosis growing from the sclerotic coat of the eye . . . . By W. Spencer Watson 227

VIII.—TUMOURS.

1. Papillary growth of abdominal wall By Francis Mason 229

2. Tumour of breast By John Foster, for Mr. Joseph Thompson, of Nottingham 230

3. Epithelioma of the heart and lungs, secondary to epithelioma of the clitoris . . By Henry Arnott 231

Digitized by Google

PAGE

4. Fibro-cystic tumour from the axilla
By CHRISTOPHER HEATH 233

5. Case of large lymphoma in the pectoralregion
By C. DE MORGAN 236

Report By W. CAYLEY and HENRY ARNOTT for *Committee on Morbid Growths* 242

6. Lipoma of nose . . . By CHRISTOPHER HEATH 242

7. A case of recurrent tumour of the front of the leg
By W. SPENCER WATSON, for Dr. J. SWIFT WALKER, of Hanley 243

Report of the subsequent history of Dr. Walker's case of spindle-celled sarcoma of the leg By Dr. WALKER 245

Report By W. S. CHURCH for *Committee on Morbid Growths* 246

8. Scirrhus beginning in lower lip and extending to jaw
By J. W. HULKE 248

9. Case of cystic sarcoma of lower jaw
By W. W. WAGSTAFFE 249

Report By SEPTIMUS W. SIBLEY and J. W. HULKE for *Committee on Morbid Growths* 252

10. Exostosis . . By T. HOLMES for P. MARTYN, M.D. 253

11. Tumour of the upper jaw . . . By J. F. WEST 255

Report By J. W. HULKE and SEPTIMUS W. SIBLEY for *Committee on Morbid Growths* 256

12. Epulis tumours of the jaw . . By HENRY ARNOTT 257

13. Fatty masses contained in a ranula . By WAREN TAY 258

14. Facts as to the general diffusion of cancer
By WEEDEN COOKE 260

15. Cystic epithelioma of the cheek . By SPENCER WATSON 262

Report By W. S. CHURCH for *Committee on Morbid Growths* 263

16. Soft cancer of the female breast . By HENRY ARNOTT 264

17. A large cystic tumour of the breast in connection with a scirrhous carcinoma, which has undergone calcareous degeneration . . . By THOMAS SMITH 267

Digitized by Google

PAGE

Report By HENRY ARNOTT and WM. CAYLEY for *Committee on Morbid Growths* 268

18. Myxoma . . . . . By JOHN GAY 269

19. Hard fibrous tumour of the palate . By W. ADAMS 272

Report By HENRY ARNOTT for *Committee on Morbid Growths* 273

IX.—DISEASES, ETC., OF THE DUCTLESS GLANDS.

(A) SPLEEN.

1. Case of acute splenitis (?) in a syphilitic By WALTER MOXON 274

2. Specimen of enlarged spleen . . By W. SQUIRE 276

3. Morbid growths in the spleen, lymphatic glands and other organs (Hodgkin's disease), complicated with acute tuberculosis . . . By J. F. PAYNE, M.B. 278

(B) SUPRA-RENAL CAPSULES.

4. Addison's disease By RICHARD QUAIN, M.D., for Dr. SILVER 280

5. Addison's disease of supra-renal capsules; pigmentation of pia mater of spinal cord and of skin of genitals By J. F. PAYNE, M.B. 281

(C) THYROID.

6. Cancer of the thyroid body, subsequent to ordinary bronchocele . . . . . By J. F. PAYNE, M.B. 283

Report By J. S. BRISTOWE and THOS. P. PICK for *Committee on Morbid Growths* 286

Digitized by Google

(D) ABSORBENT GLANDS.

PAGE

7. Tumour of the lumbar glands
By W. Howship Dickinson, M.D. 287
Report By J. S. Bristowe and Thos. P. Pick for *Committee on Morbid Growths* 293
8. Mesenteric tumour By W. Howship Dickinson, M.D. 296
Report By J. S. Bristowe and Thos. P. Pick for *Committee on Morbid Growths* 302

X.—DISEASES, ETC., OF THE SKIN.

1. General alopœcia, with microscopic specimens of the hair and nails . . . . By Edwards Crisp, M.D. 305
2. Specimens of skin and liver from a case of diffused scleriasis By C. Hilton Fagge, M.D. 309
3. Keloid tumours from the ear . By Tilbury Fox, M.D. 313
4. Case of Devergie's pityriasis pilaris By Tilbury Fox, M.D. 313
5. Compound pedunculated growths of the skin developed from moles; A. Melanotic; B. Warty By Frederick Churchill 314
6. Effects of ether spray upon the skin in Addison's disease By F. Churchill 317

XI.—MISCELLANEOUS.

1. Fungus-foot of India . . By Tilbury Fox, M.D. 320
Report . . . . . By J. S. Bristowe 320
2. Cases of rodent ulcer . . . By J. W. Hulke 326
3. Two cases of pyæmia . . . By J. F. Payne, M.B. 332

Digitized by Google

PAGE

4. Cysts containing air from the peritoneum
By J. F. Payne, M.B. 336

5. Supposed case of smallpox at time of birth
By Henry Sutton, M.B. 343

Report
By Charles Murchison and H. Charlton Bastian 345

6. A hand completely flayed by machinery
By George Lawson 346

XII.—SPECIMENS FROM THE LOWER ANIMALS.

1. Ruptured stomach of dog . . By Richard Davy 347

2. Lungs and heart of a porpessa
By William Ogle, M.D., introduced by Dr. Whipham 347

3. Growths in the larynx of a dog
By Morell Mackenzie, M.D. 349

4. Specimens of cataract and of opacities of the cornea in the lower animals . . . By Edwards Crisp, M.D. 350

Digitized by Google

REPORTS OF THE COMMITTEE ON MORBID GROWTHS.

PAGE

1. On Dr. R. Bennett's case of secondary scirrhus of the lung (Dr. Bristowe and Mr. Pick) 82
2. On Dr. Whipham's case of columnar epithelioma of the liver (Dr. Cayley and Mr. H. Arnott) 169
3. On Dr. Moxon's case of osteo-colloid tumours (Dr. Bristowe and Dr. Church) 210
4. On Mr. Morris's case of sarcoma of the fibula (Dr. B. Sanderson and Dr. Green) 214
5. On Mr. De Morgan's specimen of lymph-adenoma of the axilla (Dr. Cayley and Mr. Arnott) 224
6. On Dr. Walker's case of recurrent tumour of the leg (Dr. Church) 246
7. On Mr. Wagstaffe's cystic sarcoma of lower jaw (Mr. Sibley and Mr. Hulke) 252
8. On Mr. West's tumour of upper jaw (Mr. Hulke and Mr. Sibley) 256
9. On Mr. S. Watson's case of cystic epithelioma of cheek (Dr. Church) 263
10. On Mr. Thomas Smith's case of large cystic tumour of breast (Mr. Arnott and Dr. Cayley) 268
11. On Mr. W. Adams' case of fibrous tumour of the palate (Mr. H. Arnott) 273
12. On Dr. Payne's specimen of tumour of thyroid (Dr. Bristowe and Mr. Pick) 286
13. On Dr. Dickinson's tumour of the lumbar glands (Dr. Bristowe and Mr. Pick) 293
14. On Dr. Dickinson's mesenteric tumour (Dr. Bristowe and Mr. Pick) 302

Digitized by Google

LIST OF PLATES.

	PAGE
I. Spinal Cord from a Case of Motor Ataxy. (Dr. GREENHOW)	17
II. Atrophy of the Cerebellum. (Dr. CLAPTON) . .	21
III. Figs. 1 and 2. Case of Paralysis Agitans. (Dr. MURCHISON and Dr. CAYLEY)	26
Fig. 3. Epithelioma of the Lung. (Mr. H. ARNOTT) .	
Fig. 4. Soft Cancer of the Female Breast. (Mr. H. ARNOTT)	
IV. Malformation of the Heart: great Contraction of Pulmonary Artery, &c. (Dr. PEACOCK) . .	88
V. Figs. 1, 2, and 3. Tumour of the Lower Jaw. (Mr. WAGSTAFFE)	252
Figs. 4 and 5. Fibrous Tumour of the Heart. (Mr. WAGSTAFFE)	
VI. Pedunculated Growth from the Skin. (Mr. FRED. CHURCHILL)	316

Digitized by Google

Digitized by Google

LIST OF WOODCUTS.

PAGE

1. Fatal hæmoptysis in advanced phthisis; small oval dilatation of a branch of the pulmonary artery (Dr. D. Powell) 48
2. Ditto, division of a main branch of the pulmonary artery into two branches, &c. (Ditto) . . . 51
3. Identity of gray and yellow tubercles; zone of clusters of yellow and gray tubercles (Dr. Moxon) . . 66
4. Fibro-cancerous infiltration of connective tissue of lung; section showing fibroid growth (Dr. R. Bennett) . 81
5. Sphygmographic tracing in case of aneurism of the arch of the aorta (Dr. C. T. Williams) . . . 102
7. Unnatural extension of kidney (Dr. Heywood Smith) . 175
8. Osteo-colloid cancer of the skeleton; fine section of growth in the cranium, ⅛ in. power (Dr. Moxon) . . 207
9. Ditto, ditto, ⅛ in. power (Ditto) 208
10. Swelling of leg produced by malignant osteoid tumour of fibula (Mr. H. Arnott) 216
11. Gliomatous disease of the eyeball; side view of face a few days before death (Mr. Spencer Watson) . . 219
12. Ditto, extension of disease to left orbit (Ditto) . . 220
13. Disease of the eye; persistent hyaloid artery and vein (Dr. Liebreich) 222
14. Bony laminæ and Haversian systems in exostosis of the sclerotic (Mr. Spencer Watson) . . . 228

Digitized by Google

PAGE

15. Papillary growth of abdominal walls (Mr. F. MASON) . 229
16, 17. Fibro-cystic tumour of axilla (Mr. C. HEATH) 234, 235
18. Lymphoma in pectoral region; the external swelling caused by the tumour (Mr. DE MORGAN) . . . 237
19. Ditto, microscopic structure (Ditto) . . . 240
20. Cystic sarcoma of the lower jaw; lines of section of the bone in removal (Mr. WAGSTAFFE) . . . 249
21. Tumour of the lumbar glands; lines showing extent of dulness (Dr. DICKINSON) 288
22. Ditto, position of tumour after removal of small bowel (Ditto) 289
23. Ditto, cells, fibres and nuclei, from solid part of growth (Ditto) 291
24. Ditto, structure of superficial growth (Ditto) . . 292
25. Mesenteric tumour; outline during life (Dr. DICKINSON) 297
26. Ditto, relations as seen on opening abdominal cavity (Ditto) 298
27. Ditto, microscopic elements of the muciform fluid (Ditto) . 300
28. Ditto, epithelial cells found in cysts (Committee on Morbid Growths) 303
29. General alopæcia; microscopic specimens of the hair and nails (Dr. CRISP) 308
30. Fungus-foot of India; fragment from circumference of truffle-like body (Report by Dr. BRISTOWE) . . 321
31. Ditto, minute lobule, more highly magnified (Ditto) . 322
32. Ditto, large coloured tubes (Ditto) 323
33. Ditto, spectroscopic examination (Ditto) . . . 325
34. Rodent cancer; new growth of cell-tissue (Mr. HULKE) . 327
35. Ditto, neoplasm, and proliferating connective substance substance (Ditto) 328
36. Ditto, section through indurated tissue bounding the ulcer (Ditto) 331
37. Specimens of cataract in the bear, antelope, kangaroo, and heron (Dr. CRISP) 350

Digitized by Google

REPORT OF THE COMMITTEE

ON

LARDACEOUS DISEASE.

THE Committee presenting the Report about to be laid before the Society was nominated on the 16th of March, 1869, under the presidency of Dr. Quain.[1]

The members were Dr. Wilks, Dr. Bristowe, Dr. Andrew, Dr. Dickinson, and Dr. Marcet.

The Committee was directed to report "On the nature of the so-called Lardaceous Disease, and as to the name by which it should be recognised."

It was determined to limit the inquiry to the nature of the chemical changes in the affected organs. Dr. Marcet was entrusted with the investigation, and empowered to obtain the assistance of Dr. Dupré.

General Report of the Committee upon Lardaceous Disease.

The Committee, in presenting their report, think it right to state that it comprises the fruit of much time, labour, and expense.

The analyses of Dr. Marcet, whose report is appended, show

[1] The committee was formed in consequence of a suggestion by Dr. Dickinson in connection with a specimen which he exhibited of lardaceous disease consequent upon abscess of the ovary. See 'Trans.,' vol. xx, p. 435.

Digitized by Google

that the organs which have been examined as presenting the alteration in question are considerably deficient in potash and phosphoric acid, while they contain an increase of soda, chlorine, and cholesterine.

Where the tissue is extensively affected it is rendered much less soluble in water than in its normal condition, the insoluble portion, which is nitrogenous, being readily soluble in potash.

When iodine is brought into contact with the affected structure it enters into combination with a peculiar nitrogenous substance, by which the tissue is pervaded and produces the reddish-brown reaction familiarly recognised as the test of the morbid change. When the lardaceous change is incomplete the nitrogenous material which gives the reaction can be extracted by water. Both the iodine reaction and the substance to which it is due have been carefully investigated, together with the relationship existing between this substance and a solution of fibrin in dilute hydrochloric acid.

In reference to the name which should be applied to this morbid condition, the Committee, after due deliberation, suggest that the term *Lardaceous* should be adopted by the Society. This term, they believe, is widely used and well understood in the sense to which they desire to restrict it; but they nevertheless think it proper to insist that the word be explicitly limited to organs so altered as to present the chemical characteristics described in the report, the most obvious of which is the reddish-brown reaction with iodine.

WILLIAM MARCET,
SAMUEL WILKS,
J. S. BRISTOWE,
J. ANDREW,
W. HOWSHIP DICKINSON.

May 16*th*, 1871.

Digitized by Google

Details of the Inquiry.

First Chemical Report by Dr. Marcet.

Attention was first directed to the saline constituents of lardaceous as compared with healthy organs. The liver was selected for the observations. The following results were obtained by Dr. Dupré:

Observations upon the saline constituents of three healthy and three lardaceous livers. The portion of tissue used in each instance was 200 grammes.

Three healthy livers.

	Potash.	Soda.	Phosphoric acid.	Chlorine.
Healthy liver No. 1	·6044	·2001	·4625	·2503
„ „ No. 2	·4840	·2380	·7805	·2447
„ „ No. 3	·6042	·1310	·7340	·1391

Three lardaceous livers.

	Potash.	Soda.	Phosphoric acid.	Chlorine.
No. 1	·3458	·2997	·3553	·3032
No. 2 (from phthisis with large vomicæ)	·1826	·3491	·6400	·3115
No. 3 (from tubercular excavation of kidney, &c.)	·2630	·4925	·1935	·3832

In these observations 200 grammes of hepatic tissue were mixed and treated with 500 grammes of water, the extract thus produced being subjected to analysis.

Digitized by Google

Observations by Dr. Marcet relating to the preceding table.
December 30th, 1869.

"From these facts I conclude that the potass and phosphoric acid known to be essential to the process of the healthy nutrition of tissues are considerably deficient in the lardaceous liver; and on the other hand, that the soda and chlorine, which act but a secondary part in healthy nutrition, are increased. It would be of the highest interest to supplement this inquiry by a series of analyses of the blood in persons affected by this disease."

Report of the Committee on the preceding Observations.

"The Committee regard the facts established by these analyses as of the highest importance, since they point to important differences between the mineral constituents of lardaceous and healthy tissues, and so far confirm the analyses of Dr. Dickinson. The analyses show that the abnormal material does not correspond in its chemical relations either with fat or cholesterine, but has characters resembling, but apparently not identical with, albumen." *December 30th*, 1869.

Second Chemical Report by Dr. Marcet.

Since the first part of the present report was communicated to the Committee of the Pathological Society several samples of lardaceous liver have been examined; some were kindly supplied to me by Dr. Dickinson from St. George's Hospital, and others by Dr. Murray from the Middlesex Hospital. Dr. Dickinson's samples were instances of complete and exclusively lardaceous degeneration, while those I received from the Middlesex Hospital had undergone fatty degeneration in addition to lardaceous metamorphosis. This was shown by the proportion of fatty matters they yielded to ether, by the increase of their carbon much beyond its normal proportion, and the decrease of their nitrogen. Dr. Dickinson procured for

Digitized by Google

me a healthy human liver, which was that of a child killed by accident; this sample was very useful as a means of comparison with those affected with lardaceous disease.

Cholesterine in lardaceous liver.—My attention has been drawn by the Committee to a statement that lardaceous livers contain a large quantity of cholesterine, as one of the special features of the disease, and I have inquired into this question.

With this object in view a portion of a lardaceous liver which was in no way fatty was minced and treated with water; the insoluble mass was repeatedly boiled in alcohol and strained. The alcoholic extract, on being mixed with an equal bulk of milk of lime, yielded a precipitate, and this precipitate was collected on a filter, washed, dried, and exhausted with ether. By spontaneous evaporation the ethereal solution deposited a rather large quantity of cholesterine. It was important to ascertain whether healthy liver might not also contain this substance. In order to answer this question a portion of the liver of a child killed by accident, and perfectly healthy, was submitted to the same process, the only difference being that the minced tissue was mixed with alcohol at once instead of undergoing a first treatment with water. The precipitate with milk of lime in the alcoholic extract yielded to ether a solution which by spontaneous evaporation also deposited crystals of cholesterine, although in a smaller quantity than in the case of lardaceous tissue. Hence I conclude that the presence of chloresterine in lardaceous livers has nothing exceptional, and is a phenomenon in common with what occurs in healthy livers, the only difference being a larger proportion of the substance in the diseased than in the normal gland.

Character of lardaceous livers also fatty.—On examining a fresh section of these livers it appeared as if inlaid with a white substance which was due to the partial transformation of the hepatic tissue into fat; the white streaks consisted of fat, and the darker parts were formed of hepatic tissue, which had apparently undergone partly or entirely the lardaceous metamorphosis. The substance of these livers was cut into very thin slices and immersed in ether, when the mottled appearance of the tissue disappeared after a short time, exhibiting a perfectly uniform reddish colour.

The chemical characters of these fatty lardaceous livers have been

Digitized by Google

carefully investigated by the determination of the nitrogen and carbon in a sample of the tissue together with that of the fat it contained.

It was assumed that the whole of the nitrogenous substances existed in the form of an albuminoid compound.

The process was first applied to healthy hepatic tissue as follows:

Composition of healthy human liver.—A sample of dry, healthy, human liver yielded 45·55 per cent. of carbon and 13 per cent. of fat. This fat, considered as stearine, contained 9·94 of carbon, which, subtracted from the total carbon found in the livers, would leave 35·61 of carbon, corresponding to 67·2 of albuminoid substances. On the other hand, the whole of the nitrogen in this liver amounted to 11·69 per cent., corresponding to 74·2 of albuminoid substances. This shows that in 100 of liver the whole of the carbon is not present as fat and the whole of the nitrogen not present as albumen by a difference of 7.

Composition of healthy sheep's liver.—A sample of dry sheep's liver being submitted to analysis in the same way, yielded the following results:

Carbon	44·00	per cent.
Nitrogen	9·12	„
Fat	24·90	„
Carbon in fat	19·00	„
Total carbon	44·07	„
Carbon in albumen	25·07	„

Equivalent to 47·3 albumen.
N. found (9·12) equal to 58·1 albumen.
47·3

Difference 10·8

Showing that in 100 of dry sheep's liver the whole of the carbon is not present as fat and the whole of the nitrogen not present as albumen by a difference of 10·8.

Digitized by Google

Composition of lardaceous liver also fatty.—The analysis of a sample of human liver lardaceous and fatty, performed according to the same process, yielded the following results:

Carbon	62·99
Nitrogen	9·00
Fat	35·30
Carbon in fat	27·18
Total carbon	62·97
	35·79

Equivalent to 67 albumen.
Nitrogen found (9·0) equivalent to 57·3 albumen.

Showing that in 100 parts of this liver the whole of the carbon is not present as fat and the whole of the nitrogen not present as albumen by a difference of 9·7; consequently this sample of liver lardaceous and fatty contained a much higher proportion of fat and carbon than healthy liver, but no other chemical change had apparently taken place; so far, therefore, the organic portion of pure lardaceous non-fatty livers appears to have the same composition as that of healthy hepatic tissue. The increase of the proportion of fat in the lardaceous and fatty livers is very remarkable, amounting in another case to no less than 64 per cent. of the dry tissue.

Composition of the aqueous extract of livers.—I now undertook a comparative examination of the watery extract of liver in health and in lardaceous disease, with the object of inquiring into the nature of the iodine reaction considered as peculiar to lardaceous tissue. The question to answer was—What is the nature of the reddish-brown reaction due to the application of a solution of iodine to a section of a lardaceous liver?

Dr. Dickinson having observed that a solution of fibrin in dilute hydrochloric acid gave with pure iodine a precipitate of the same colour as that of the lardaceous reaction, kindly sent me for examination a sample of this precipitate suspended in water.

The extracts of liver, healthy and diseased, after being boiled and filtered for the separation of the albumen, were acidified with dilute

Digitized by Google

hydrochloric acid,[1] and mixed with a solution of iodine in iodide of potassium, when a reddish-brown precipitate was found in both cases. Care was taken to have a considerable excess of iodine present. The precipitate obtained under the three circumstances mentioned above were therefore similar, as far as their appearance was concerned; they were also equally soluble in dilute alkalies.

What did these precipitates consist of? Had they the same or different chemical compositions? In order to answer these questions, the precipitates were submitted to a careful examination, the results of the inquiry being disposed under the form of the following table.

[1] In the extracts of healthy liver hardly any precipitate or turbidity appeared unless in the presence of dilute hydrochloric acid, while in the extract of the lardaceous livers a dense turbidity formed at once by the addition of the solution of iodine, which assumed the form of a distinct and bulky precipitate when the fluid was acidified.

Digitized by Google

Examination of the precipitate obtained by the addition of iodine to extracts of a healthy sheep's liver and a human lardaceous and fatty liver, and also to a solution of fibrin in dilute hydrochloric acid. The precipitate exhibits the same reddish-brown colour and the same solubility in alkalies in every case.

Precipitate with an aqueous solution of iodine in extracts of sheep's liver, the albumen removed by coagulation.		Precipitate with an aqueous solution of iodine in an extract of a human lardaceous and fatty liver. The albumen removed by coagulation.		Precipitate with iodine in a solution of fibrin in dilute hydrochloric acid.
Portion of the precipitate soluble in alcohol and ether mixed.	The solution has a dark port-wine colour; evaporated to dryness it loses entirely the iodine it contains. The residue is insoluble in ether, but slightly soluble in water; it contains nitrogen.	Portion of the precipitate soluble in alcohol and ether mixed.	The solution has a dark port-wine colour; evaporated to dryness it loses entirely the iodine it contains, or nearly so (a trace was found present). The residue is insoluble in ether, but soluble in alcohol and water, especially with aid of heat, and contains nitrogen.	The precipitate is entirely soluble in a mixture of equal parts of alcohol and ether. The solution has a dark port-wine colour; evaporated to dryness (and treated again if necessary) it loses entirely the iodine it contains. The residue has the appearance of a pale-coloured jelly, which is but very slightly soluble in water, and is insoluble in alcohol. It dissolves in dilute potash, and this solution yields afresh the original reddish-brown precipitate by the addition to it of a solution of iodine and dilute hydrochloric acid. The residue contained nitrogen.
Portion of the precipitate insoluble in alcohol and ether, is free from iodine and contains nitrogen. It is nearly entirely soluble in water.		Portion of the precipitate insoluble in alcohol and ether, is insoluble in hot and cold water, and contains nitrogen and a trace of iodine.		

Digitized by Google

From this investigation it follows—

1st. That in all three of the iodine precipitates the iodine is very loosely combined with the other substances which enter into their formation, so much so that the mere evaporation of the alcoholic solution of the precipitates suffices to rid the mass entirely, or nearly so, of the whole of the iodine originally present.

2ndly. That the iodine precipitates in the extracts of healthy and diseased liver differed from each other with respect to the reactions exhibited by the material they yielded to a mixture of alcohol and ether; this material, when free from iodine, being but slightly, if at all, soluble in water in the case of healthy liver, though soluble in water in the case of the diseased liver. They also differed from each other by the degree of solubility in water (when free from iodine) of their constituents insoluble in alcohol and ether; this substance from the healthy liver being nearly entirely soluble in water, while that obtained from the lardaceous liver was insoluble in water, both, however, containing nitrogen.

3rdly. That the iodine precipitates in the solution of fibrin resembled, in many respects, the portion of the precipitate obtained from the extract of the healthy liver which was soluble in a mixture of alcohol and ether. The characters found to be the same in both of these cases were—

a. Their solubility in mixed alcohol and ether.

b. Their loose degree of combination with iodine, which in both cases caused the entire separation of the iodine by mere evaporation of the solution.

In the case of the fibrin the residue had to be treated three times with alcohol and evaporated down to dryness, but the final result was the complete volatilization of the iodine.

c. Their both containing nitrogen.

The only difference between these two materials, as far as their properties were concerned, appeared to exist in the degree of solubility in water of the substances when free from iodine, but even on that point I could not obtain a satisfactory conclusion, and I would think it well worth the while to pursue the inquiry, and ascertain by chemical analysis, and a further investigation in other respects, whether these two substances are really the same. It would be of very great interest, in a physiological point of view, to find that healthy liver actually contains the same substances as that which is obtained artificially by dissolving fibrin or albumen in a

Digitized by Google

dilute acid. But so far I cannot consider that the present inquiry has shown these substances to be identical.

4thly. That the insolubility in water of the main portion of the mass precipitated by iodine from the extract of a lardaceous liver accounts perfectly for the iodine reaction, which is considered and acknowledged as the test of lardaceous tissue. The precipitate obtained by adding a solution of iodine to an extract of healthy liver does not form, or is but very slight, hardly amounting to more than a haziness, unless hydrochloric acid or another dilute acid be added to the fluid, while the addition of iodine to an extract of lardaceous liver causes a bulky turbidity or a precipitate at once, which, however, is favoured by the presence of dilute hydrochloric acid. It is this precipitate which, forming in the lardaceous tissue when it is tested with iodine, gives the reddish-brown reaction; as no precipitate takes place under this circumstance in the healthy liver, no reaction occurs.

The precipitate forms in the diseased and not in the healthy liver, because the principal substance precipitated is soluble in water in the case of the healthy liver, and insoluble in water in that of the diseased gland. This interesting substance insoluble in water, when in the free state, is, however, soluble in the liver, as shown from its presence in an aqueous solution obtained from the organ; hence, although one of the substances is soluble in water, and the other not, they are both soluble in the liver and the extract obtained from it. It is obvious that the attraction of the iodine for the substance in the lardaceous liver sufficed to overcome the circumstance which held this substance in solution in the liver, and to throw it down as the characteristic reddish-brown precipitate, while in the case of the healthy liver, this substance being soluble when free, iodine failed to make it insoluble in the hepatic tissue.

An attempt was undertaken to determine the nitrogen in a portion of the iodine precipitate, insoluble in alcohol and ether, obtained from a lardaceous liver; it still contained a trace of iodine. The analysis yielded 12·6 per cent.[1] of nitrogen, which is much less than that contained in albumen, amounting to 15·7 per cent.

Examination of purely and completely lardaceous liver.—The livers which yielded the results obtained above were fatty as well as lar-

[1] No conclusion can be drawn from this analysis.

Digitized by Google

daceous. Dr. Dickinson having kindly supplied me with a very good specimen of a liver entirely lardaceous and in no way fatty, I endeavoured to prepare in the pure state the material which formed its substance, with the object of determining the proportion of nitrogen it contained. For this purpose a portion of the tissue was dissolved in potash and then precipitated with hydrochloric acid; the precipitate was redissolved in potash, again precipitated with acetic acid, and washed. Three analyses of this substance, when dry, yielded respectively 14·4, 13·4, and 13·5 per cent. of nitrogen, showing apparently that the substance was of an albuminous origin, albumen containing 15·7 per cent. of nitrogen. This result is not, however, conclusive, as I have no reliable evidence that my substance was quite pure, and I may have been analysing albumen in an impure state.

The conclusion from the present inquiry, respecting the cause of the iodine reaction on lardaceous tissue and the nature of this tissue as investigated in lardaceous livers, is, therefore—1st. That this reaction is due to the precipitation, in a loose state of combination with iodine, of a substance invariably present in lardaceous tissue, which, when free from iodine, is insoluble in water, alcohol, and ether. 2nd. That the substance of lardaceous livers may be called *albuminoid*, although the proportion of nitrogen it was found to contain appeared to be somewhat lower than that which exists in albumen.

WILLIAM MARCET.

May 16*th*, 1871.

Digitized by Google

REPORT.

SESSION 1870-71.

I.—DISEASES, ETC., OF THE NERVOUS SYSTEM.

1. *Embolism of the left middle cerebral artery of more than six weeks' standing; yellow induration of the corpus striatum, with surrounding white softening.*

By C. Hilton Fagge, M.D.

Amelia F—, æt. 25, was in Guy's Hospital under Dr. Habershon's care, on account of right hemiplegia with aphasia, with which she was attacked on September 5th, 1870. She died on October 16th. The post-mortem examination was made by me, in the absence of Dr. Moxon, on October 17th.

When the brain was removed it was at once seen that the left middle lobe was soft, flaccid, and wasted at its extremity, and had thus a pointed form. There was much abnormal adhesion about the Sylvian fissure, so that the middle cerebral artery was difficult to trace. When exposed, it was found to be occupied for, perhaps, half an inch with white coagulum. It rested immediately on a hard mass, in which, in fact, it almost seemed to be imbedded.

On opening the left lateral ventricle it was found that the corpus striatum was markedly flattened. It had, however, generally the appearance of having undergone white softening, excepting that part of its surface had a yellow look. When an incision was made into it this was found to be due to the presence of a large mass of yellow, rather firm substance in its interior, nearly reaching the surface. This

Digitized by Google

was continuous with the mass already mentioned as existing in the Sylvian fissure.

On microscopical examination the diseased part of the corpus striatum was found to contain a large quantity of fatty granules and many opaque compound granule masses. Few nerve-tubes were seen, and these had undergone a marked granular change.

Unfortunately, the brain was thrown away before there was an opportunity of making a careful dissection of the affected artery. The embolism arose from disease of the mitral valve. There were small embolic patches also in the spleen and kidneys.

Remarks.—This case is of interest because it enables us to trace the local effects of an embolism of one of the cerebral arteries at a period when it does not very often happen that we are called upon to make a post-mortem examination. One is taught in standard works on the subject that when the middle cerebral artery becomes obstructed the corresponding part of the brain undergoes white or in some cases red softening. In this instance, however, the greater part of the corpus striatum was in a very different condition, forming a yellow mass, at least as firm as the healthy brain substance, and very like in appearance to an "infarctus" of the spleen or kidney. A similar case has already been recorded by Dr. Wilson Fox, in the eighteenth volume of the 'Transactions of the Pathological Society,' and in their well-known papers on cerebral softening in the 'Gazette Médicale' for 1866 MM. Prévost and Cotard relate an experiment in which they injected tobacco seeds into the carotid of a dog, and, having killed the animal thirty-nine days afterwards, found that the fissure of Sylvius was occupied by a yellow patch of firmer consistence than the rest of the brain. The corresponding Sylvian artery was obstructed by tobacco seeds. *October* 18*th*, 1870.

---

2. *Spinal cord from a case of motor ataxy.*

By E. Headlam Greenhow, M.D.

The patient from whom the specimen was taken had been under my care for upwards of five years before his death. His case was brought before the Clinical Society in the year 1868, and

Digitized by Google

published in the first volume of the Society's 'Transactions' (p. 95), supplemented by a very able report from Drs. Bastian and Buzzard, who examined the patient on several occasions whilst he was in the Middlesex Hospital under my care.

R. R— was about 57 years of age when he died in November of the present year. He had been for many years an ironmonger's porter, in which occupation he had been accustomed to carry heavy weights upon his back and shoulders. In early life he had during several years been subject to epilepsy, and had also had delirium tremens and rheumatic fever, but an interval of at least fifteen years had occurred between his recovery from the last of these ailments and the accession of the earliest symptoms of spinal disease.

When R. R— first came under my care he had the staggering, unsteady gait, and the inability to walk unless his movements were guided by sight, which are so characteristic of that form of paraplegia to which the name of progressive locomotor ataxy has been generally applied. He also suffered from severe pains in various parts of the lower limbs, only of momentary duration, but often recurring in the same situation in a more or less rapid succession of shocks for many hours at a time. The pains would then abandon their first seat, but would sometimes recommence immediately in some other part of the same limb, or in the opposite one, whilst at other times they would cease entirely for several hours, or even for several days together. There was likewise disorder of the organs of special sense. The pupils were excessively contracted, and the focal distances of the eyes differed, that of the right being four inches less than that of the left eye. On examination with the ophthalmoscope the retinal arteries were seen to be small, and the optic disc pale. The senses of hearing, smell, and taste, were all more or less impaired, as was the sense of touch over the face and inside of the mouth, and the patient was also frequently troubled with a sense of unpleasant subjective odours. The general sensibility of the trunk and limbs was everywhere more or less impaired; sensibility to pain was almost abolished; electro-sensibility was greatly diminished; sensibility to changes of temperature was so much impaired that hot or cold applications only produced the impression of contact, not that of temperature. Tactile sensibility, though greatly blunted, was less impaired, but impressions made by touch were slowly appreciated. On the other hand, reflex sensibility was greatly increased; any contact with his limbs of which he was not made aware

Digitized by Google

by his sight, for example, even so trifling a touch as that produced by the falling of a bed-card upon his limbs, or the graze of a woman's dress as she passed him in the street, would produce violent and spasmodic action of the lower limbs, attended by a sense of alarm, often causing him in the one case to start up in bed, and in the other almost to fall down in the street. From the day when he first came under my observation his urine was highly ammoniacal, and though it dribbled away almost constantly the bladder was never quite empty except when the catheter was used. The urine also contained a notable quantity of pus. During the last two years of life he had several severe attacks of hæmaturia. He gradually became worse, and for some time before death he was entirely unable to raise himself or even to move in bed without assistance, but he retained his intellect until within a few hours of his death, which took place on the 15th of November.

Post-mortem examination.—Body emaciated; muscular system well-developed. The liver was of moderate size; its surface somewhat granular, as if from a slight degree of cirrhosis. The left kidney was sacculated, its pelvis was filled with thin purulent fluid, and the adjacent renal tissue was ulcerated; the corresponding ureter was dilated and thickened. The right kidney and ureter appeared to be normal. The bladder was thickened, its mucous membrane intensely congested, somewhat ragged and shreddy at the base, and almost black from extravasation.

The skull-cap was enormously thickened, and its tissue very dense. The dura mater was normal; the arachnoid much thickened. There was a considerable quantity of sub-arachnoid fluid. The brain itself presented nothing abnormal to the naked eye; the spinal cord throughout its whole length appeared to be of much smaller size than usual. Its texture was firm, and on transverse sections being made the posterior columns were seen to be replaced by a semi-transparent gray tissue throughout the cervical, dorsal, and lumbar regions.

Microscopical examination.—Dr. Cayley has kindly favoured me with the following report:—"The cord was hardened in spirit and chromic acid, and thin sections taken from different portions were submitted to microscopical examination after being stained with carmine, and subsequently treated either with carbolic acid or with absolute alcohol and turpentine. The pia mater, especially posteriorly, was much thickened and very adherent. The posterior

Digitized by Google

Digitized by Google

DESCRIPTION OF PLATE I,

Illustrating Dr. Greenhow's case of Motor Ataxy (p. 14).

Fig. 1 represents a section of spinal cord, showing—

a. Thickened vessels.
b. Remains of wasted nerve-fibres.
c. Unaltered nerve-fibres.

Fig. 2 represents a section of optic nerve, showing thickened vessels and septa.

Fig. 3 represents the thickened vessels and corpora amylacea from posterior cornua of gray matter.

Fig. 4 represents the posterior roots of spinal nerves, studded with corpora amylacea.

Digitized by Google

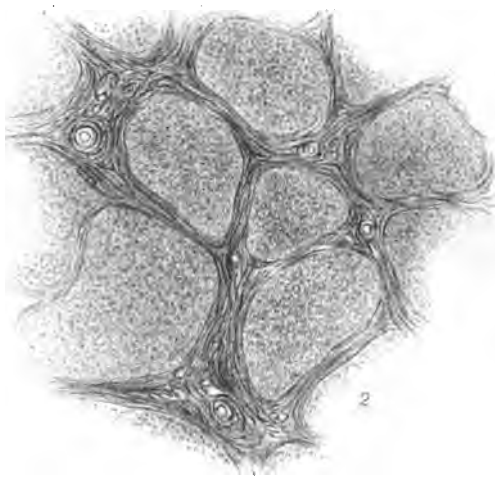

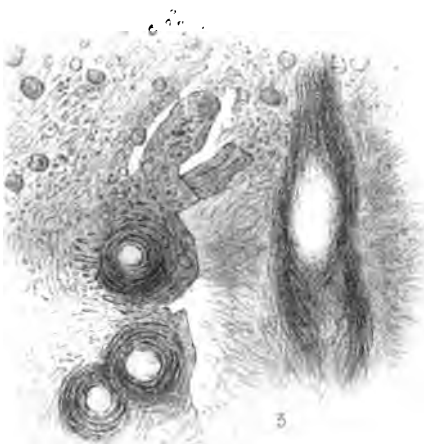



Digitized by Google

Digitized by Google

columns were much diminished in bulk, and in the lower dorsal region consisted of a finely reticulated granular substance thickly strewn with corpora amylacea, no nerve-fibre remaining. The walls of the arteries were greatly thickened, chiefly from hypertrophy of the tunica adventitia, though the circular muscular fibres also appeared abnormally thick. In many instances the walls had a homogeneous glistening appearance, but gave no amyloid reaction with iodine, whilst the corpora amylacea became deeply stained with it. Scattered in the reticulated substance were a few round nuclei. The posterior roots of the nerves were thickly studded with corpora amylacea; no oil-globules were seen. The vessels in the gray matter, especially in the posterior columns, were likewise much thickened; the nerve-cells appeared normal; the white substance of the antero-lateral columns was for the most part normal, but in the dorsal region, for some little distance externally to the posterior roots of the nerves, the superficial layer immediately beneath the pia mater showed degeneration similar to that in the posterior columns, the axis cylinders having disappeared, and the remaining reticulated ground-substance being studded here and there with corpora amylacea. The vessels in the antero-lateral columns also appeared thickened, but to a less extent than in the posterior columns and gray matter. In passing up the cord the degeneration was found to become less and less extensive; the posterior columns gradually showing an increased number of unaltered longitudinal nerve-fibres with distinct axis cylinders, but throughout the whole length the parts of the posterior columns adjacent to the posterior fissure and posterior surface were completely degenerated.

The lower part of the medulla was unfortunately destroyed in removing the cord; the upper part and the pons presented nothing abnormal.

Transverse sections of the optic nerves and optic commissure were examined. No change was observed in the nerve elements, but the fibrous septa appeared thickened, and the vessels in them were likewise thickened, and many of them had a homogeneous glistening appearance. (Plate I.) *December 20th*, 1870.

Digitized by Google

3. *Spindle-celled sarcoma connected with the posterior tibial nerve.*

By Marcus Beck.

G. G —, æt. 32, gardener. The patient had always enjoyed good health till four years ago, when he began to suffer from pain and slight tenderness in the lower part of the right leg and in the sole of the foot. The pain was not constant, it was severe, and of a shooting character, and was increased by exercise. About two and a half years ago the limb began slowly to enlarge in the lower third. He applied for relief at St. George's Hospital about two years ago, and was seen by one of the surgeons, who passed a grooved needle into the tumour. No fluid was found, and he was advised to let it alone and return to show himself in a year's time. From that time till his admission into University College Hospital on December 28th, the tumour had continued slowly to increase; lately the increase had been more rapid and the pain had become more severe and constant, but he had been able to continue his work as a gardener up to the time of admission. There was no history of syphilis.

On admission a distinct tumour was found situated below and partly beneath the natural prominence of the calf. The circumference of the diseased limb over the tumour was one inch greater than that of the sound one at the same place. The tumour projected to the inner side of the limb from beneath the superficial muscles; it was slightly moveable chiefly in a lateral direction. The skin was freely moveable over it, and there were no enlarged veins on the surface. The tumour was excessively tender when pressed upon, especially at the inner side. About one and a quarter inch from the inner edge of the tibia the posterior tibial artery could be felt displaced considerably to the inner side and pulsating under the skin.

On January 4th Mr. Erichsen made an incision at the inner side of the limb so as to open up the space between the superficial and deep layers of muscles, with the view of ascertaining, if possible, the exact nature and connections of the growth, as the patient would not consent to any further proceeding. The conclusions arrived at were that it was a soft solid tumour, having connections with some of the deeper parts of the limb, probably the fibula, and that amputation was the only resource; and as the nature of the growth was

Digitized by Google

so uncertain, it was considered safer to remove the whole of the bones with which it could possibly be connected by amputating through the knee-joint. This operation was performed on January 25th, and the patient made a good recovery.

On examining the limb after removal an oval tumour about three and a half inches in length by two in breadth was found situated between the superficial and deep layers of muscles; the posterior tibial nerve was spread out over its surface, and the artery was lying to its inner side in the position in which it had been felt before removal. The tumour was enclosed in a sort of double capsule, the first being composed of the deep fascia of the limb thickened by pressure and of the surrounding muscles. The flexor longus pollicis was spread out over part of the outer side of the capsule. From this outer capsule the tumour could be readily separated by the tip of the finger, leaving it connected solely with the posterior tibial nerve, which was spread out over its inner side and firmly blended with the special capsule of the growth. On making a section into the mass by the side of the nerve it was found to be excessively soft, breaking down at the slightest pressure. It was of a dirty pink colour, with a few dark red spots, apparently due to hæmorrhages. The nerve above and below the tumour was considerably swollen, but this was probably due to the inflammation set up by the exploratory incision.

On microscopic examination it was found to be composed almost entirely of delicate spindle-cells, measuring about $\frac{1}{500}$ inch in length and $\frac{1}{2500}$ inch in breadth. Each contained a single oval granular nucleus measuring about $\frac{1}{2000}$ inch in length, and $\frac{1}{3000}$ inch in breadth, and in each nucleus was a single nucleolus. The intercellular substance in many parts was delicately fibrillated, but no distinct fibres were found except in the capsule. Each specimen showed several sections of vessels, and in some small extravasations of blood were found.

From the ready way in which the tumour could be isolated from all the surrounding parts except the nerve, and from the early period in the history at which pain became a prominent symptom, it seems clear that the growth originated in the neurilemma, and not in the intermuscular cellular tissue, involving the nerve merely by pressure. *March 7th*, 1871.

Digitized by Google

4. *Atrophy of the cerebellum.*

By Edward Clapton, M.D.

M. A. F—, æt. 33, married, was admitted into St. Thomas's Hospital, under my care, on the 20th December, 1870. She was suffering from pleurisy and extreme prostration. The abdomen was hard and distended, but there was no indication of pain on pressure. Her manner was peculiar; she would answer questions promptly but not rationally; was unable to recognise her friends. Her hands were very tremulous when moved, and she was unable to feed herself. Pulse very frequent and feeble. Breathing short and rapid. She had been married one year, and was confined a month previous to admission; was said to have been very delirious for a day or two after her confinement. She died nine days after admission. An hour before death she startled the nurses by suddenly rising and manifesting a considerable degree of muscular strength. There were no convulsive movements.

Her husband informed me that he was only acquainted with her for a short time before their marriage. She could take long walks, but was obliged to walk slowly, and during her pregnancy her gait was very unsteady; was somewhat dull of comprehension, but could read and write, and carried on all her domestic duties very fairly. Her brother had informed him that, as a child, she was very backward in intellect and delicate in health, and that she was unable to walk until six years of age, and up to fourteen could not guide her hand to her mouth, so that she was obliged to be fed. My clinical clerk, Mr. Newby, took some trouble to find out her mother, and her account was to the effect that up to the age of four her daughter was a very healthy child; that at that period she was attacked with measles, after which she was unable to walk or talk for six months; that from that time up to the age of fifteen she walked very unsteadily, and was not able to use her hands with ease or certainty; and that she was of dull intellect. With regard to the theory which assigns the cerebellum as the organ of sexual instinct, I may mention that, according to her husband's account, everything was perfectly normal in respect of her generative functions.

Post-mortem examination.—The membranes of the brain appeared

Digitized by Google

Digitized by Google

DESCRIPTION OF PLATE II,

(*From drawings by* G. STEWART, M.D.),

Illustrating Dr. Clapton's case of Atrophy of the Cerebellum (page 20).

Fig. *a* represents the vertical section of cerebellum from its posterior and most atrophied part. The section extends from the surface to a point a little below the ganglionic layer. It shows an almost complete absence of proper nerve-substance, with great increase of the neuroglia; also spherical transparent and apparently homogeneous bodies, which stained deeply with carmine.

Fig. *b* represents the vertical section of same cerebellum from its least atrophied part. The structure apparently normal.

Digitized by Google

b

a

Digitized by Google

Digitized by Google

healthy. The cerebellum was remarkably small, and the posterior fossæ of the skull small in proportion. The spinal cord was removed, and throughout the pia mater on the posterior aspect of the cord were scattered small thin bony plates about the sixteenth of an inch in diameter. The brain and cord were set aside for further examination. The pleuræ and each pleural cavity contained a few ounces of turbid serum, and both layers were covered with an exudation of soft recent lymph. The lower lobe of each lung was congested and sparingly crepitant.

Beneath the pelvic fascia on the right side of the pelvis, between it and the innominate bone, was about one ounce of pus; a smaller collection was situated immediately in front of the first piece of the sacrum. The iliac and femoral veins were unobstructed. The liver was pale and fatty. The other organs were all examined, and were found free from disease.

A careful examination of the cerebellum was made by Mr. C. Stewart, the curator of the museum, who has supplied me with a drawing of the microscopical appearances. (Plate II.) The weight of the entire brain was 38 oz., and of the cerebellum 710 grains; the average weight of the brain in the female being 44 oz., and of the cerebellum 2200 grains. The weight of the atrophied cerebellum is consequently less than a third the normal. Its transverse diameter was three inches, the average being about four inches. This would correspond with a reduction of cubic contents from five to three The base of the skull was, without any increase of its thickness, accurately adapted to the under surface of the brain.

The cerebrum appeared of normal consistence, but the cerebellum was extremely hard with the exception of a narrow area in front of each lateral lobe, which, both to the naked eye and under the microscope, appeared normal. The blood-vessels were healthy. A section of the atrophied part showed, on microscopical examination, an almost complete absence of proper nerve substance, with great increase of the neuroglia; also spherical, transparent, and apparently homogeneous bodies which stained deeply with carmine.

March 21*st*, 1871.

Digitized by Google

5. *Venous vascular tumour of cerebrum.*

By H. Morris.

Frederic Heppy, æt. 38, a married man, was admitted into the Middlesex Hospital under Dr. Goodfellow, on April 6th, 1871. His previous personal and family history was briefly this. His mother, a violent-tempered woman, was a drunkard, and separated from his father, of whom he knew but little; his maternal grandfather was a great drunkard; none of his relatives have been in an asylum. He is himself of a very irritable and excitable temper, and has for many years been intemperate. At the age of thirteen or fourteen years he was frightened by a fire-engine, by which he was knocked down, and soon after this, while walking, he was seized with the first fit he ever had. These fits, which, from the description given, were of a true epileptic nature, have occurred during the last thirteen years—*i. e.* since his marriage—regularly every four or five weeks, until this last attack, which was preceded by an interval of freedom of four months' duration.

He generally had premonitory symptoms of their occurrence in severe pain in the head and considerable perspirations. A wild expression of features and inconsistent remarks were observed by his wife as a warning. His wife also states that a meal of pork or veal or excess of drink invariably brought on the fits.

About seven years ago, after the death of a child from convulsions, he drank to great excess, and was insane for two or three months and following afterwards. He often expressed his belief that he should die out of his mind, and on more than one occasion showed homicidal tendencies after drinking. For the last five or six years he has been unable to do much work, has been very morose and excitable, and has had complete sexual incapacity. He for a long time has had a cough, and has occasionally expectorated blood. His present attack occurred four days before admission. He was as well as usual on April 2nd, but during the day he had some disappointment at his work, and then drank hard "to throw it off." During that night he awoke and was violently delirious, and remained so for six hours, when he had one of his old fits, during which his left eye was protruded so far as almost to extend beyond the eyelids. On April 3rd he had five fits, and was unconscious during the intervals. The next day he

Digitized by Google

was better, and remained sensible till the evening, when he again became unconscious, but was free from fits. On the morning of April 5th he was well enough to go to his place of business, but returned soon, and was shortly afterwards seized with the same violent delirium and severe diarrhœa. He was brought to the hospital in an unconscious condition, had a high temperature (103·5°), and the physical signs of bronchitis and pneumonia. He died early on the 7th of April, having been less than twenty-four hours in the ward.

The post-mortem examination.—There was congestion of the veins of the arms and neck, also of the bronchi. In the apex of the right lung there were three cheesy deposits of tuberculous matter, with thick coarse fibrous septa spreading into the lung tissue from the pleura, which was thickened over the upper lobe. There was pneumonia of the lower lobe of the left lung, and some old adhesions binding down each lung to the thoracic walls.

Two small excavated linear ulcers, about four lines in length, with well-defined sharp edges, existed, one on each true local cord. The liver was very fatty, and the mucous membrane of the stomach highly congested.

The arachnoid membrane of the brain was opaque and thickened; the veins of the pia mater and of the lateral ventricles were markedly congested and in places varicose. The left cerebral hemisphere a little to the side of its posterior angle was seen to be adherent to the parietal arachnoid, and a congeries of tortuous veins distended with dark blood bulged outwards from the surface of the brain. These veins took very twisting courses, were closely matted to each other, and here and there some fine areolar tissue intervened between their walls, which were exceedingly thin, and in places dilated into sacculi as large as a small cherry. The whole formed a tumour in which was no brain substance, and which reached nearly to the lower surface of the cerebrum, and upwards nearly to the convex surface. Projecting forwards from this mass of veins into the brain substance between the posterior and descending coruna of the left lateral ventricle was a large ovoid cyst, formed by the distension of the side of one of the veins of the tumour. This was as large as half a walnut on section, and was filled with blood clot of varying ages,—some quite recent, others of an ochre-yellow colour, and deposited in strata like the clot in an aneurism. A curved probe could be passed from the posterior part of this cyst along an infundi-

Digitized by Google

buliform process into a vein. This venous tumour did not reach to the lateral ventricle, nor did it in any way communicate with the choroid plexus.

The brain matter surrounding its front and lateral portions had a yellow, softened appearance, but no evidence of actual softening having taken place was discovered microscopically.

Remarks.—This case, so far as I have been able to ascertain, is unique. A mere varicose state of the veins of the pia mater has been often noticed, and Schröder van der Kolk has considered this condition a frequent one in epileptics.

Virchow opposes this opinion for reasons stated in his work on tumours. He has, however, figured and described two cases of angeioma of the brain, but these were formed of a close network of dilated *capillaries and commencing venules*, which latter were bulged into minute ampullæ, having little or no cerebral substance between them, and producing no alteration in structure in the surrounding brain material. One of these was found at the base of the middle lobe of the brain near the sylvian fissure, the other in the pons Varolii.

What relation existed between the tumour in this case and the intemperance and epilepsy I will not undertake to say; for if their presence was not a mere coincidence it is equally easy to find arguments in favour of the views that the one was a cause or a result of the other. But from our knowledge of these tumours in other parts of the body it is quite probable that this venous nævus existed at or soon after birth, or originated in early life, and was increased by the causes which produced congestion of the other veins of the brain and the pia mater. *April* 18*th*, 1871.

---

6. *Case of paralysis agitans.*

By C. Murchison, M.D., and W. Cayley, M.D.

John J—, æt. 71, was admitted into the Middlesex Hospital on Dec. 13th, 1870, the sixth day of an attack of typhus fever, which proved fatal on the twelfth day. Twelve years before he had begun to suffer from tremulous movements of the right hand, which

Digitized by Google

had gradually extended to the other extremities and the head, and which were much increased by excitement or any attempt at voluntary movement. Latterly his body had been bent forward much in walking. During these twelve years also he had had several attacks of what he called "rheumatic fever," but he had never complained of cardiac symptoms, nor were there any signs of organic disease of the heart. As regards his fatal illness, the typhus eruption was distinct but not copious; the temperature on the day of admission was 103·4° Fahr.; on the eighth day it rose to 104·8° Fahr.; and shortly before death it was 103·5°; on the seventh day the tongue became dry and brown, and in the following night he became very restless and delirious; on the tenth day albumen appeared in the urine, which was very scanty, and he was quite unconscious; and on the same day the whole body was in a state of constant and violent tremulous movement, even the occipito-frontales and orbiculares oculi muscles being involved. From this time also until death there was dysphagia and retention of urine.

On *post-mortem* examination the body presented the appearances usual after death from typhus. The blood was liquid and dark. The spleen was not very large, but its tissue was converted into a semi-fluid pulp. The lungs, liver, and kidneys were congested. The brain was shrunken. The arachnoid was raised above the convolutions by accumulation of fluid beneath. The lateral ventricles were much dilated and full of fluid; but the quantity of fluid in the ventricles and on the surface of the brain was not greater than is common after death from typhus in a person of advanced age.

It is not often that opportunities are offered for determining the nervous lesions of paralysis agitans, as patients rarely die of this disease in hospitals. Portions of the brain, medulla oblongata, and spinal cord were accordingly preserved in chromic acid, and have now been examined by Dr. Cayley, whose report is appended. The morbid appearances correspond with those which, according to Dr. Sanders, in his article on "Paralysis Agitans" in 'Reynolds' System of Medicine' (vol. ii, p. 199), have already been described by Bamberger, Skoda, Oppolzer, Lebert, &c.

May 2nd, 1871. C. MURCHISON.

Report by Dr. Cayley on Dr. Murchison's case of paralysis agitans.—No marked alteration was observed on inspection of the cord in the recent state without the aid of the microscope. On microscopical

Digitized by Google

examination of thin sections, after hardening in chromic acid and staining with carmine, the following changes were noticed:

1st. The cortical or connective tissue layer of the cord appeared thickened, and was more thickly studded with nuclei than in health, these often occurring in little groups. This alteration of the normal character of the cortical layer was observed chiefly in the cervical and dorsal regions, and was more marked on the posterior than the anterior aspect of the cord.

2ndly. Passing from the cortical layer into the substance of the cord were irregular tracts and patches of connective tissue thickly nucleated, which, like the altered cortical layer, took a deep, diffused red colour from the carmine. The reticulum of the cord, especially in the neighbourhood of these patches, was much thickened. These patches, which were very irregular in their distribution, occurred only in the dorsal and cervical regions, and were most frequently met with near the exit of the posterior roots of the nerve, generally a little external to them. The posterior roots of the nerves themselves did not appear altered.

3rdly. The central canal of the cord throughout its whole length was completely transformed. In its site was an oval tract, very much larger than the normal canal, crowded with cells of various sizes and shapes, the majority having the characters of leucocytes, others of an oval or elongated form, but none presenting the characters of the normal epithelium of the central canal. This tract occupied not only the site of the central canal itself, but also that of the surrounding central substantia gelatinosa.

4thly. The capillary vessels of the gray matter of the cord, and to a less extent those of the white matter, were distended with blood, and in some cases contained aggregations of white blood-globules, apparently forming plugs; here and there small points of extravasation were visible.

5thly. Scattered through the whole length of the cord, chiefly in the gray matter, were small deposits composed of leucocytes or exudation cells; these were met equally in the cervical, dorsal, and lumbar regions.

In this cord there appear to be two kinds of morbid change—first, a chronic one, causing thickening of the cortical layer and reticulum, with the formation of patches of connective tissue induration; and secondly, an acute process, giving rise to the capillary congestion, and extravasation, and scattered patches of exudation. The latter

Digitized by Google

Digitized by Google

DESCRIPTION OF PLATE III.

(*From drawings by* H. ARNOTT.)

Figs. 1 and 2 illustrate Dr. Murchison's case of Paralysis agitans (page 24).

Fig. 1 represents a section of spinal cord in paralysis agitans (dorsal region).

a. Cortical layer.

b. Patch of nucleated connective tissue passing into white substance, stained with carmine.

Fig. 2 represents a section of spinal cord in paralysis agitans (cervical region).

a. Gray matter at base of anterior horn.

b. Patch of exudation cells, stained with carmine.

c. White matter of anterior column.

d. A vessel filled with blood.

Fig. 3 illustrates Mr. H. Arnott's case of Epithelioma of the Lung (page 231).

Fig. 3 represents a section of epithelioma in lung from edge of a nodule of disease secondary to epithelioma of clitoris.

a. Remains of lung tissue.

Fig. 4 illustrates Mr. H. Arnott's case of Soft Cancer of the Female Breast (page 264).

Fig. 4 represents a section of a soft cancer of the breast, moderately soft portion hardened in chromic acid and stained.

Digitized by Google

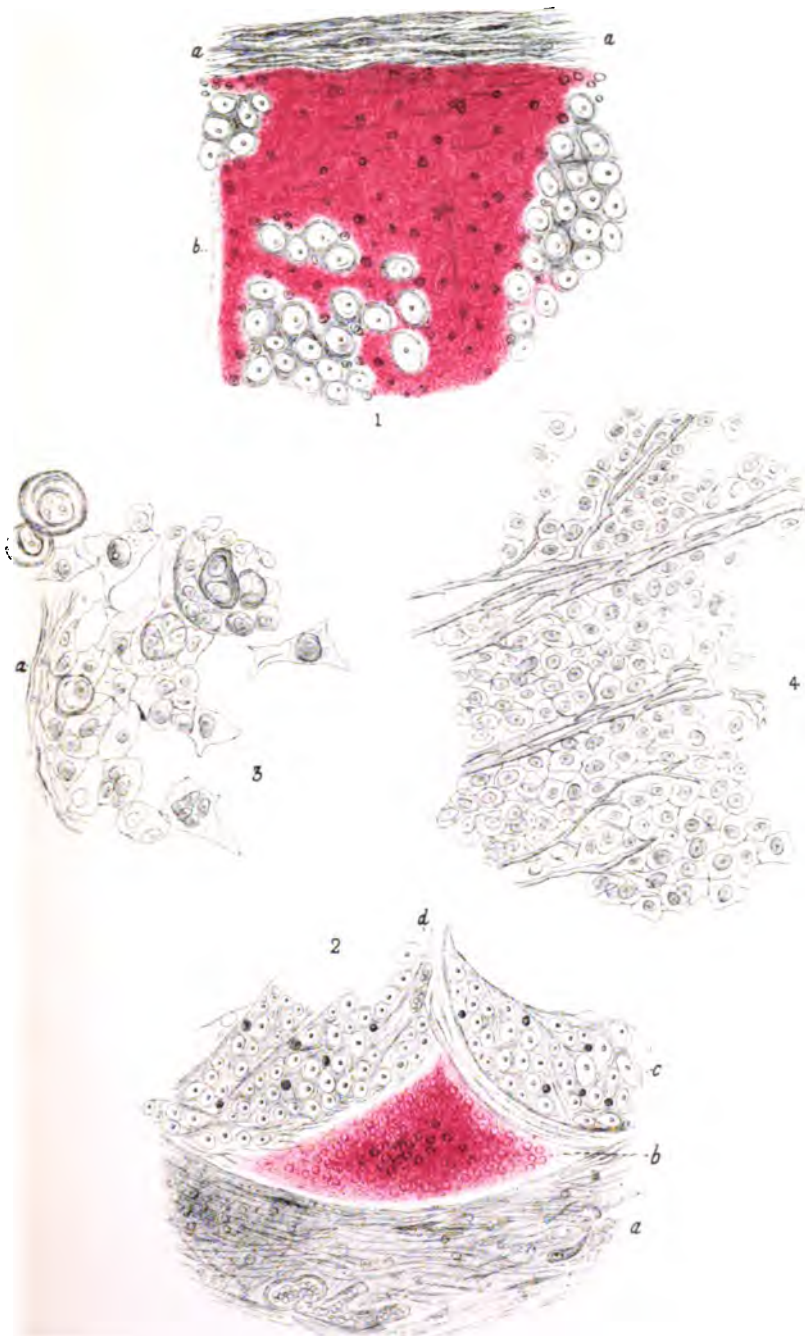

Digitized by Google

Digitized by Google

process was probably contemporaneous with the attack of typhus and consequent exacerbation of the symptoms of the paralysis agitans.

The accompanying drawings were kindly made for me by my friend Mr. Arnott. (Plate III.)

May 1st, 1871. W. CAYLEY.

---

7. *On the changes of the spinal cord in tetanus.*

By T. CLIFFORD-ALLBUTT, M.D.

THE following researches were undertaken in consequence of a conversation with Dr. Dickinson, when he showed to me a section[1] of a spinal cord taken from a case of tetanus, in which a hæmorrhage was found. Since my own sections were made I have also been referred to a communication on the same subject by Dr. Lockhart Clarke in the Transactions of the Medical and Chirurgical Society, vol. xlviii. The cases from which the cords were taken which were submitted to me for examination were as follows:

CASE 1.—Thomas Wade, æt. 22, was admitted under Mr. Teale in the Leeds Infirmary, on December 29th, 1869. There was a severe laceration of the skin and tissues about the right ankle.

January 7th, 1870.—"Sore throat" and stiff neck at 5 p.m. (same day) rigidity of jaws.

8th.—Tonic spasm; opisthotonos.

9th.—Much opisthotonos; difficulty of swallowing. Died 4.30 p.m.

The post-mortem was made twenty-two hours after death, and the cord was placed, as soon as removed, in spirit. It seemed soft in many parts, and in the upper dorsal region was with difficulty removed whole. Two days later it was removed to chromic solution, where it remained for sixteen days. It was then placed in bichromate of potash solution until sections were made in May, 1870.

[1] The sections here alluded to were brought before the Society in connection with Dr. Allbutt's communication. They are not described in this volume, as the morbid appearances they displayed are detailed in a paper in the 'Medico-Chirurgical Transactions' for 1868. The more striking changes were great vascular distention, extravasation of blood, exudation of translucent material, and erosion of the nervous tissue in the course of the arteries. These alterations affected the cord equally in its whole length.—W. H. DICKINSON.

Digitized by Google

The posterior tibial nerve was also investigated and removed up to the ham. Suppuration was found in the sheath of the nerve up to this point. It was also preserved with the cord.

CASE 2.— Hunt, æt. 13, admitted under Mr. Nunneley, May 8th, 1870, with lacerated forefinger of right hand. Amputation had on a former occasion been declined by the parents, and the finger was now gangrenous. Some symptoms of tetanus were present on admission; these became worse until her death, on May 12th. Treatment by amputation of finger and chloral. The post-mortem was made within a day of death and the cord was handed to me in spirit on the day following. On the third day it was transferred to chromic acid, and thence, as before, to bichromate of potash in about a fortnight. Sections were made in July, 1870, and the slides were labelled "Nunneley, 1."

CASE 3.—James Buck was admitted into the Leeds Infirmary, under Mr. Nunneley, April 16th, 1870. Chopart's operation on the foot was performed on May 13th. Symptoms of tetanus appeared on May 23rd. Treatment by chloral ʒss secundis horis. Death May 29th. Spinal cord handed to me in spirit as before.

This cord I saw removed eighteen hours after death. The fifth lower dorsal and lumbar portions were soft and with difficulty removed whole. In the upper part of the lumbar enlargement was an evident hæmorrhage about the size of a sixpence on the surface. The cord was hardened and cut as the others. Sections were made and labelled "Nunneley, No. 2," on September 19th, 20th, 1870. The posterior tibial nerve was also investigated. The sheath contained pus in about two thirds of its tibial length, which was as high as we ventured to examine. The nerve was hardened and sliced with the cord.

CASE 4.—John Smith, æt. 47, was admitted April 16th, 1870, under Mr. Wheelhouse, with compound fracture of leg and laceration of hand. Previous to the accident he had had good health. A finger was removed and the leg put in a swing and treated with carbolic acid.

April 20th.—Lower jaw and diaphragm first became spasmodic. A grain of opium was given every two hours, and a calomel and colocynth purge.

Digitized by Google

22nd.—Bromide of potassium was added, fifteen grains every four hours.

24th.—Died.

I saw the cord removed about twelve hours after death. It was soft, chiefly in the dorsal region. There were also numerous submeningeal hæmorrhages, one of some extent in the neighbourhood of the lumbar enlargement. The cord was prepared in the same way and was sliced on September 26th, 1870.

The result of the examination of these four cords may be summarised as follows:

1. Diminution of consistence of various degrees and situation.

2. Hæmorrhages in two of them, visible to the naked eye.

3. On microscopic examination the vessels in all cases showed marks of severe congestion, the larger vessels being full and distended, and a number of very fine vessels springing up into full view. The walls of the larger vessels in some places were evidently thickened.

4. Exudation had taken place through the vessels into the surrounding tissues, so that in many places they are visibly surrounded by granular exudative products, in other places by large empty spaces, or spaces with some remnant of exudation, and in other places large gaps were seen from which the vessel itself had disappeared, probably during the process of mounting. These spaces were often large enough to be seen by the naked eye on holding the slide to the light.

5. In two of the cords large and small hæmorrhages had occurred into their substance.

6. The epithelium of the central canal was in all cases greatly proliferated, and was often seen in course of liquefaction or breaking down.

7. Striking changes were seen in all cases in the gray matter, and more especially in that of the anterior horns. The caudate cells seemed in the first place to become rather large and very distinct, this distinctness being apparently due to some detachment from the surrounding tissue. In some cases the cells were so hardened that they were very easily turned out by the razor and lay about on the field beautifully demonstrated with their tails. In other slides they might be seen still *in situ*, but perfectly detached and surrounded by a thin line of transparent space. At a subsequent stage these cells had disappeared, often completely or in very large numbers, so

Digitized by Google

that the horns had collapsed. In some places the horn preserved its size or nearly so, but presented only a granular appearance without cells, the granular matter probably consisting of their débris. In one case the process of destruction was admirably shown, namely, in the case under Mr. Wheelhouse. In the anterior horns cells were seen undergoing a yellow degeneration, perhaps of a fatty kind. A yellow point was visible in the centre of some of the tailed cells, which in others had invaded more of their space, and in others had filled the whole cavity, so that the cell-wall could just be detected around the degenerated contents. It seems probable that the cell then burst, leaving granular débris behind it, which, again, in its turn disappears and the horn thus collapses. I venture to attach considerable importance to these changes, which are not described by Dr. Lockhart Clarke. They were less visible in the posterior horns, where distortions and spaces seemed rather to be secondary to vascular disorder.

8. In all cords were patches of the "granular disintegration" of Clarke, spaces of considerable size being found in many places with borders of decomposing nerve tissue. These occurred chiefly, as in Clarke's cases, in the commissure, but were visible in other parts also. (In a fifth cord, from a case of tetanus, examined since, a space of this kind ran through the whole cervical enlargement, and was at its largest diameter quite visible to the naked eye.)

9. The only negative observation I think worth special record is that I failed to make out any definite relation between the parts of most serious mischief in the cord and the part wounded. In the cases of wounded legs the cervical enlargement was as much disturbed as the lumbar. But the duration of the symptoms before death certainly seems to be in direct relation with the amount of visible mischief.

10. On turning to the nerves examined I have little or nothing to add to the naked-eye appearances. Under the microscope the nerves were thickened and their blood-vessels thickened and congested. There was no great quantity of interstitial proliferation in the inner sheaths, the pyoid matters seeming to have their origin almost entirely in the outer. This is true also of the fifth case before referred to, in which tetanus followed an injury to the foot, and in which semipurulent inflammation was again found in the sheath of the posterior tibial nerve.

In conclusion, I would venture very strongly to urge neurotomy

Digitized by Google

as a remedial process in tetanus. In the three cases in which I have had the examination made, the nerve trunk supplying the injured part was found to be bathed in inflammatory products, and I attribute the rapid destruction of the central gray matter of the cords to the influence of the irritation acting through the nerve trunk. As the central mischief increases rapidly day by day, it is of the first importance that this or any other remedial means should be made use of at the earliest possible opportunity. *Feb. 7th*, 1871.

Report of Committee upon the sections of spinal cord from tetanic patients exhibited by Dr. Allbutt.—The sections of spinal cord submitted to us for examination present the following morbid appearances:

1. Great distension of the blood-vessels in both white and gray matter, with occasional exudation and disintegration of tissue around them.

2. Isolated patches of disintegration of various shapes and sizes in both gray and white matter. Besides these there are, in the white matter, numerous vacuities which in transverse section have circular or oval outlines. These spaces, which are not mentioned in the preceding description, are such as result from disintegration of the nerve-fibres.[1]

3. The sections belonging to one case displayed a peculiar disintegration with yellow pigmental degeneration[2] of some of the nerve-cells, and atrophy of the processes, which in some instances were shrunk, and in others had almost disappeared, giving to the cells the appearance of more or less globular bags of yellow granular matter, which retained its colour unaffected by the solution of carmine in which the sections had been soaked. We are of opinion that this change is one of a chronic nature, unconnected with the tetanic condition and accidentally associated with it in the present instance.

4. The apparent excess of epithelium in the central canal is a condition so commonly found that we do not attach any pathological importance to it.

J. LOCKHART CLARKE.
W. HOWSHIP DICKINSON.

July, 1871.

[1] These appearances, with proliferation of connective tissue, were described by Dr. Lockhart Clarke as affecting the spinal cord in a case of paralysis. 'Brit. and For. Med.-Chir. Rev.,' April, 1860.

[2] This change in the nerve-cells was first described by Dr. Lockhart Clarke in connection with different forms of paralysis, in Beale's 'Archives' for 1863, No. xiii.

Digitized by Google

The author ventures to remark upon the empty spaces that these were not overlooked by him, but are regarded by him as spaces formed by vascular distension and perivascular degeneration, the vessel having then been detached from its loose bed in making the section. It occurred to him that these might be the vascular erosions such as have been described by Clarke and Dickinson in other cases, but his subsequent and his present opinions are rather in favour of the former position. He has likewise seen, frequently, the overgrowth of epithelium in cords suffering from congestion or chronic inflammation, but not in those which are healthy.

Aug. 1*st*, 1871. T. C. A.

We are of opinion that the vacuoles referred to are wholly different in their nature and origin from those, also found in this case, which have been described by Dr. Clarke and Dr. Dickinson as arising in connection with blood-vessels. The cavities we allude to were like punctures in the substance of the white matter; they had no connection with the presence or with the possible removal of blood-vessels; each cavity was nearly the size and shape of a single nerve-fibre, and resulted, as we conclude, from its disintegration and disappearance.

J. L. C.
W. H. D.

Aug. 4*th*, 1871.

Digitized by Google

II.—DISEASES, ETC., OF THE ORGANS OF RESPIRATION.

1. *Constriction of the trachea; syphilitic deposits in the liver and kidney.*

By Morell Mackenzie, M.D.

The specimens were removed from the body of a man, æt. 39, who was admitted into the Hospital for Diseases of the Throat, November 10th, 1870, suffering from extreme dyspnœa. The patient was considerably emaciated, and of anxious appearance. He denied ever having had syphilis, but there was a large suspicious scar on one cheek-bone (attributed by him to an accidental blow), and there were several small nodes on both shin-bones. He stated that he had enjoyed perfectly good health until a few weeks previously, when, after running quickly up a long flight of stairs, a sudden attack of shortness of breath came on, and for some hours he feared he would have been suffocated. His voice was good, and, on making a laryngoscopic examination, his larynx was found to be healthy. On examining the chest the respiratory murmur was found to be universally very feeble; there were scattered bronchial râles, and there was dulness at the lower front part of the right side of the chest. The prominent symptom was dyspnœa of a very severe and paroxysmal character. Several times the patient was for many hours quite unconscious, pulseless, and with scarcely perceptible respiration. On one occasion he remained in this state for two days. Between the attacks the patient was well, and even gained flesh. At the beginning of December he apparently began to make a recovery; he was able to walk about the ward, and seemed quite comfortable. He remained a fortnight without an attack, but on the 15th of December dyspnœa again came on, and symptoms of bronchitis and pleurisy showed themselves, and he died on the 28th of December.

Digitized by Google

Post-mortem appearances.—Heart.—Left ventricle moderately contracted; valves, orifices, and muscle healthy. A little spot of atheroma on aortic segment of mitral valve.

Pleuræ.—There are old adhesions at the apices of both lungs, and recent lymph at both bases, especially at the parts where the lung beneath is consolidated. This lymph can be scraped off with care.

Lungs, emphysematous, especially at margins and bases. They are much congested, and on pressing the cut surface pus exudes from the minute bronchial tubes. At both bases, but more markedly at the right, the lung-substance is consolidated, is red, soft, granular, and sinks in water. In fact, there is lobular pneumonia in the stage of red hepatization.

Bronchial tubes.—The mucous membrane everywhere congested and granular. On opening up the tubes the terminal ones are seen to contain semi-solid pus.

Larynx.—Healthy.

Trachea.—At the point where the trachea is crossed by the innominate artery, its calibre is so reduced that it will only admit an ordinary sized goose-quill. This constriction is caused by a puckered cicatrix situated on the anterior and right side of the trachea. There is no thickening around the windpipe, nor is there anything external to it to account for this condition. It seems to have been caused by some ulceration of the trachea which has undergone cicatrization. The innominate artery itself is healthy, and so are both recurrent laryngeal nerves.

Liver.—Scattered over its convex surface are masses of yellow material, varying in size from a large chestnut to a pea. Some of these masses are situated below the surface in puckers; others are parallel with it. On the under surface of the liver similar masses are seen, but of smaller size. There are none of these about the vena porta, but on tracing the portal vein into the liver substance masses are come upon here and there in the course of the vessel. These masses are of a yellow colour, of firm consistence, cutting and looking like wash-leather. Under the microscope the material is seen to consist of granular cells and granular matter. Nowhere is anything seen of a cancerous nature. These masses yield no juice when scraped. There can be no doubt that they are syphilitic deposits. Peritoneal covering of liver cloudy in parts, as if there was a little commencing peritonitis.

Kidneys.—The right kidney contains a yellow circumscribed de-

Digitized by Google

posit, similar in nature to what is seen in the liver, of about the size of a pea. The capsules are very adherent, but they are otherwise healthy.

Brain.—Brain substance and vessels healthy to the naked eye.

Spleen.—Not examined.

In addition to the pathological interest of this case, it is remarkable in a clinical point of view, from the extreme paroxysmal character and sudden development of dyspnœa, dependent on organic changes very gradually brought about. *February* 21, 1871.

---

2. *Case of diphtheria, with extension of the membrane to the bronchial tubes.*

By C. Murchison, M.D.

William M—, æt. 24, was admitted into the Middlesex Hospital on March 31st, 1871. One month before, without any known exposure to contagion, he began to suffer from cough, huskiness of the voice, and a raw feeling in the throat. He went about, however, till March 28th, when these symptoms became aggravated, and on March 29th he lost his voice, and had pain and difficulty in swallowing, with severe paroxysms of difficult and noisy laryngeal breathing.

On reaching the hospital these symptoms continued; the patient was unable to speak except in a whisper, and had frequent attacks of noisy, stridulous breathing. Pressure over the larynx caused pain, and brought on a fit of dyspnœa. Both tonsils were swollen and red, and plastered over with soft white material. The cervical glands were not enlarged. Lung signs healthy. Pulse 88; temperature 101° Fahr. Considerable pallor of face, but no albumen in the urine. The treatment consisted mainly in steam-inhalations, and chlorate of potash with perchloride of iron.

On April 2nd and 3rd the patient coughed up large masses of thick false membrane like wash-leather, evidently from the larynx. The tonsils at the same time became clean, and there was an im-

Digitized by Google

provement in the laryngeal symptoms. But on April 6th the patient was worse. The respiration was permanently quickened; bronchial râles were heard all over both lungs; the sputum was slightly rusty. Fresh patches of white material had formed on both tonsils. Pulse 108; temperature 102·2°. On April 7th these symptoms were aggravated; the signs of laryngeal obstruction were still decided; there was considerable lividity of the face, with retraction of the soft parts of the chest during inspiration, and strong expiratory efforts of the abdominal muscles. To-day for the first time the urine contained albumen—about one third of its volume after boiling. At 10 p.m. the breathing became suddenly worse, and the patient seemed to be in immediate danger of sudden death from asphyxia. Tracheotomy was performed, and at once the symptoms were relieved. The patient had a good night, breathing easily and freely through the tube; but at 7 a.m. of April 8th the dyspnœa and lividity of the face returned. This change in the symptoms was not due to any obstruction in the tracheotomy tube. The breathing became rapidly worse, and at 8.45 a.m. the patient died asphyxiated.

After death, the larynx, trachea and bronchi, down to their fine ramifications, were lined with a thick false membrane, forming a perfect cast of these tubes, but easily detached from the subjacent membrane, which was intensely injected. There was no trace of membrane on the tonsils, fauces, or upper surface of the epiglottis, but the under surface was coated with a thick layer, which terminated abruptly at its margin. Below the wound a large fragment of membrane hung loose into the interior of the trachea. The pleural surface of both lungs was plastered with flakes of recent lymph, and in both lungs were several large patches of lobular pneumonia in an early stage. The anterior portion of the lungs was pale and emphysematous. Both lungs were large, smooth, and intensely congested, dripping with blood on section.

The false membrane was everywhere made up of modified epithelial cells, and contained no fibrillated tissue.

Although when the patient was first seen there were a few small white patches on the tonsils, yet the absence of albuminuria and the fact that the severe laryngeal symptoms were preceded for nearly a month by sore throat and huskiness of the voice made the diagnosis of diphtheria doubtful until the masses of false membrane were coughed up. The microscopic appearances of the false membrane agreed with those recently given by Messrs. Cornil and Ranvier, and

Digitized by Google

other pathologists, in consisting of altered epithelium-cells without any fibrillated structure. Ten years ago similar observations respecting the structure of the diphtheritic membrane were communicated to this Society ('Trans.,' Vol. XII, p. 241). *April 18th*, 1871.

---

3. *Aneurism of a branch of the pulmonary artery in a phthisical lung.*

By T. Henry Green, M.D.

The specimen was taken from the body of a patient, Mary Ann E—, æt. 18, who was in Charing Cross Hospital, under the care of Dr. Headland. She had suffered from cough, expectoration, and shortness of breath, for about nine months, and was admitted into the hospital October 19th, 1870, in consequence of an attack of profuse hæmoptysis, which she stated had occurred for the first time three weeks previously.

On admission she presented the physical signs of consolidation and excavation of the upper part of the left lung. The hæmoptysis continued at intervals in large quantities for four days, and on the 24th inst. she died during an attack, a large coagulum having been removed from her larynx and trachea a short time before her death.

At the *post-mortem* examination the upper half of the left lung was found to be firmly adherent to the parietes, and to be occupied by a large irregular cavity, which was traversed by numerous vessels. Immediately below this, and near the posterior border of the lung above its root, was another cavity about the size of a small walnut, with smooth fibrous walls, within which, and almost completely filling its cavity, was an aneurism, in size and colour closely resembling a morella cherry. This was situated on a branch of the pulmonary artery, about one twelfth of an inch in diameter: its parietes were thin, and had ruptured near its base. A bronchus, the size of a small crow-quill, was traceable into the cavity. The base of the lung and the apex of the right lung, contained a few scattered grey

Digitized by Google

and cheesy nodules of consolidation. The other organs were comparatively healthy. There was no ulceration of the intestines.

November 1st, 1870.

---

4. *Peculiar pneumonia in a syphilitic subject.*

By Walter Moxon, M.D.

The subject whose lung was exhibited came to an untimely end through fracture of the cervical spine. This was caused by one sack of grain falling on him as he was carrying another in the act of unloading a ship. It was not to be learnt from his companions that he had been complaining so as to impress their memories. It is certainly remarkable that in the presence of such grave cachectic disease and acute inflammation combined the man could have been able to endure the exertion of carrying such weight as he did. He lived only a few hours after the accident, with total paralysis of the trunk and limbs, and died of respiratory paralysis.

At the *post-mortem* examination the body was observed to be well formed and fairly nourished. Hair and beard dark and plentiful; no sores or scars; the fourth cervical vertebra was fractured, and the spinal cord crushed through at the corresponding spot, so that its columns were all divided. So much for the accidental cause of death, but on inspecting the chest remarkable disease was found in the left pleura; the lower half of the membrane was thickened much and coated with recent firm lymph of subacute pleurisy; its surface roughened with transverse lines from friction. There were some old strands of ancient adhesion, and in these was recent yellowish lymph; these conditions decreased from below upwards. The left lung, under and corresponding to the disease of the pleura, showed a state of grey fibroid change with diminution of bulk and hardening and darkening of the tissue. This state affected nearly all the lower lobe and extended in disregard of the lobar fissure across into the upper lobe, spreading therein with an irregular border, whose outline was made mostly of convex projections, these

Digitized by Google

forming masses of more recent disease, which showed tendency to break down in the middle at half an inch depth from the surface in at least two instances, though they passed indefinitely into the main disease below. They represented a more recent formation of the same kind. The lower lobe showed on section that a thick mass of fibre in the pleura appeared to have by contraction puckered the lung up around it, so that this mass of fibre was imbedded in the surface of the lung rather deeply; but yet the lung itself was very fibrous and at parts graduated into this pleural mass, so that one could not say whether part of it was not really fibrous-changed lung. There were two distinct masses or thick plates of this fibre, one on the back and one on lower surface of lower lobe; the lung's pleura was only connected by bands here with the parietes. The hardened lung showed fibrous tissue chiefly as a great increase of the inter-lobular septa and of the tissue round the vessels and tubes, but beside the presence of this fibre there was much wasting of the air-cell tissue; this was, however, in various conditions. Sometimes the lobules were reduced to small relics, whose texture was coarser though closer than natural; in other parts the appearance was just like section of common sponge, rather open, so that the state resembled ordinary emphysema, but with reduction of the whole bulk rather than expansion, and also more coarse and thick than emphysematous lung. In yet other parts some larger spaces, not differing in appearance from the distended air-vesicles just described, were plainly continuous with the bronchia of whose small branches they were expansions. The larger bronchial tubes were unnaturally contracted.

The right pleura showed large patches of thickening on its lower half, with some adhesion near the spine. Under some points, thicker than the rest, the tissue of the lung showed an early degree of the same change as that in the other lung, there being some widening of air-vesicles and of small bronchia in isolated parts, surrounded by healthy substance. A single small, dilated bronchial tube, surrounded by some dilated air-vesicles, would run up to these spots on the surface and appear to terminate in them.

The vocal cords were thick, as though from coughing. The heart was natural. The liver was very large, weighing 105 oz., marked by cicatricial patches like those on the lung; the tissue was highly lardaceous. The spleen weighed 10 oz., and, as well as the supra-renal capsules, was very lardaceous. The kidneys weighed

Digitized by Google

16 oz. The pyramids were pale and very lardaceous. Both testes showed excellent specimens of syphilitic fibrous orchitis.

As suggesting a syphilitic nature in this lung disease, there is, first, the peculiarity of its distribution in the lung, especially the curved outline that it had, advancing convex into the undiseased part; and second, its association with syphilitic changes in other parts of the body. As to the diseased tissue itself, it would correspond very well with ordinary grey induration of advanced stage; it was close, hard, and iron-grey in colour, through an excess of fibrous substance present, developing at the expense of the air-vesicles. The pleura over the affected part was thick, but not adherent, and it was covered with rough lymph of firm consistence. The non-adhesion may be taken as proving a low degree of intensity, seeing that there was no fluid to keep the surfaces apart and so prevent union, while the action had evidently been of long duration. Such low intensity in some degree explains the freedom from symptoms commensurate with the extent of disease.

As to the general question of the effect of syphilis on the lung, the following, I think, may be regarded as true:—1st. There are a few well-authenticated instances of syphilitic gumma occurring in the lung, but these are always small and as to their effect insignificant. 2nd. That a chronic white hepatization, with more or less induration, spreading usually from above downwards, occurs in the lung of syphilitics. This condition is frequent in congenital syphilis; its occurrence in adults I endeavoured to show in a paper in 'Guy's Hospital Reports' for 1867. This white hepatization is liable to attacks of circumscribed gangrene, producing cavities which give to the organ much of the appearance of ordinary phthisis. 3rd. It is believed that syphilis exerts a qualifying influence on phthisis, causing the phthisis to become fibroid, or, as some would say, syphilis is a cause of fibroid phthisis. Personally, I have had no experience to prove this. I have repeatedly seen phthisis in syphilitic bodies presenting its ordinary tubercular character.

The present specimen does not correspond to either of these conditions; although it might bear the title of fibroid disease of the lung, yet it cannot justly be called phthisis, if, in so doing, it is intended to express a generic relation to common phthisis, to which it has no resemblance. No tubercles or caseous pneumonia were present, and the disease extended from below upwards continuously, and not in discrete patches. So that this case cannot support the

Digitized by Google

statement that syphilis causes fibroid phthisis. Of course the association of this pneumonia with other syphilitic conditions may have been a mere coincidence, but its peculiarities, and especially the eruption-like mode of spread in the lung, call for some explanation. The remarkable absence of symptoms, too, suggests inquiry, and argues some specific cause restraining the inflammation within low and peculiar limits.

These circumstances, in the presence of such marked general syphilis, will, I think, tend to induce the belief that the pleurisy and pneumonia were syphilitic, and I have several times seen patches upon the pleura, in syphilitic bodies, like those in the present case.

February 21, 1871.

---

5. *Some cases illustrating the pathology of fatal hæmoptysis in advanced Phthisis.*

By R. Douglas Powell, M.D.

Fatal hæmoptysis has attracted the attention of physicians from very early times, and some attempts appear to have been made, not wholly without success, to discover the real source of the hæmorrhage, but the observations were scattered and fragmentary; and Laennec (1827), in asserting that in moderate hæmoptysis the blood proceeded by simple exhalation from the bronchial mucous membrane, and that in severe hæmoptysis it was effused into the vesicular structure of the lungs, also stated that, though it was not impossible an aneurism of one of the branches of the pulmonary artery or a varix of the veins might by rupture give rise to hæmorrhage, yet *no well-described instance of the kind had come to his knowledge.* Rokitansky,[1] on the other hand, remarks on the frequency with which the larger branches of the pulmonary artery remain patent in the walls of cavities, not seldom causing fatal hæmorrhage by rupture subsequently to the formation of an aneurismal dilatation, or to the softening of their walls by participation in the inflammary changes around them. MM. Herard and Cornil[2] maintain, however, that hæmorrhage cannot

[1] 'Handbook of Path. Anatomy,' vol. iv, 1852, Sydenham Society's Transl., p. 117.
[2] 'De la Phthisie Pulmonaire,' Paris, 1867, p. 338.

Digitized by Google

take place from the walls of old cavities, because the dense connective tissue of which they are composed opposes the rupture of their vessels, which latter are indeed, they state, obliterated. They thus agree with many earlier observers (Baillie, Meckel, Laennec, Guillot[1]), the latter of whose observations on the obliteration of the vessels traversing the walls of cavities they have repeatedly verified. Dr. Carl Bürger[2] is of opinion that, in the majority of cases of hæmoptysis, both in people with sound lungs and in cases of advanced phthisis, whether copious or in small quantity, the source of hæmorrhage is the capillaries of the bronchial tubes. He admits, indeed, the erosion or rupture of a larger vessel in the wall of a cavity to be the source in certain rare cases, but even in these cases he regards the hæmorrhage as proceeding from large branches of the bronchial arteries or pulmonary veins, scarcely ever from a branch of the Pulmonary Artery. He includes in his paper, however, an example of the latter, which he quotes from Niemeyer. Two cases of fatal hæmoptysis from rupture of aneurisms of branches of the Pulmonary Artery, which occurred at the Brompton Hospital and were published by Dr. Cotton[3] and Dr. Quain[4] in 1866, recently attracted special attention to the subject, and pointed to the probability of such aneurisms being more commonly the cause of fatal hæmoptysis than was generally supposed, and two or three cases have been subsequently published in the 'Pathological Transactions' and medical journals which tend to confirm this view. One of these cases, the specimen of which was exhibited by Mr. Heath to this Society in 1868, had been described by Dr. Fearn in the 'Lancet' in 1841.

The only connected paper on this subject with which I am acquainted has been contributed by a Danish physician, Dr. Rasmussen, and translated by Dr. Moore in the 'Edinburgh Medical Journal' for 1868–9, vol. xiv, to which I shall again have occasion to refer.

The most recent writer who refers to this subject, Dr. Peacock, in a paper on the varieties of Phthisis contributed to the 'St. Thomas's Hospital Reports' for the present year, considers important hæmorrhage as very rarely proceeding from the walls of old cavities, for the same reason as that stated by MM. Herard and Cornil, and others, viz.

[1] 'Descriptions des Vaisseaux,' &c., in L'Expérience,' i, 1, 1838.

[2] 'Ueber das Verhaltniss der Bronchial und Lungen blutungen fur Lungenschwindsucht.' Tubingen, 1864.

[3] 'Med. Times and Gazette,' January, 1866.

[4] 'Path. Trans.,' vol. xvii.

Digitized by Google

because these vessels are obliterated. Dr. Peacock looks upon hæmoptysis from rupture of an aneurismal dilatation of a pulmonary arterial branch, an example of which he published in 1843, as ocur. ring generally in the early stage of phthisis, when the tubercular consolidations are commencing to soften.

It is difficult to understand how the fact though so distinctly affirmed by Rokitansky, should still have been overlooked or denied by more modern observers, that a considerable number of the large vessels traversing the walls and trabeculæ of cavities in the lung remain patent; a number, it is true, greater in some cases than in others, varying, indeed, according to the course which the disease has taken, the rapidity with which the cavity has been formed, and its subsequent quiescence[1] or activity. In some cases almost every trabecula contains a patent vessel; in others they are difficult to find.

The three following cases and those contained in the table which I append to this paper will serve as a basis for the further more special remarks which I have to make.

I will add some comments special to each case, and will, in conclusion, make such observations as the cases, taken together with those in the table, seem to suggest.

Case 1.—Wm. H—, æt. 25, baker, admitted into the Brompton Hospital under my care, in Dr. Cotton's absence, September 6th, 1870. This man had come under my notice as an out-patient in June, 1870, when he stated that he had been well until the preceding Christmas, but since then had gradually failed in health with cough, emaciation, &c. *His fingers were noticed to be clubbed.* He had had

[1] It is, perhaps, well to mention that by the term *quiescence*, as applied to the walls of cavities, is here meant that condition of dryness, smoothness, and comparative avascularity, commonly seen in cavities which are old, circumscribed, and non-extending; while the term *activity* refers, not so much to the extension of a cavity by the breaking down of fresh pneumonic consolidations into it, as to that condition of active ulceration and erosion which is apt to take place in cavities shut off by fibrous induration from the surrounding parts. Such cavities have often been long *quiescent* when their walls become attacked by the ulcerative process, attended with profuse and exhausting purulent discharge, the occasional formation of gangrenous sloughs, or of fistulous canals, which may open into the pleural cavity or through the thoracic wall. This process, which belongs to the class of ulcerations, not of parenchymatous inflammations, causes extensive exposure of vessels.

Digitized by Google

partial aphonia since February 20th. On admission the cough was severe; shortness of breath considerable; expectoration copious, muco-purulent; pulse 100. He suffered from diarrhœa soon after admission. Some albumen was present in the urine.

On September 23rd, up to which date he had never had hæmoptysis, he expectorated at 5 p.m. about half a pint of blood, and again at 11 p.m. six ounces. On the 25th, at 7.30, he expectorated in gushes one pint of bright red blood (so described by Mr. Bartlett, clinical assistant), after which he had orthopnœa and faintness, with cold extremities. He gradually sank, and died on the 26th, at 9 p.m., of exhaustion, without any fresh attack of hæmoptysis.

At the autopsy, thirty hours after death, the heart was natural; no valvular disease or hypertrophy of its walls. Both lungs were large and heavy; some adhesions on the right side. The *right lung*—pleura not generally thickened, but at several places varying in size from that of a florin to a crown piece, most of which were over the lower lobe, it was slightly thickened by flaky fibrous laminæ, which marked the position of old adhesions, and beneath these the lung was felt to be excavated. On section the lung was found to be, for the most part, made up of mingled emphysema and consolidations, the latter, however, being in excess and consisting of patches of granular pneumonic tissue in all stages of degeneration, and showing no definite gradation in age on passing from apex to base. Some old cheesy nodules are scattered here and there; several of them were found in the middle lobe. At the apex there was a moderate-sized cavity, and at the base of the lower lobe one of about the size of an orange. These cavities were sharply defined, smooth-walled, and but slightly trabeculated; no trabecula passing across them. The lower cavity contained a large clot, completely filling it, and attached by a pedicle to its upper angle, where, partially nestling in a cup-shaped depression, a thin-walled aneurism of the size of a small walnut was discovered, which arose from one of the secondary branches of the Pulmonary Artery and had ruptured at the point most remote from the artery, the opening being large enough to admit the bulbous end of a large probe, and having attached to it the clot which filled the lower cavity. The aneurism contained a few fibrinous laminæ. All the bronchial tubes were filled with blood. In the lower and middle lobe of this lung were also observed patches of lobular pneumonia of the characteristic granular texture, of a pinkish-grey colour, and surrounded by a blood-stained areola.

Digitized by Google

The *left lung* presented characters essentially the same as those of the right, *i. e.* a mingling of lobular pneumonia and crepitant tissue; there were no basic cavities in this lung.

Remarks.—From the characters of the cavities in the right lung, their smooth, tough walls, which were, however, thin, and the pleural adhesions corresponding to them externally, I am inclined to think that they were of a date considerably prior to that of the disease so rapidly progressing at the time of death, perhaps contemporaneous with the old yellow, cheesy nodules, a few of which were found scattered through the lung. The thickening of the finger ends noted in June is also confirmatory of this view, for though I have certainly seen in one or two cases this process of clubbing come on acutely with pain and throbbing, yet such is not usually the case, and clubbing of the fingers may, as a rule, be taken as a sign of old-standing disease. The large clot which was attached to the aneurism completely filled the cavity, thus arresting the hæmorrhage. Rokitansky describes clots thus formed by hæmorrhage as one means by which cavities may become obliterated, the patient surviving, and the clots undergoing cretaceous degeneration. Of course, there was no possibility of such an occurrence in the present case. There were no tubercles present in the lungs, the recent disease was essentially of the pneumonic type. The quite recent pink pneumonic patches surrounded by blood-stained areolæ, were obviously due to the irritation of blood which had been inhaled into the air-vesicles, and which had become partially decolourised and absorbed, partially mingled with inflammatory elements. The rapidity with which these processes had taken place is noteworthy, there having been only three days' interval between the hæmoptysis and the patient's death. Case 7 in the table presented similar appearances, concerning which I added some remarks to a more full description of the case in the 'Lancet' for May 15th, 1869.

Case 2.—James M—, æt. 31, a signalman, was admitted into the Brompton Hospital October 6th, 1870, under the care of Dr. Symes Thompson, who has kindly permitted me to bring the case before the notice of the Society.

Patient had been ill for seven years with cough and expectoration, and had emaciated during the last twelve months. The expectoration had diminished lately. He had never had hæmoptysis. There was no hectic on admission. He was seized on October the 9th with

Digitized by Google

hæmoptysis, expectorating about a pint of blood, and died almost instantly.

Autopsy, October 10*th*.—The heart was healthy, its right ventricle being quite empty.

Left lung.—The upper lobe firmly adherent, the pleura covering it being much thickened, with here and there fatty tissue between its two layers. This lobe was excavated into three large, superficial, dry cavities, with very thin, hard walls, having a bluish section, and lined by false membrane. These cavities contained some large trabeculæ, and were partially occupied by recent blood-clots. In the central cavity (corresponding with the anterior axillary region) the source of hæmorrhage was found to be a flattened aneurism of about the breadth of a threepenny-piece, and having a wide triangular rupture at its central part. The aneurism freely communicated with the subjacent vessel, a large tertiary division of the Pulmonary Artery, which ran along the side of the cavity. The lower lobe of the lung was crepitant, and studded with discrete granulations, resembling those of recent miliary tubercle, but somewhat angular, and surrounded with pigment and with radially converging lines, as if they had undergone contraction. At many points a pigment mark could only be distinguished, suggesting the probability of the miliary nodule having been absorbed. In the central portion of this lobe were several hard, circular, yellowish-white, semi-cartilaginous nodules (the younger-looking ones granular), isolated from the rest of the pulmonary tissue, and not surrounded by collections of miliary tubercle.

The *right lung* presented some old adhesions at the posterior apex; a small cavity there, and scattered granulations throughout the rest of the lung, which was generally spongy and free from pneumonia. The granulations were isolated and pigmented, presenting characters similar to those in the opposite lung.

The other organs were healthy. There were no signs of syphilis discoverable.

Remarks.—In this case there can be no doubt as to the cavities having been of very old date and in a perfectly *quiescent* state. Here, as in the last case, there had been no hæmoptysis prior to the fatal attack.

Another point of some pathological interest in this case, but not bearing upon the present question, is the presence of the miliary tubercles above described. I think it might be very fairly assumed

Digitized by Google

that the hard nodules found in the middle lobe were the remains of former disease, bearing the same date as that which gave rise to the cavities, and they agreed in structure with the cheesy nodules upon which modern observers lay so much stress, as being infecting centres for fresh tuberculosis. It is probable, therefore, that they may have originated the eruption of miliary tubercle dispersed through the lungs, the only objection to this view being that the miliary tubercles were not more thickly scattered round the nodules than elsewhere, which thus had not the appearance of foci of disease. The tubercles themselves, though doubtless of tolerably recent production, presented characters which, I believe, are only rarely met with; they were evidently contracting and becoming obsolescent. I have met with this form of tubercle in the enlarged lung on the comparatively healthy side of patients who have died of phthisis mainly unilateral and of the "fibroid" variety;[1] somewhat similar granulations were present in Case 3. Such appearances lend comfortable support to the opinion that true miliary tubercle may stop short in its development for a time at least, and may possibly altogether disappear.

Case 3.—William M—, æt. 31, an engineer, admitted into the Brompton Hospital, under my care, in Dr. Cotton's absence, October 10th, 1870.

Patient had suffered from constant cough for twelve months. Two cousins had died of phthisis. He first had hæmoptysis in January of the present year to the amount, he stated, of two pints, and again still more copiously a month before admission. He had lost considerably in weight, and had suffered from night sweats; no diarrhœa. He complained on admission of constant cough, with profuse nummulated expectoration, great shortness of breath, and considerable general exhaustion. He was emaciated, and had a dry red tongue, a rapid pulse, and some œdema of both legs and arms. Urine contained lithates, but no albumen.

The physical signs, October 11th, showed considerable excavation of lung on both sides, most on right. On the left side was heard most distinctly, opposite the second rib and corresponding interspace, a little within the nipple line, a remarkable variety of amphoric breathing. The first third or half of the inspiration was peculiarly jerking, and would be best described as interrupted-amphoric; the remaining part of inspiration and the expiration were equably amphoric.

[1] *Vide* 'Clinical Transactions,' vol. ii, p. 185, note.

Digitized by Google

The only explanation of the sound which suggested itself to me at the time was that of a plug of tough mucus partially obstructing a large bronchus at its entrance into a cavity, so that on the cavity becoming more expanded during the latter half of the inspiration there would be room enough for air to pass in an uninterrupted current. Mr. Hind (clinical assistant) had also observed the sound previously; it was very distinct and persistent.

Patient died the next day, October 12th, almost instantly, of hæmoptysis.

WOODCUT 1.

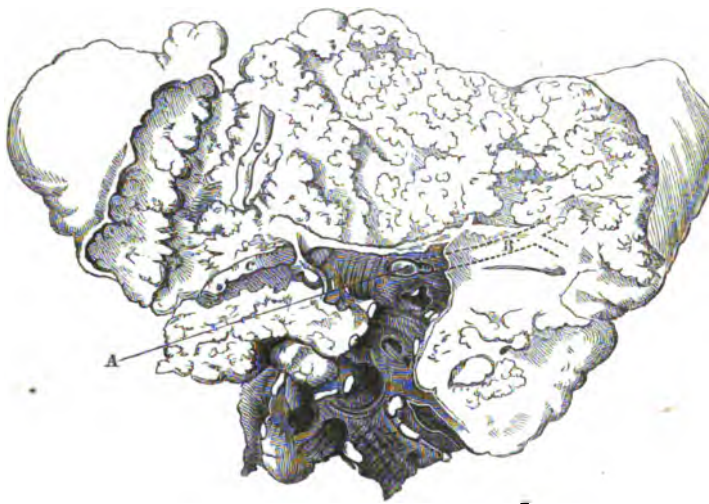

Illustrating Case 3.

Post-mortem examination.—There were cavities in both lungs, largest on the left side; a large, thin-walled, ragged excavation occupying the whole of the upper part, and consisting of many cavities which had broken into one. The pleura was somewhat thickened. The internal surface of this cavity was vascular and roughly trabeculated, and large vessels were exposed in several places. A main bronchus opened into the cavity near its upper part, at the same time sending upwards a considerable branch, which opened into it at another point.

Immediately at the point where the bronchial tube abruptly termi-

Digitized by Google

nated in the cavity, a small oval dilatation of a vessel passing transversely beneath it projected through a button-hole slit in its mucous membrane (Fig. 1, A). On cutting into this dilatation it was found to be due, in part, to a considerable thickening of the vessel wall, but mainly to its local dilatation. The vessel, on being traced upwards, proved to be a branch of the Pulmonary Artery perfectly patent. On inserting a flexible piece of silver wire, and directing it along the continued course of the vessel (B), it was found to pass obliquely through the wall of the cavity in a downward direction, and thence along the cavity wall, completely exposed on one side for nearly two inches; but on near examination the true wall of the vessel was found beyond the first half inch of its course along the side of the cavity to have been completely eroded, leaving a well-defined margin at this point, from beneath which the wire appeared; the rest of the vessel really consisted of fibrinous coagulum, from over which the vessel wall had been removed by ulceration for a distance of about an inch. Another branch of the artery given off in a direction upwards immediately before the branch upon which the aneurism is situated, passed similarly through the cavity wall and appeared exposed, passing along its side for a considerable distance. A small rounded opening perforated the wall of this vessel an inch beyond its entrance into the cavity, and as the vessel was patent beyond, this aperture was thought to have been the source of the hæmorrhage, but on further examination the vessel was found almost completely occupied by fibrinous coagulum between this perforation and its origin from the main branch. There can be little doubt, therefore, that the first-named erosion of the vessel in its main course beyond the aneurism was the real source of the hæmorrhage.

There was extensive disease of the rest of the lung mainly of the pneumonic variety.

Remarks.—The cavity above described was of tolerably old date. Its walls were undergoing a process of acute ulceration, leading to extensive exposure of vessels, and eroding their walls before they could become completely obliterated. The next case will illustrate even better than this the long continuing patency of many of the larger vessels coursing along the walls of cavities, and their gradual closure by deposition of fibrin only at that part of the vessel-wall which is attacked externally by the ulceration. In the present case the vessel-wall was ulcerated away, exposing the coagulum, and the ulcerative destruction had extended above the attachment of

Digitized by Google

the coagulum, whence the fatal hæmoptysis. The small aneurism illustrates the formation of such dilatations by yielding of the artery at the point where it receives least support. Its situation, projecting into a large bronchial tube just at its termination in a cavity, and its expansile pulsation during life, fully accounted for the peculiar sounds heard a few hours before the death of the patient.

In this case no doubt the blood pressure was considerably increased in the vessel by its becoming blocked up by coagulum a little beyond, and by the simultaneous blocking of the other main tributary of the parent vessel.

CASE 4.—C. T—, æt. 36, a coachman, unmarried, admitted, October 11th, into the Brompton Hospital under the care of Dr. Pollock, who kindly allows me to bring the case forward, had been accustomed to drink very freely, and had had syphilis. Had suffered from winter cough for seven years, constant bad cough twelve months, expectoration abundant; occasional hæmoptysis to amount of one ounce. Patient on admission, October 11th, presented the symptoms and signs of rapidly progressing phthisis, and died on the 22nd. He had no hæmoptysis while in the hospital.

Post-mortem examination twenty-four hours after death.—Emaciated, right side of chest flattened; pleural layers on right side firmly adherent, and thickened both at upper two thirds, and also at diaphragmatic portion. This lung was contracted, the upper and middle lobes excavated by widely communicating cavities, with indurated walls with which the thick pleura was intimately blended, having deep coloured, very vascular, trabeculated surfaces. Bronchial tubes inflamed, and at parts ulcerated. Close to the inner wall of the upper and largest cavity, a main branch of the Pulmonary Artery (A, Fig. 2), measuring three quarters of an inch when cut across, divided into two branches, two eighths and three eighths of an inch across respectively, which diverged from one another in the walls of the cavity imbedded in trabecular ridges of hardened pulmonary tissue. After thus traversing the wall for a little more than half an inch, these vessels, which were remarkably symmetrical, became fully exposed in the cavity. The left or upper branch, rather the smaller of the two, appeared as a rounded, firm, rod-like process, a little more than half an inch long, terminating in a free blunt-pointed extremity; its surface had a glistening pinkish pearly aspect, like the internal coat of an artery. On examination, after opening up

Digitized by Google

the vessel, this process was found to consist of a firm, smooth, fibrous coagulum (Fig. 2, B), which was attached to the inner surface of the exposed wall of the vessel. It terminated above in a similarly blunt-pointed extremity, and occupied two thirds of the calibre of the

WOODCUT 2.

Illustrating Case 4.

vessel. The internal coat of the vessel, elsewhere smooth and natural-looking, here passed with the external coat over the fibrous clot on its outer side, so as to enclose it; but it soon terminated in a

Digitized by Google

delicate margin near the upper end of the coagulum, having evidently been denuded from the remainder of that process by ulceration. The vessel was still patent at the inner side of the coagulum, but gradually diminished and terminated at its extremity. A small branch given off just above the coagulum terminated in a precisely similar manner (c), and in this instance the termination of the vessel wall could be plainly traced on the coagular process as a delicate margin, left by the ulcerative destruction which had denuded the lower part of the coagulum.

The arteries leading to these cavities were mostly somewhat wrinkled, the contraction of the surrounding tissue having diminished their calibre.

The lower lobe of the lung, excavated at its summit, was actively congested and studded with groups of tubercular granulations elsewhere.

The left lung presented at its apex a cavity having all the characters of those on the right side, except that the pleura was not appreciably thickened, and the cavity not so superficial. The rest of the lung gave evidence of acutely progressing disease, innumerable groups of gray granulations being dispersed throughout, associated with much active congestion, though comparatively little lobular pneumonia. Indeed, externally, the lung appeared generally emphysematous, with the exception of the apex, where the peculiar bluish depressed tracts on the pleura marked the situation of the old-standing disease beneath. The larger bronchial tubes were very vascular; their mucous membrane much thickened, and presenting several sharply defined deep ulcerations, the margins of some of which were sloughy. On examining the walls of the cavity at the apex several vessels were found exposed, and many of them on being cut across were found still patent. One of them passed across the cavity as a trabecula, one and a half inch in length, the central third of which it almost wholly formed. On cutting open this vessel it was found to be of the size of a crowquill, and given off with a smaller branch from one of the larger divisions of the Pulmonary Artery at the commencement of the trabecula. At the point where it was most exposed, *i. e.* at the middle third of the trabecula, the greater part of its calibre was occupied by an elongated, oat-shaped fibrous coagulum, which was firmly attached to the internal wall of the vessel on the side denuded by the ulcerative process, and which terminated above and below in a free blunt-pointed extremity. The re-

Digitized by Google

maining portion of the vascular canal was unaffected, its lining membrane perfectly natural, and it was occupied by a dark soft post-mortem clot. On tracing the vessel further, the portion to which trabecular tissue was still attached externally remained natural, the opposite exposed wall was thickened by the uniform deposition on its internal coat of laminæ of fibrin from which by careful manipulation it could be partially separated, but further on, the wall of the vessel became thinner and eroded by ulceration, until finally at the further end of the trabecula it could no longer be traced, the fibrinous clot becoming exposed. The vessel here terminated, having previously given off a small branch from its opposite (patent) side, which after a course of half an inch terminated in a free closed point.

General remarks and conclusions.—The facts brought forward in the description of the above four cases, and also those briefly related in the table, show I venture to think conclusively that *fatal pulmonary hæmorrhage in cases of advanced phthisis almost invariably proceeds from rupture of a branch of the Pulmonary Artery in a cavity, either traversing its walls, or crossing it imbedded in a trabecula.* Of the fifteen cases tabulated (including the three above described) in all the twelve cases in which the source of hæmorrhage was discovered post-mortem, it was found to be of this nature. In six of these twelve cases a well-marked sacculated aneurism was found situated upon the pulmonary branch, having caused death by rupture. These aneurisms varied in size from that of a large pea to a Maltese orange, had thin very friable walls, and were usually devoid of coagula, or contained only a few imperfect fibrinous laminæ. Of the remaining six cases in which the source of hæmorrhage was traced, in five the vessel was bulged at the seat of rupture on the exposed surface only, forming what might be called a semi-fusiform aneurism or ectasia. In these cases the wall of the vessel at its bulged portion was usually greatly thickened, though more brittle than natural. Dr. Rasmussen describes this thickening as due to hypertrophy of the muscular coat of the artery. I cannot think that this is the true explanation, but shall have to refer to this point presently. In the remaining case (12 of Table, 3rd specimen exhibited) the hæmorrhage had resulted from ulcerative erosion of the wall of a branch of the Pulmonary Artery, on which, however, a little higher up there was a small aneurism or ectasia situated.

It will be interesting next to note the kind of cases in which

Digitized by Google

these hæmorrhages are most apt to occur, and for this purpose one may with great practical convenience divide cavities into *old-standing quiescent*, *old-standing active*, and *recent* cavities. Of these three varieties the first is certainly that which is most favorable for the production of pulmonary aneurisms or ectasias; and there seem to be good grounds for saying that the more chronic and quiescent the cavity, and the more unilateral the disease, the more nearly, in short, it approaches the type of what has been described as fibroid phthisis, the more probable is it that hæmorrhage, if it occur in any quantity, proceeds from a pulmonary aneurism. A glance at the table will justify this observation, almost all the cases being chronic and unilateral, having old disease with contraction on one side (in most cases the left), and enlargement with comparatively slight disease on the other. In cases 7 and 10 tolerably acute catarrhal pneumonia had supervened upon the old disease. Those who have endeavoured to ascertain the real date of commencement of so insidious a disease as phthisis, will probably agree that the durations noted in the fifth column might in most cases be truthfully prolonged, and thus rendered more in accordance with the histories as registered by the pathological changes found in the lungs.

The very gradual and insidious necrotic process by which the cavities in these cases, originating at first in softening of pneumonic or tubercular consolidations, extend before becoming altogether quiescent, a process consisting of fatty metamorphosis of the fibroid induration which circumscribes the softened mass, is most favorable to the preservation of the patency of the large vessels in the immediate neighbourhood. One or more vessels may run for a considerable distance very superficially along the wall of the cavity, or may bear to it only a tangent relation in their passage elsewhere. On becoming exposed at one point, the vessel-wall missing its wonted support, becomes strained by the blood-pressure and thickened at this point, not, I think, as Dr. Rasmussen supposes, altogether by hypertrophy of its muscular coat, though this coat is undoubtedly thickened, but by an inflammatory change set up by the increased strain to which it is subjected. The uniform semigelatinous appearance, glistening and firm section of the thickened wall, together with the fact that the thickening only takes place on the side of the vessel which is exposed, would seem conclusively to show that the change cannot be merely compensatory hypertrophy, and a microscopic section taken from a specimen in an early stage, also shows a

Digitized by Google

commingling of new connective tissue elements, causing induration, affecting the whole thickness of the wall, and obscuring the distinction between the coats. The local thickening of the vessel wall is usually so great as to cause a marked external enlargement before any actual dilatation of the vessel takes place. The destruction of elasticity, and the degeneration which necessarily follows upon inflammatory changes, leads, however, to the gradual yielding of the wall at the point affected, and it becomes thinner as it expands. The aneurism may give way while it is yet a mere dilatation, and its walls still thick, showing that though thick they are more brittle than natural, or it may expand out into a more or less perfectly saccular form, its walls becoming finally in some cases, wonderfully thin and brittle, looking and feeling very like rotten brown paper, being so degenerated as to be undistinguishable in structure from that of any fibrous lamina it may contain.[1]

In the second class of cases the cavity is, I am inclined to think, usually of tolerably old standing; its walls are thick and indurated, but instead of being in an inactive condition are undergoing a rapid ulcerative process; such cavities are extremely vascular and roughly trabeculated, and in them the large vessels are extensively exposed and eroded, and may give rise to fatal hæmoptysis in the manner I have already fully indicated in the description of and remarks on cases 3 and 4. Though hæmoptysis may be very considerable in such cases, *fatal* hæmoptysis is, I am inclined to think, not so common as in the first class. Case 12 of table (III supra) was of this character, and very probably the three cases, 1, 4, and 8, may have been also.

Of the third class of cases I have as yet been able to recognise no example,[2] viz. those in which fatal hæmoptysis occurs from rupture of a vessel in the course of rapid breaking down of degenerated tubercular or pneumonic consolidations. In such cases small vessels

[1] *Vide* Dr. Moxon's case, vol. xx of 'Transactions.'

[2] Among four other cases of fatal hæmoptysis which I have had opportunities of examining since this paper was written one might fairly be considered an example of this class. It was a case of chronic basic pneumonia of some two months' standing, which had proceeded to excavation. The patient, a young woman, was improving under treatment at the Brompton Hospital, when she was suddenly seized with fatal hæmoptysis. *Post-mortem*, the hæmorrhage was found to have proceeded from an aneurism projecting into the cavity. This case is more fully related by Dr. Charles Williams, under whose care the patient was admitted. Vide 'Pulmonary Consumption, its Nature, Varieties, and Treatment,' by Drs. C. J. B. and C. Theodore Williams, p. 151.

Digitized by Google

may become broken across, but the softening which is mainly due to pneumonic processes which have preceded is in great measure the result of the obliteration of the small vessels involved in the inflammation. The tissue immediately surrounding the large vessels possesses greater vitality; these arteries, if exposed at all, are so after being involved in and surrounded by acute inflammation, and are more likely to become entirely closed by coagula. One readily perceives the difference between the two cases. In those of the first and second variety the artery is gradually exposed and invaded on one side, the other remaining still in contact with living tissue which preserves the nutrition of its wall. In the third variety at present under consideration the artery is surrounded and involved by acute inflammation, and though it preserves its physical shape after all other tissues have broken away it has by this time ceased its function as a blood channel. I much regret that I have not more minutely examined into the condition of the heart in these cases; its texture and valves were healthy in all, and with one exception there was no obvious hypertrophy. The observations of Dr. Peacock[1] show that the weight of the heart in persons who have died of Phthisis, though less than in those who have died of other acute diseases, is greater than that of those who have died of other chronic diseases. Dr. Peacock also points out that the decrease in the size of the heart in Phthisis is due to diminution of its cavities, and the capacity of its orifices, while both the right and left ventricles are thicker than in other chronic diseases. In his tables, however, Dr. Peacock makes no distinction between the different kinds of Phthisis, and no doubt his remark concerning the relative weight of the heart in cases of Phthisis generally, would apply with increased force to those very chronic forms, many of which approximate to the conditions met with in cirrhosis. I think, therefore, the hearts in my cases were no doubt relatively heavy, though they were certainly not enlarged.

There seems to be no special predisposing causes favouring the occurrence of aneurism of branches of the Pulmonary Artery. There was no special history of drink or syphilis in any of the cases recorded in the table. In one only was there granular disease of the kidney; and the fact of the Pulmonary Artery and its branches being perfectly healthy, except where exposed to adverse local influences, shows these influences alone to have any important effect in determining the occurrence of aneurisms. These cases, therefore, are in no respect

[1] 'Weight and Dimensions of the Heart in Health and Disease.' 1854.

Digitized by Google

related to aneurisms of the aorta and systemic arteries. The age of the patients varied between fourteen and forty—average twenty-five. In ten out of the twelve cases in which the source of hæmorrhage was discovered it was found in the left lung, the side on which the disease was most advanced.

There is only one other point to which I would refer, and that is as to the colour of the blood expectorated. It is much insisted on by Dr. Carl Bürger as an argument in favour of copious hæmorrhage generally proceeding from the bronchial vessels or pulmonary veins, and only very rarely from the Pulmonary Artery, that in most recorded cases of hæmoptysis the colour of the blood expectorated has been described as bright red. Several important fallacies underlie this argument however; in the first place it is rare for a medical observer to be present at the moment of hæmoptysis, and the blood expectorated on to the floor or into a basin becomes in a great part arterialised before it is seen; if expectorated into a deep receiver only the surface may become arterialised, and the deeper layers remain dark, but unless the hæmorrhage is very rapid indeed, it becomes largely mixed with air, and rendered frothy and bright, even before it can be expectorated.

I have endeavoured to confine myself in this paper strictly to the consideration of fatal hæmoptysis occurring in cases of *advanced* phthisis. Such an accident happens occasionally, though rarely, in the early stage of phthisis, and cases are recorded in which it has happened without any disease of the lung being present.[1] The hæmorrhages whether profuse or slight occurring independently or in the earlier stages of Phthisis, and also sometimes in the later stages, probably in most cases have a very different origin from those referred to in the present paper, being derived from the bronchial mucous membrane or the vesicles of the lung, and due to numerous causes which disturb the circulation through the pulmonary and bronchial vessels. This department of the subject, however, requires much further investigation, and I merely mention it here lest I might be supposed to imply that the larger branches of the Pulmonary Artery are the source of all, or even necessarily of the majority of attacks of hæmoptysis. *October* 15*th*, 1870.

[1] Dr. Bürger quotes a case of the kind.

Digitized by Google

Table Illustrating Dr. Powell's

Cases of Fatal Hæmoptysis[1] *occurring at the Brompton*

No.	Name.	Age.	Sex.	Physician under whose care.	Duration	Hereditary predisposition.	Attacks of Hæmoptysis.	Heart.
1	F. W.	21	M.	Dr. Alison	12 mo.	No	No attack until May 8th, 1868, when fatal	Healthy
2	P. D.	15	M.	Dr. Cotton	2 years	Father died of phthisis	1st hæmop. 12 mo. ago; six attacks of copious hæmop. between April 4th, and death June 10th, 1868	Healthy, 5¾ oz.
3[2]	W. D.	40	M.	Dr. Powell	6 years	No	1st hæmop. 6 mo. ago; copious again July 24th, 27th, May 6th and 8th; died August 9th, 1868	Healthy, large, right cavities enlarged
4	W. B.	28	M.	Dr. Sanderson	5 mo.	Brother died of phthisis	?	Healthy
5[2]	H. C.	27	M.	Dr. Cotton	18 mo.	Mother, sister, and brother died of phthisis	No attack until November 18th, 1868, when death resulted in a few minutes	Healthy, flaccid; right ventricle empty

[1] Only such cases are here included as have died immediately from, or within a few days of, the hæmoptysis.

Digitized by Google

Cases of Fatal Hæmoptysis.

Hospital between February, 1868, *and November*, 1870.

Left lung.	Right lung.	Source of hæmorrhage.	Remarks.	Autopsy conducted by
Contracted; large cavities, with dense fibrous walls; much fibroid induration; some grey tubercle at base. Pleura cartilaginous.	Enlarged, tissue crepitant; some scattered grey granulations.	No ruptured vessel discovered.	A case of one-sided chronic phthisis, with much fibroid change and tubercle.	Dr. Powell.
Small, 9½ oz.; cavities at apex, one containing aneurism. Rest of lung atrophied.	Enlarged, 10½ oz.; some scattered tubercle; tissue crepitant; no pneumonic centres.	Aneurism size of Maltese orange, sacculated, communicating with a considerable branch of the pulmonary artery; vessel much diminished beyond.	A case of chronic tubercular phthisis.	Dr. Powell.
Much contracted; great thickening of the pleura, and fibroid degeneration of lung. Three large chronic cavities, occupying almost the whole lung, in lower of which small aneurism found.	Enlarged, emphysematous; some scattered grey granulations.	Aneurism size of a pea, situated on a small arterial branch, which becomes obliterated half an inch beyond.	A case of chronic, one-sided, tolerably typical, "fibroid" phthisis.	Dr. Powell.
Chronic cavities at apex; cheesy nodules scattered below.	Apex wrinkled, containing indurated nodules; some scattered granulations.	No ruptured vessel found.	The *post-mortem* appearances suggest that this case was of much longer duration than 6 months.	Dr. Powell.
Diminished in size; an adherent cavity at apex; scattered tubercle below.	Enlarged; a wrinkled cavity at apex, surrounded by emphysema. A second thin, dense-walled cavity at lateral part containing aneurism.	Aneurism sacculated, thin-walled, size of large pea; vessel a branch of pulmonary artery, size of crowquill.	A case of chronic tubercular phthisis. Cavities in a state of quiescence.	Dr. Powell.

[2] Clinical Societies 'Transactions,' vol. ii, "Phthisis with contracted lung," Case I.
[3] 'British Medical Journal.'

Digitized by Google

No.	Name.	Age.	Sex.	Physician under whose care.	Duration	Hereditary predisposition.	Attacks of Hæmoptysis.	Heart.
6	E. L.	20	F.	Dr. Cotton	5 years	Brother died of hydrocephalus	Copious hæmop. 18 mo. ago, recurring every second day for 2 mo., then at longer intervals; again October 21st, 28th, 29th, November 4th and 16th, 1868; death three days afterwards from exhaustion	Healthy
7[1]	R. W.	25	M.	Dr. Sanderson	3 years	No	No attack until March 11th, 1869, 2 oz.; 13th, 2 pints; died on 17th from exhaustion	Healthy
8	F. B.	...	F.	Dr. Cotton	?	No	No previous attack; died in a few minutes, February 3rd, 1870	Small, cavities empty
9[2]	F. L.	14	F.	Dr. S. Thompson	14 mo.	Father and mother died of phthisis	Hæmop. January and February, 1869; nearly fatal attack in November; death instant., February 9th, 1870	Healthy, empty, contracted
10[3]	W. H.	25	M.	Dr. Powell	12 mo.	Uncle died of phthisis	No previous attack; copious hæmop. September 23rd, 1870; again 25th, followed by shock and orthopnœa; died in twenty-six hours	Healthy

[1] 'Lancet,' May 15, 1869. [2] 'Medical Times and Gazette,' May 21, 1870.

Digitized by Google

Left lung.	Right lung.	Source of hæmorrhage.	Remarks.	Autopsy conducted by
Chronic cavity at apex, firmly adherent; thick pleura; small vascular dilatation at upper part of cavity.	Tolerably clear.	A slight bulging of vessel wall as it crossed upper part of cavity; very widely ruptured.	A case of chronic tubercular phthisis, making but little progress. No pneumonic centres were found as the result of hæmoptysis.	Dr. Powell.
At apex congestion, with points of white pneumonic degeneration. At summit of lower lobe a moderate-sized cavity containing aneurism. Rest of lung emphysematous, with some scattered grey tubercle.	Considerable cavities and grey induration; some recent pneumonic centres at anterior base.	A small, widely ruptured dilatation of branch of pulmonary artery; opening closed by partially decolourised coagulum.	A case of chronic tubercular phthisis, with some supervening pneumonia at left apex. Some fresh pneumonic centres at right anterior base, the result of the hæmoptysis.	Dr. Powell.
A large cavity at apex; grey induration and cheesy nodules below.	Enlarged; some small cavities; scattered grey granulations (angular).	Source of hæmorrhage not found. Too much force used in injecting vessels, causing extensive extravasation of injection fluid.	Chronic tubercular phthisis.	Dr. Powell.
Contracted; indurated with thick pleura, a large cavity at inferior part of which aneurism found.	Enlarged emphysematous, with scattered granulations. An old contracting cavity at apex.	Small oval, thick-walled bulging on one side of vessel, traversing indurated wall of cavity. Small, slit-like rupture.	Chronic, tolerably one-sided phthisis. Death very sudden considering smallness of rupture.	Dr. Powell.
Scattered pneumonia; patches in all stages of degeneration.	Also much degenerated lobular pneumonia; a moderate-sized cavity at apex and one at base; smooth-walled, at upper part of which aneurism situated.	Aneurism thin-walled, sacculated, size of walnut, communicating by small opening with a secondary branch of pulmonary artery running across top of cavity.	Sub-acute pneumonic phthisis, with granular kidneys. Cavity at anterior base of older date than other disease.	Dr. Powell.

[3] Vide full notes, supra.

Digitized by Google

No.	Name.	Age.	Sex.	Physician under whose care.	Duration	Hereditary predisposition.	Attacks of Hæmoptosis.	Heart.
11[1]	J. M.	31	M.	Dr. S. Thompson	7 years	Mother died of phthisis	No previous attack; died abruptly October 9th, 1870, ejecting about a pint	Healthy, cavities quite empty
12[1]	W. M.	31	M.	Dr. Powell	12 mo. constant cough	Cousins died of phthisis	Copious hæmop. January, 1870, and 1 mo. ago; died October 15th, almost instantly	Healthy

The following three cases of fatal hæmoptysis from rupture

13[2]	E. C.	28	M.	Dr. Cotton	?	?	Admitted November 3rd 1865; 1st hæmop. 5 mo. ago; moderate again, half-pint, November 4th; repeated on 24th, 1865; patient sank a few days afterwards.	Healthy
14[3]	...	30	M.	Dr. Quain	9 mo.	No	No previous hæmop. before fatal attack.	Not mentioned as diseased

[1] Vide full notes, supra. [2] 'Medical Times and Gazette,' Jan. 13, 1866.

Digitized by Google

Left lung.	Right lung.	Source of hæmorrhage.	Remarks.	Autopsy conducted by
Three very chronic dry cavities at upper part, in central one of which aneurism found. Lower lobe contains scattered grey tubercle.	Old adhesion and small cavity at apex; rest of lung crepitant, containing some scattered granulations.	Aneurism flattened, size of a three-penny piece, very thin-walled, communicating freely with subjacent vessel traversing smooth indurated wall of cavity. Rupture triangular, wide.	A case of very chronic phthisis, with quiescent cavities of old standing.	Dr. Powell.
Upper lobe excavated by inter-communicating cavities, with dark vascular walls; cheesy pneumonia and tubercle below. A small aneurism situated at entrance of bronchus into main cavity. Vessels of cavities extensively exposed and diseased; one of these ruptured.	Cavities at apex; cheesy pneumonia and tubercle below.	An exposed vessel lying along wall of cavity, has given way by a small rounded hole. No bulging at this point.	A case of subacutely progressing pneumonic phthisis, with a tolerably old cavity, the walls of which are in a state of active ulceration.	Dr. Powell.

of pulmonary arterial aneurisms occurred in 1865 *and* 1866.

Condensed; a large cavity in upper lobe; another in lower lobe, at lower part of which a small arterial bulging found.	A small vomica at apex, but little disease elsewhere.	Branch of pulmonary artery exposed for ¾ inch, where existed an elongated dilatation, partially divided into two, the smaller one having ruptured.	Aneurism the result of local loss of support to vessel wall, together with softening and degeneration of walls from exposure in cavity. (Dr. Cotton.)	Dr. Powell.
Pleura much thickened. A large trabeculated cavity occupying whole upper lobe, in lower part of which dilated vessel found. Small cavities in lower lobe; yellow tubercle.	—	Branch of pulmonary artery, size of crowquill, exposed for 2 inches in wall of cavity, and irregularly dilated into a varicose aneurism.	—	Dr. J. Williams.

[3] 'Pathological Transactions,' vol. xvii, p. 79.

Digitized by Google

No.	Age.	Sex.	Name.	Physician under whose care.	Duration	Hereditary predisposition	Attacks of Hæmoptysis.	Heart.
15[1]	27	M.	W. T.	Dr. Cotton	18 mo.	?	Admitted April 27th, 1866; 1st. hæmop. August, 1865; copious hæmop. July 3rd, 1866, repeated daily until 11th, when death from exhaustion	Large, valves healthy

[1] 'Med. Times,' 1866.

Digitized by Google

Left lung.	Right lung.	Source of hæmorrhage.	Remarks.	Autopsy conducted by
"Contracted, covered by thickened pleura, and bound down by strong adhesions;" old cavities, one of which situated at posterior part of middle of lung; smooth walled; contained a pulmonary aneurism; tissue at base of lung condensed, air less.	Enlarged, with two small cavities and some scattered deposit.	Aneurism sacculated, size of walnut; arising from artery, size of crowquill; contained some fibrinous layers.	Left lung in a state of cirrhosis; the cavity in which aneurism contained probably a large bronchial dilatation.	Dr. Dunlop.

Digitized by Google

6. *Case to show identity of gray and yellow tubercles.*

By Walter Moxon, M.D.

The specimen shown was the lung of a river pilot who had died in Guy's Hospital of gangrene of the legs, due to exposure to severe weather while faint from want of food and weak through the phthisis.

It is not necessary to detail the history of the case or the post-mortem appearances found, except so far as they bear on the point advanced in regard of the tubercles. The lungs both had cavities in their upper lobes with indurated patches and tubercles. These tubercles were mostly in the form of gray pigmented patches, arising through spread of the tuberculous disease from points of origin in a continuous budding sort of way; there were also gray and yellow tubercles and intermediate kinds scattered in small clusters in the lower lobes. The larynx and intestine were both rather severely affected; the latter showed tubercles on the outside of the bowel in the peritoneum.

I thought this case worthy of note because of the common type or kind of disease in the lung connecting the two kinds of tubercle present there. I mean the large pigmented iron-gray tubercles or granulated masses around the circumference of which the tubercles are formed. Sections of them have a corymbose appearance. They are not of unusual occurrence. Such patches in sizes varying from a horsebean up to a plum or larger are well known to be not uncommon in phthisis, and I believe they characterise a very severe and often hereditary and otherwise highly "constitutional" form.

But the interest of the case is in the strong contrast which two of these patches showed—I assume that they grow—as spreading from their centre outwards, like the cutaneous eruptions which in section they so much resemble, the central part being the older and the peripheral part that most recently formed. Now the central part has in both exactly the same character and is identical; but the outer zone of one patch has the character of gray subpellucid tubercles of the most typical kind, while the outer zone of the other patch has larger opaque, yellowish-white tubercles of the most scrofulo-pneumonic kind.

Numerous microscopic sections showed that both these kinds of

Digitized by Google

tubercles were seated in the proper pulmonary texture, and not especially about the ends of the bronchial tubes.

I believe in this case there is a kind of evidence bearing importantly on the question of the identity of the two forms of tubercle.

The gray patches occur in the same lung and have the same appearance, structure, size, and relation to the tissue, so that it is impossible to think that two such identical patches arose from

WOODCUT 3.

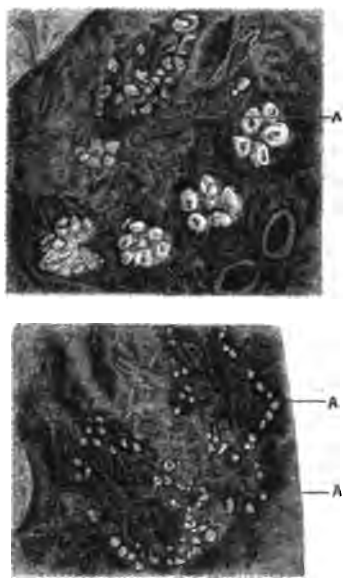

The upper cut shows the zone of clusters of yellow tubercles, the lower cut shows the zone of grey tubercles. The iron-grey areas within the zones are not successfully shown.

dissimilar causes in the same lung together. Granting their identity, it is almost equally difficult to doubt that the tuberculous border around each of the masses stands to the mass as its most recently formed part.

The special weight which I wish to credit to this case is herein, that the identity of the two chronic patches established the identity of the yellow and gray tubercular border which are respectively the more recent parts of these patches.

Digitized by Google

7. *Lymphadenoma of the mediastinum and kidneys.*

By C. Murchison, M.D.

These specimens were obtained from the body of a patient, Hannah G—, æt. 21, who had been admitted into Middlesex Hospital on Dec. 6th, and died on Dec. 10th, 1870. Her father and three aunts, and an uncle on the father's side, had died of phthisis; her mother had died of cancer of the uterus; and a sister had suffered from rheumatic fever. Her own health had been good until fifteen months before coming to hospital, when she had been laid up for a month with rheumatic fever and acute pain in the left side of the chest. After this she returned to service; but she soon began to complain of dyspnœa and palpitations on any slight exertion; and during the winter of 1869-70 she coughed up, on several occasions, a little bright red blood. One day in August, 1870, she was suddenly seized with a severe fit of coughing, and ever since the liability to dyspnœa and palpitations had increased, and she had suffered at times from severe pain at the epigastrium and stretching thence round the left side. She had not lost flesh nor perspired at night.

On admission into the hospital the patient's body was found to be fairly nourished, but she had great lividity of the lips, cheeks, hands, and feet, and moderate œdema of the legs, and she suffered from great dypsnœa amounting to orthopnœa. In front of the chest there was absolute dulness, commencing one inch below the left clavicle, continuous downwards with that of the heart, and extending two inches across the middle line to the right side. Near the right margin of this dulness, corresponding to the second right costal cartilage, was a bulging about the size of a pigeon's egg, which the patient was confident had not existed longer than four or five days. It was hard and did not pulsate; it was not the seat of a bellows-murmur and was not tender. No breath sound could be heard over the dull space, and there was an absence over it of vocal resonance and thrill, but vesicular breathing was audible between its upper margin and the clavicle. Posteriorly there was impaired resonance, but not absolute dulness, over the upper half of the left lung, with distant tubular breathing and pleuritic friction. Over the lower three inches of the left base there was also dulness

Digitized by Google

with feeble breathing and diminished vocal resonance and thrill. With the exception mentioned, the right lung was clear on percussion. Dry bronchial râles could be heard over both lungs. Pulse 120, small, weak, and irregular, but equal in the two wrists; impulse of heart imperceptible and sounds heard with difficulty, and not transmitted through the dull space. No dysphagia nor inequality of pupils, and voice natural. No appreciable enlargement of the cervical or axillary glands. Occasional retching of food. Urine loaded with lithates, and contained a small quantity of albumen. Temperature 101° Fahr.

While in the hospital the patient had not merely permanent orthopnœa, but had also severe paroxysmal exacerbations of dyspnœa, during which she seemed in danger of asphyxia. She also suffered from very severe darting pains in the upper part of the left side of the chest, and had great tenderness over the dull space and in the epigastrium, so that it was almost impossible to percuss the chest. On Dec. 10th an attack of dyspnœa came on suddenly, which in ten minutes terminated in death.

Autopsy.—On removing the sternum a tumour, as large as a child's head and weighing several pounds, was found occupying the mediastinum and encroaching upon both lungs, but especially upon the left. It was firmly adherent to the right costal cartilages, and the prominence noted during life to the right of the sternum was found to be due to a portion of the tumour protruding between the second and third costal cartilages. The tumour pressed the heart backwards, so that no portion of this organ was visible on removing the sternum. Posteriorly the tumour extended to the spine and embraced the roots of both lungs, and extended some way into the interior of the left lung. The left pneumogastric nerve was traced into the tumour. The tumour was nodulated on its outer surface, and its cut surface was firm and grayish-white, and yielded no milky juice. The left pleura contained thirty ounces of serous fluid. There were no isolated masses of disease in the lungs, but the glands in the posterior mediastinum and one deep-seated gland in the left side of the neck were much enlarged and presented a similar appearance to that of the tumour. The thyroid gland was enlarged to about double its proper size, and in the lower end of the left lobe was a white nodule the size of a pea, having the same structure as that of the tumour. Both kidneys were congested and in the cortical

Digitized by Google

substance of both was a mass as large as a marble of the same morbid tissue as that of the thoracic tumour.

Microscopically the morbid material in the different parts of the body was found to consist of minute spheroidal bodies, apparently lymph-corpuscles, held together by a transparent stroma. The structure was the same as that of two other specimens described by me in the two last volumes of the 'Society's Transactions' (vol. xx, p. 192; and vol. xxi, p. 372), and the case was evidently another example of the disease now known as lymphadenoma.

January 17*th*, 1871.

---

8. *Intra-thoracic growth; enlarged thymus, &c.; Hodgkin's disease or lymph adenoma.*

By James Risdon Bennett, M.D.

Elizabeth H—, æt. 17, a spare, delicate-looking girl, height 5ft. 1½ in., weight 6 st. 2 lbs., was admitted into the Victoria Park Hospital under my care, January 7th, 1871. Her mother is said to have died of "decline and heart disease." Father is living and in good health. She has eight brothers and sisters living and in good health. One sister died, æt. 22, of "fits," and a brother æt. 3 of inflammation of the chest.

Previous history.—She states that up to twelve months ago her health was good and that she never had rheumatism or epistaxis. The catamenia, however, have not yet appeared, nor are the mammæ developed. About a year ago she says that she caught cold from wet feet, after which she had cough attended by a good deal of expectoration mixed with some blood. The cough continued but was better in the summer. A month ago she was obliged to give up her place as a servant, in consequence of the shortness of her breath, which for nine months has been gradually becoming worse. Latterly she has had some nocturnal perspirations, and for three or four months has been losing flesh. A fortnight before admission she had some diarrhœa. There has been no swelling of the feet.

Digitized by Google

Present state.—Face thin; complexion fair and delicate; expression dull and apathetic; emaciated. Some sudamina on the chest and abdomen, but no rose-coloured spots. Tongue tolerably clean, but dry; much thirst; appetite tolerable; bowels regular; some cough, which, however, is not very troublesome. Breathing short, especially on the least exertion. Decubitus chiefly to the right; expectoration scanty, consisting of white glairy matter mixed with some pigment. Pulse 140; resp. 36; temp. p.m. 102·5. Some sweating at night, but sleeps pretty well. Urine scanty, loaded with lithates, but free from albumen and sugar. Thorax fairly well developed, but on viewing it anteriorly is much rounded in lower sternal region which is much more prominent than natural. Respiratory movements forced and heaving, the whole chest moving "en masse," with but little natural expansion of the ribs. The superficial veins are somewhat dilated, especially about the left shoulder. Just above the left clavicle there is an enlarged gland, which, she states, has been there since childhood. The whole central anterior portion of the chest is absolutely dull on percussion, and the dulness extends rather more towards the right than to the left side. Under the clavicles and towards the angles of the ribs the resonance is good, and perfectly good in the lateral and posterior regions. The sphere of anterior dulness is of a pyramidal shape, the apex extending full half way up the manubrium of the sternum. The cardiac impulse is most distinctly felt and seen in the epigastrium low down. The sounds of the heart are indistinct, but heard in the natural situation and rather lower than usual. No abnormal bruit can be detected. Over the whole region of anterior dulness there is entire absence of all respiratory sounds. In the right lateral region some creaking and rubbing sounds can be heard, both during inspiration and expiration; on the left side this is less marked. Respiration may be heard in both intra-clavicular regions and throughout the posterior region of the thorax and in the capillary regions. It is, however, everywhere somewhat shallow, and mixed throughout with more or less sonorous, sibilant, and mucous râles. Tactile fremitus can be perceived under the clavicles and behind, and feebly in the lateral bases. The intercostal spaces are fairly well marked when viewed from behind. The liver is enlarged, extending below the ribs, and there is a tumour in the left lower hypochondriac region apparently from splenic enlargement.

Digitized by Google

She was evidently a good deal distressed in her breathing, and the cough frequently came on in exhausting paroxysms, but was unattended by much expectoration. She complained of a certain amount of pain in the sternal and lateral regions, and frequently lay to the right and on her face, or sat up in bed bent forward, resting on her knees. At times she would be somewhat cheerful, but usually was taciturn and took but little notice, apparently absorbed by her general distress and difficulty of breathing. The heart's action was often very rapid but never irregular, and she sometimes complained of tenderness on pressure by the hand or the stethoscope over the cardiac region.

The temperature, respirations, and pulse were regularly noted during the whole time of her residence in the hospital, and generally the observations were made both night and morning. The temperature ranged from 104·2 on the 20th March to 96·8 the lowest, on the 27th January. Usually, however, the range was from 100 to 102. The pulse ranged from 108 the lowest to 160 the highest; and the respirations from 24 the lowest to 48 the highest.

The physical signs never varied in character during her whole illness, but there was considerable variation in the extent and intensity of the signs of bronchial and pleuritic irritation and of the general distress and difficulty of breathing. The central sternal dulness steadily increased, though not rapidly. From first to last there were no signs of displacement (except as regards the situation of the apex beat of the heart) or of local pressure either on the bronchi or trachea or large vessels. Immediately before death, however, there was a certain amount of œdema of the lower extremities and of the right hand, on which she lay a good deal. Nor was there any lividity of features till immediately antecedent to her death.

A marked relation existed between the signs of bronchial irritation, distress of breathing, and the range of temperature, pulse, and respirations. Thus, during the month of January, *i.e.* for the first three weeks after her admission, the signs of serous and mucous irritation were very extensive and various, and the temperature ranged from 100·4 to 103·7, the pulse from 136 to 160, the respiration from 36 to 48.

On the 23rd January she was reported as much relieved. The thoracic symptoms were much less marked, she had scarcely any wheezing and comparatively few bronchial râles, much less pain and

Digitized by Google

general distress, took her food better, and was altogether distinctly improved in her general condition. At this date the temp. was 96·8, pulse 136, respirations 30. This improvement continued for some time, and at this period the splenic enlargement could not be felt.

On the 22nd of February she is reported as worse again, she had again lost her appetite, the wheezing and râles, especially on the right side, were very general, the breathing was much more distressed, the anterior dulness appeared to be extending, she had profuse sweating, and the temp. rose to 103·3, the pulse to 140, the respirations 36 to 38. Of these changes in her condition she experienced several.

In the beginning of March she was much better, but towards the end of the month she had again relapsed. The breath became very short and the cough very troublesome; she also, at this time, became very drowsy and took very little food, she lay quite over on her face to the right; loud, sibilant, and mucous râles were heard throughout the chest except over the region of the anterior dulness, where alone there was any marked deficiency of percussion resonance.

There was but little attempted in the way of treatment. She took, with some apparent advantage, effervescing salines with small doses of digitalis, and sometimes a little nitrate of potash. She did not appear to bear anything in the shape of tonic, but was relieved from time to time by an ether and soda mixture, by the external use of belladonna, mustard poultices, and once or twice by small blisterings with the liquor vesicatorius.

Her diet consisted principally of milk, jelly, beef tea, with a little wine or brandy and eggs.

Autopsy and microscopical examination conducted by Dr. H. G. Sutton.—The body was much wasted. The lower extremities were moderately œdematous.

On raising the sternum its under surface was found firmly adherent over its upper third to a growth lying in the region of the thymus. This growth formed a large, firm, hard, solid mass; it was situated in front of the trachea and just above the base of the heart. It extended down in front of the pericardium to the diaphragm, and laterally to the anterior portion of each lung. When this mass was cut into from above downwards the portion lying over the pericar-

Digitized by Google

dium was seen to be more than an inch thick, and this very thick portion extended nearly as high as the top of the sternum, and diminished in thickness as it extended downwards in front of the pericardium. This growth was attached to the outer surface of the pericardial sac, but it had not invaded the bag of the pericardium, and this serous membrane was healthy. The growth extended on each side, as already mentioned, into the anterior portion of the lungs, so that the lung-tissue was in these situations converted into firm, tough, gray, solid tissue; the growth extended about two inches into the lungs. The growth also extended backwards around the trachea, but it had not compressed the air-passage or the vessels at the root of the neck. The cut surface of the growth had a bluish-gray colour, and passing through it was some more opaque yellow tissue. The growth was very firm, tough, and yielded no distinct juice. The portion invading the lungs had similar characters. The aorta and pulmonary artery were uninvolved. The heart was normal. The two sides of the pleuræ were firmly united over the anterior parts of the lungs.

A section of the right lung from apex to base showed the following appearances. There were masses about the size of shillings lying amongst apparently healthy lung-tissue. Each mass was solid, moderately firm, and smooth, and had a bluish-gray appearance, and was very circumscribed and separated from the surrounding lung-tissue. There was also a little dark pigment scattered in each mass. Also in this lung were several bodies about the size of large pins' heads, which were gray, firm, hard, tough; in appearance they looked like so-termed tubercle. The lung substance surrounding these bodies was healthy. The left lung was in a very similar condition to the right. At the root of the right lung a large gland was seen, which was equal in size to a small walnut. It cut with a sense of resistance. The divided surface had a yellowish-gray appearance, and was firm and tough. It was also pigmented in parts, but yielded no juice on pressure.

At the root of the neck, just above the apices of the lungs, the glands were very much enlarged. On cutting into one, which was the size of a walnut, it was seen to have a gray or pinkish-gray appearance, and was firm and tough. In parts the gland substance had a yellowish-gray colour. There was no caseous appearance. The glands in front of the lumbar region were also much enlarged, and presented a similar appearance to those just

Digitized by Google

described, excepting that they were not tough and firm. The inguinal glands were similarly affected. The gland substance yielded no juice. In the liver was a pinkish-gray mass about the size of a florin, which was also firm but not very tough. In one kidney was a similar but smaller mass. The spleen was enlarged, but not very much so; when cut into, some yellowish, firm, circumscribed masses were seen; they varied in size, some were about three quarters of an inch by half an inch, others were about the size of split peas; all had the same appearance but differed in size.

Stomach, intestines, and peritoneum were healthy.

Microscopical examination.—Sections were taken from the growth situated in the region of the thymus, and they were examined by the aid of $\frac{1}{5}$ and $\frac{1}{8}$ of an inch object-glasses. Their growth appeared to be made up of a large number of corpuscles and cells which were lying amongst a fine network-like tissue. The corpuscles very much resembled and were about the size of lymph or white blood-corpuscles, and besides these there were some larger cells which contained distinct nuclei, and here and there some oat-shaped connective-tissue nuclei were seen. The tissue forming the network was for the most part homogeneous-looking, and the corpuscles were lying in the meshes of this network.

When a very thin part of the section was very carefully examined the corpuscles were seen in some situations grouped together in a semicircular manner, and on moving the field a thin group of corpuscles was observed curving in various directions, and the arrangement corresponded with what is seen when channels lined with cells are cut across. Running between and separating some of these groups were clearer spaces, which were bounded by some firm ill-defined, fibre-like tissue. In other parts of the field three or four corpuscles were closely packed together, and they formed a centre, and numbers of other corpuscles were found lying in a network, and the corpuscles and fibres of the network were converging around these centres. Here and there minute blood-vessels were cut across, and the lymph-like corpuscles were collected in larger numbers around the vessel, and the corpuscles and network were arranged in a concentric form around the vessels.

The manner in which the corpuscles were arranged appeared to indicate that the growth consisted of gland tissue, and the appearance of the corpuscles and the way in which they were grouped

Digitized by Google

resembled the medullary or so-called lymph tubes of lymphatic glands, and the passages between the tubes corresponded with the lymph paths. Further, the manner in which the corpuscles were arranged around the vessels resembled what is seen in normal lymph glands. It would appear, therefore, that the growth was made up of lymph gland tissue.

The masses in the lung were carefully examined, they consisted of corpuscles similar to those observed in the growth above described. These were seen in largest numbers outside and around the minute bronchial tubes, and they were observed extending along the alveolar walls, and in some parts they filled up the alveoli. These corpuscles also existed in large numbers around the vessels.

The microscopical appearances observed in the enlarged, firm, indurated glands resembled, for the most part, the growth in the thymus region, also the masses in the spleen. I was, therefore, led to conclude from the microscopical examination that the growths situated in the thymus region, in the lungs, and spleen, and in the lymphatic glands, consisted of the same histological elements, and that they were pathologically the same, and that these growths resembled lymph gland tissue, and corresponded to what has been observed in Hodgkin's disease, or as it is sometimes called lymph adenoma. *May* 16*th*, 1871.

---

9. *Secondary scirrhous, or fibro-cancerous, infiltration of connective tissue of lung, &c.; primary cancer of mamma removed.*

By J. Risdon Bennett, M.D.

Maria Thorpe, æt. 42, a cook, single, very well formed and rather stoutly built; of healthy appearance, dark hair, and well nourished, came under my notice February 25th, 1871. Her mother is living, æt. 63, and in good health. Her father died many years ago "of tumour in the throat." Her only brother is living, and in good health. Asthma, she says, is the family complaint.

Digitized by Google

Previous history.—For four years past she has had cough in the winter, but considers herself to have been in good health till two years ago, when she first detected a swelling in the left mamma. The last two winters she had less cough than before. She never had hæmoptysis nor rheumatism, but has had epistaxis. Last July she went into St. Mary's Hospital, where the mammary tumour was removed by the knife. The wound healed completely and speedily, and she remained well till Christmas last, when she had an attack of so-called bronchitis. At this time she noticed that her breath was shorter than it had ever been before, and this shortness of breath, as well as the cough, have continued ever since. She thinks she has lost flesh latterly, and has been subject to sweatings.

Present state.—The situation of the left mamma is occupied by a large indurated cicatrix, surrounded by considerable thickening and hardening of the integuments. There is some lividity of the edges of the cicatrix, but no ulceration. Some enlarged lymphatic glands may be traced along the edge of the pectoral muscle towards the axilla, where there are two or three enlarged glands. She complains of no pain in the diseased tissues, nor is there any tenderness. The integuments are infiltrated and hardened for some distance around the cicatrix.

She considers her cough to be somewhat better than it has been, but her breath to be even more short. She has some expectoration, not copious, and consisting for the most part of glairy mucus, mixed with some pigment and opaque mucus. This was examined under the microscope, but revealed nothing of a special character. The thorax is ample and well formed, everywhere resonant on percussion, unless it be under the left clavicle, where there is some questionable dulness. The respiration, also, under the left clavicle is somewhat deficient; elsewhere it is distinct and tolerably free, but everywhere mixed with sibilant and mucous râles; sometimes there is much prolonged wheezing. The breathing is short and frequent, and the least exertion induces considerable dyspnœa. The lips are slightly livid, but the general colour of the face is good. Skin soft and sweating. Pulse 100, feeble. The heart's sounds are normal. The catamenia regular. Bowels confined, tongue white, and appetite only moderate. She complains of considerable weakness. Temperature 99·6 a.m.; 99·3 p.m. She was ordered the effervescing calumba mixture, and squill and ipecac. pills at night, and the ether and soda mixture occasionally for any unusual difficulty of breathing.

Digitized by Google

After being ten days in the hospital her general condition appeared to be somewhat improved; she had less cough and expectoration, and the signs of bronchial irritation had considerably diminished. But her dyspnœa was not correspondingly relieved. A few days later she had again more cough, and the expectoration was more muco-purulent in character; but there was not more febrile disturbance. The skin continued moist or sweating, and the temperature 98·9.

March 31st.—She complained greatly of shortness of breath, which had been steadily becoming more and more distressing. The chest, however, remained perfectly resonant throughout, and the mucous râles had almost disappeared, although there was from time to time a good deal of wheezing and whistling. At this time the least movement even in bed seemed to distress her, and, as she expressed it, her "breath was gone in a moment." Her face was at this time paler and more pasty in appearance. She had evidently lost flesh, and her appetite was very poor. The cicatrix had become more prominent, and had assumed a more discoloured and livid appearance. The temperature, also, was higher than it had hitherto been, viz. 100·2 a.m.

April 7th.—She passes very bad, distressing nights from the extreme breathlessness, sitting up in bed, and fearing to make the least movement. She dislikes being noticed or in any way disturbed, but always says that she has no pain. The cough is not troublesome, and there is very little expectoration. Auscultation shows that but little air enters the vesicular texture of the lungs, and the respiration has a short whiffing character. The chest is, however, as far as can be ascertained, quite resonant on percussion.

Subsequent to the above date the face became dusky and livid, and she was extremely restless. Finally she became drowsy and slept much, and expired somewhat suddenly, as though from syncope, on the 10th April.

Post-mortem examination.—April 11th.—Body not emaciated; subcutaneous fat on abdomen an inch in thickness. Muscles firm and ruddy. Cicatrix left after the removal of left breast, extends from the left edge of the sternum almost into the axilla. Cicatrix itself and adjacent tissues dense, indurated, and prominent; no ulceration. A small chain of lymphatic glands could be felt running along the edge of the pectoral muscle. Axillary glands slightly enlarged and hard.

Digitized by Google

On removing the integuments from the thorax, which was well covered by muscle and abundant fatty tissue, the cicatrix was found to be firmly attached to the ribs, and required to be cut away with some force; it had a yellowish, fibroid appearance, and cut like gristle. The left pleura was found to be free from adhesions, as was also the right, with the exception of one or two firm bands in the upper part. The costal pleura corresponding to the primary growth presented to the naked eye no appearance of change.

The lungs, heart, and pericardium were removed entire.

The bases of the lungs were adherent to the diaphragm so firmly as to be separated with difficulty. The pericardium was adherent to the heart at several points, and the latter was marked here and there by milk spots, which had invaded the muscular tissue. On the external surface of the pericardium over the apex of the heart, to which it was not adherent, was a cancerous-like growth consisting of hard, small, grayish-white nodules and ridges. The auricles were invaded externally by similar growths, having the appearance of "drops of tallow," on the surface. There was a fibroid nodule on one of the corpora arantii of one of the semi-lunar valves of the aorta. Two of the pulmonary valves were semifused The tricuspid and mitral valves were normal, but the endocardium on the auricular surface appeared opaque. Both ventricles were uncontracted.

The lungs appeared to be in a state of inspiration, and had not collapsed. They were of a dirty white colour. The costal pleura was traversed here and there by fine irregular lines, of a yellowish colour, raised above the surface. The margins of the lungs were decidedly emphysematous. On section they showed an apparent general hypertrophy of the connective tissue, and presented a remarkable reticulated appearance, being traversed by fine yellowish-white bands, which marked out the lobules, and in some cases even the air-cells with the greatest distinctness.

The morbid growth appeared to have followed the course of the bronchi, which it had also invaded, and thence spread through the connective tissue of the lungs. On the cut surface numerous small points were seen, having, at first glance, very much the appearance of miliary tubercle. On closer examination, however, they were found to be cut ends of minute bronchial tubes which had become thickened and hardened by having undergone fibro-cancerous change. In each case by gentle pressure frothy fluid could be pressed from their extremities. There was no true solidification of the lungs or

Digitized by Google

general infiltration, except as regarded the free margin of the lower lobes, especially of the right lung, which, on section, presented a general yellowish-white appearance, were firm, and had lost all trace of lung tissue to the naked eye, having very much the look of portions of a cancerous mammary gland. In the upper lobe of the right lung, immediately beneath the pleura, was a solid mass about one inch long and half an inch wide. It was firm and tough, yielded no juice, and resembled fibroid tissue. Extending from this mass were numerous white bands, and the pleura over it was thickened, but not very much so. The lungs contained much air, and floated readily.

Bronchial tubes were dilated, occasionally sacculated, and much thickened by morbid deposit and infiltration.

Bronchial glands contained much pigment, were not enlarged, and were apparently free from disease.

Liver was somewhat enlarged, and presented a nutmeg appearance. There were several hard, whitish masses close to the surface. The largest in the upper portion of the right lobe had, on section, a diameter equal to that of a penny piece. There was but one nodule in the interior of the liver of the size of a hazel-nut, near, but not in connection with, a large branch of the portal vein. It consisted of tough, greyish, fibroid-like tissue.

The supra-renal body of the right side was diseased, its medullary portion having undergone a somewhat similar fibroid change.

The kidneys and spleen were normal, with the exception of dark venous engorgement.

There were a few enlarged, apparently fibro-cancerous glands near the lower omentum, but the mesenteric glands elsewhere were not affected.

The intestines were normal.

The microscopical examination was made by Dr. G. H. Sutton.—The tumour situated in the upper lobe of the right lung consisted of fibro-cellular tissue. A number of corpuscles and nuclei were seen lying in a fibre matrix. The corpuscles varied in size, and were mostly spherical or ovoid in shape. Some of them were irregular in form, apparently due to pressure. There were also some spherical cells which contained distinct but not large nuclei, and some granular matter. The fibre stroma was very abundant in some situations, and it formed the most prominent part of the growth. The fibres were ill-defined, and

Digitized by Google

many of them had large nuclei. In other situations the corpuscles were very numerous, and preponderated over the fibre-like tissue.

A number of corpuscles were seen extending from the part forming the tumour into the interlobular connective tissue, and they were observed very distinctly amongst the elastic fibres forming the alveolar walls of the air-cells.

Sections were made of other parts of the lungs, and examined; but in every section the new fibro-corpuscular growth was seen lying in great quantities around the bronchial tubes and vessels, and it existed in greatest abundance in these situations. In consequence of this the connective-tissue layer around the minute tubes and vessels seemed very much increased.

It was further observed that the new growth had extended from the thickened tissue lying around the tubes and vessels along the minute divisions of the bronchi and vessels into the walls of the air-cells, and in this manner almost the whole of the lung seemed reticulated and mapped out by this new fibro-corpuscular tissue.

WOODCUT 4.

Section of lung showing the fibroid growth.

May 2nd, 1871.

Digitized by Google

Report by the Committee on Morbid Growths on Dr. R. Bennett's case of secondary scirrhus of the lung.—Our examination of the lungs, shown to the Society by Dr. Risdon Bennett, confirms the account which he has furnished of them. The bronchial tubes and pulmonary vessels almost to their smallest ramifications are imbedded in a greater or less abundance of dense white fibrous-looking material; which is, therefore, so arranged that on section of the organs the tissue seems mapped out by it into irregular polygonal spaces.

Under the microscope the adventitious formation is seen to be made up mainly of cells, rounded or polygonal, and for the most part about the size of the cells of the bronchial mucus. These are for the most part collected in the meshes of a fibrous matrix. In some parts the fibrous tissue is predominant; in other parts the cells preponderate, and in places seem to be grouped in loculi of various sizes. We believe that these latter are neither air-cells nor bronchial passages, but the cells of the morbid growth are so like those of the bronchial mucus that it is difficult to be absolutely certain on that point. We distinctly observed (as is described in Dr. Bennett's report) that the cell-growth extended from the seats of its chief development into the tissues separating adjoining air-cells from each other, where it formed rounded excrescences projecting into the cavities of the air-cells, but separated from them by their limiting membrane.

There can be no doubt that the disease was of a malignant character, and little doubt that the growth in the lungs was secondary to that which had existed in the breast.

J. S. Bristowe,
Thos. B. Pick.

---

10. *Peculiar Sputum.*

By Walter Whitehead.

December 9th, 1869.—Mary Ann Lee, out-patient, St. Mary's Hospital, Manchester, æt. 24. Single; leucophlegmatic. Menstruated at 15, always regular as to time; quantity small;

Digitized by Google

colour pale. Never remembers having had any particular illness. Appetite voracious. Very fond of raw meat. Tongue quite clean. Teeth much decayed. Bowels always constipated. Highly nervous, timid and bashful. Suffers from periodic headaches. Complains of shortness of breath, and the rising of large quantities of a substance in her throat, which has continued without interruption since she was seven years of age. No cough. Chest examined carefully without detecting the slightest deviation from the normal condition beyond a slight roughness in the upper part of right bronchus. The expectorated matter she describes as not being coughed up, but raised involuntarily to the upper part of trachea, and then expelled by a peculiar effort described by the term "hawking." This only occurs after eating. Sometimes the pieces are three inches in length, at others mere fragments. They appear thicker at one end than at the other, and the thin end conical, and of a greyish black for a quarter of an inch. One of these masses when put into a six-ounce phial containing water will half fill it. The diameter is usually that of a cedar pencil. None noted to be bifurcated. Rarely complete tubes, although generally curved upon themselves into tubular forms. The microscope reveals a homogeneous basement membrane, studded with epithelial cells. On the 23rd December, 1869, she commenced taking an ounce of the mistura ferri composita, with ten grains of the bromide of potassium, three times a day, and after meals. She has continued taking this mixture to the present time with a gradual decrease in the quantity of mucus secreted, together with a steady improvement in her weight and general health. The amount now expectorated does not equal in a week the quantity previously formed in one day.

From the history, and from the chemical and microscopical examination, I conclude that I may classify the case as an example of the disease which I have recently described under the name of "Mucous Disease;" the same disease which Dr. Andrew Clark described in connection with the colon, in the ninth volume of the 'Transactions of the Pathological Society.' I feel further induced to form this conclusion from the fact of their being similar mucous products, occasionally passed by the bowel and demonstrably from some portion of its course. Consequently, we must attribute to some general cause these formations, and not consider them in the light of a local affection. *January 17th*, 1871.

Digitized by Google

Report of Committee on Mr. Whitehead's specimen of sputa.—The specimen consists of several tenacious gelatinous-looking masses more or less elongated, of ragged outline and non-tubular, and of delicate transparent membranous laminæ, varying in size from that of a minute flake to a square inch, and streaked with irregular reticulations. On microscopic examination, both the membranous portions and the more solid masses are found to consist almost entirely of stratified squamous epithelium; scales arranged in irregular patches in a hyaline or faintly granular glutinous material in which some scales also float freely. Imperfectly fibrillated streaks are also here and there seen studded with nuclei having the characters of mucous corpuscles, and giving a similar reaction with acetic acid. Boiling in dilute caustic soda renders the whole transparent. With the exception of one or two doubtful ciliated epithelium cells detected in one specimen, no elements distinctive of lung tissue or bronchial mucous membrane were discoverable.

The above characters favour the opinion that the specimens consist of mucus yielded by a catarrhal condition of the pharynx or upper part of the œsophagus.

R. Douglas Powell,
Henry Arnott.

January 5th, 1871.

Digitized by Google

III.—DISEASES, ETC., OF THE ORGANS OF CIRCULATION.

1. *Cases of malformation of the heart.*

By T. B. Peacock, M.D.

Case 1.—*Entire obliteration or atresia of the orifice and trunk of the pulmonary artery; cyanosis; death from cancrum oris.*

The subject of this anomaly was an intelligent boy, aged two and a quarter years, under the care of Mr. Croft at St. Thomas's Hospital. It was reported that his mother had experienced great trouble during the whole of her pregnancy, and the child became subject to fits a few days after birth and continued to suffer from them till he was six months old. When seen by Mr. Croft he was somewhat cyanotic, the lips and ends of the fingers being blue. He died of cancrum oris.

The width of the heart was considerably greater than its height, the transverse diameter being 27 French lines (60·75mm., 2·39 Eng. in.), and the vertical only 18 (40·5mm., 1,59 Eng. in.).

The aorta arose further to the right than usual, and, from the absence of the pulmonary artery, its origin was completely exposed at the base of the heart.

The pulmonary artery was entirely obliterated, but existed in the form of an impervious band, extending from the termination of the infundibular portion of the right ventricle to the point where a large vessel given off from the aorta (the ductus arteriosus) divided into the two pulmonary branches. There was a large aperture in the septum of the ventricles, by which the two cavities freely communicated, and the aorta, though in connection with both ventricles, arose in chief part from the right ventricle. The right auricle was large, and the Eustachian valve fully developed. The right auriculo-ventricular aperture was natural, and the sinus of the right ventricle was of large size, and its walls thick and firm, while the infundibular portion, or conus arteriosus, was very imperfectly developed. The foramen ovale was entirely closed. The left auricle and ven-

Digitized by Google

tricle were relatively small, and the walls of the ventricle thin and flaccid. The pulmonary veins entered the auricle as usual. The ascending portion of the aorta was large, and the branches at the arch were irregular. In the situation of the arteria innominata an unusually wide vessel was given off which apparently divided into the right subclavian and two carotid arteries. Immediately beyond that point a comparatively small branch arose which was probably the left subclavian artery. As, however, the heart was only seen after its removal from the body, the precise distribution of these vessels could not be ascertained. At the under part of the arch, about the commencement of its descending portion, a large artery arose and passed to the point of bifurcation of the pulmonary branches, where it was connected with the cord which represented the trunk of the pulmonary artery. This was obviously the ductus arteriosus, and had evidently furnished the supply of blood to the lungs.

This case corresponds in its general features with the majority of instances of atresia of the pulmonary artery which have been placed on record.

1st. As usually obtains, the obliteration of the pulmonary artery had occurred at an early period of fœtal life, before the separation of the ventricular cavities was completed. Of about forty cases of the kind which can be referred to, in not more than eight or nine was the septum of the ventricles found entire. This would appear to indicate that the obstruction in the pulmonary artery generally occurs at a very early period of fœtal life; but it is possible that the comparatively small number of cases in which the septum has been closed may be due to the circulation being less capable of being maintained under these circumstances, and the infant consequently surviving birth only for a short time, so that the condition may escape observation.

2nd. The ductus arteriosus was obviously in this, as in much the largest proportion of cases, the channel through which the blood, which was incapable of passing through the trunk of the pulmonary artery, was transmitted to the pulmonary branches, and was so conveyed to the lungs. It is probably only when, with obliteration or constriction in the pulmonary artery, the ductus arteriosus has also become obstructed, that the supply of blood to the lungs is furnished or supplemented by vessels from some other part of the aorta or from one of its branches.

3rd. The closure of the foramen ovale, which had occurred in

Digitized by Google

this case, though occasionally found in connection with occlusion of the pulmonary artery, when the septum of the ventricles is incomplete, so that the blood can readily pass from the right side of the heart to the left, is certainly not of common occurrence. In cases of atresia, with perfect separation of the ventricular cavities, the foramen ovale necessarily remains open, and forms, indeed, the only means by which the blood returned to the right auricle can be transmitted into the left ventricle and aorta and so to the lungs.[1] It is, however, remarkable how small an aperture has, in some such cases, been found to exist, though generally the foramen is largely open.

4th. It has been thought that cases in which, like the present, the whole trunk of the pulmonary artery is obstructed, are more common than those in which the orifice only of the vessel is impervious, in consequence of the adhesion together of the semi-lunar valves, but this idea does not seem well founded; both forms of obstruction are not of uncommon occurrence.

5th. The age which was attained by this little patient somewhat exceeded the period to which children with atresia of the pulmonary artery usually survive. Of twenty-eight cases referred to in Dr. Peacock's work on 'Malformations of the Heart,' in seven only was life prolonged beyond twelve months, and in two of the cases which have more recently been placed on record in our own transactions, the duration of life was also very limited. In this case the little boy lived to two and a quarter years and then died of a disease only indirectly, if at all, connected with the cardiac defect. Instances in which the subjects survived to much more advanced ages are, however, on record.[2] There is reason to believe that in cases in which the septum of the ventricles is incomplete the duration of life may be more prolonged than in those in which the ventricular cavities are entirely separated. It is obvious that in the former class of case, the facility with which the blood which enters the right auricle can be transmitted to the aorta and so to the lungs, is much greater than in the latter, where the foramen ovale only affords the channel of communication.

6th. Irregularity in the origin of the vessels at the arch is not of uncommon occurrence in cases of malformation of the heart; and the peculiar distribution which probably obtained in this instance

[1] There is, indeed, one case recorded in which the foramen is said to have been closed, but there is reason to doubt whether, in this instance, the pulmonary artery was completely impervious.

[2] See paper by Dr. Peacock in the 'Transactions' for 1868–69, vol. xx, p. 61.

Digitized by Google

is one of the most frequent forms of deviation which are met with in cases in which the heart is quite normal.

CASE 2.—*Great contraction, or stenosis, of the pulmonary artery; defect in the septum of the ventricles, and aorta arising equally from the two cavities; no ductus arteriosus, but that vessel replaced by two small branches connected with the aorta; Cyanosis.*

The subject of this case was a boy, æt. 17, admitted into St. Thomas's Hospital under the care of Dr. Peacock on the 9th of June, 1869. He was of stunted form and high shouldered, and had a slight lateral curvature of the spine. He stated that he had suffered from palpitation of the heart and difficulty of breathing as long as he could recollect. His lips were purple and his cheeks flushed, and his fingers were long and tapering, the ends clubbed and the nails incurvated. The lower extremities were œdematous. There was a systolic murmur heard over the whole præcordia, and loudest at the base and in the course of the aorta and pulmonary artery, especially the latter. There was also a murmur heard with the impulse of the heart at the apex and towards the left axilla, and feebly at the lower angle of the left scapula. A murmur of a different note was also audible towards the end of the sternum, and there was marked pulsation in the jugulars. The respiratory sounds were attended with bronchitic rhonchus, and there were signs of emphysema of the lungs. Shortly after his admission into the hospital he took cold and all his symptoms became aggravated; there were pains and swellings of the joints, and the cyanosis was much more marked. He also suffered from occasional syncopic attacks to which he had, indeed, been subject for the last seven years. He died on the 19th of July.

The *post-mortem* examination took place the following day. The calvaria was very irregular in form, being fuller on one side than on the other. All the organs of the body were very much congested, and the lungs especially so; but, with the exception of the heart, they were otherwise healthy.

The pericardium was healthy. The heart was remarkably altered in form, being considerably wider in the transverse than in the vertical direction. (Plate IV.) The aorta arose further to the right than usual, and its ascending portion was entirely exposed in consequence of the small size of the pulmonary artery. The

Digitized by Google

Digitized by Google

DESCRIPTION OF PLATE IV,

Illustrating Case 2, described in Dr. Peacock's paper on Malformation of Heart (page 88).

A. Probe passed through the orifice of the pulmonary artery, indicating the size of the aperture.

B, B. Compensatory branches from the aorta.

C. Left branch of pulmonary artery, receiving compensatory vessel on that side.

Digitized by Google

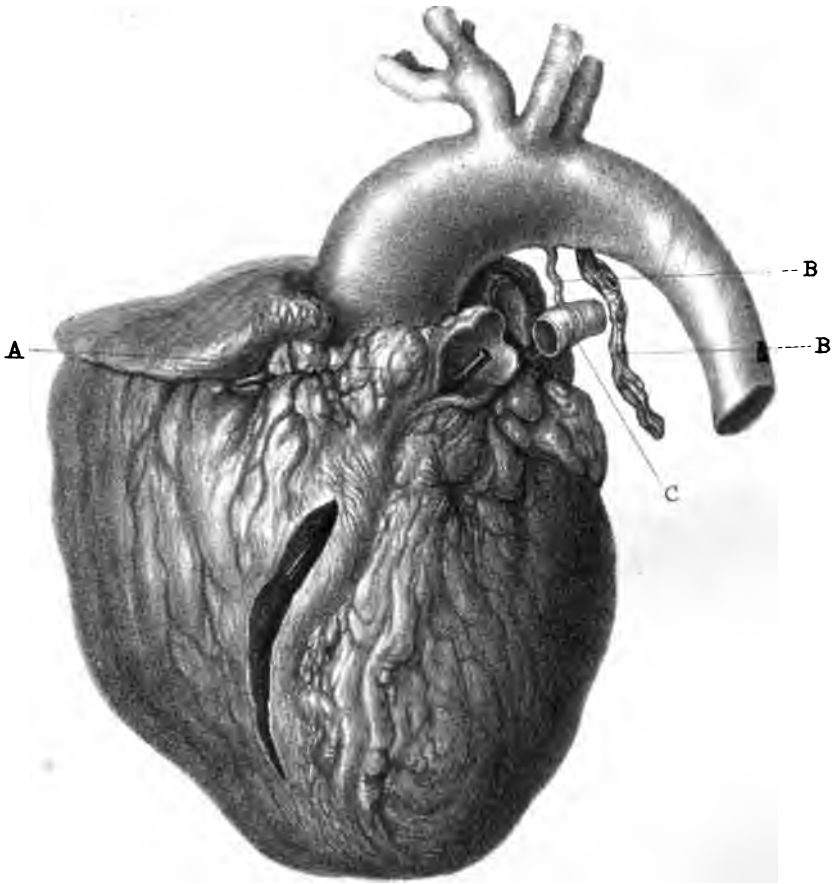

F. Burgess del et lith

W. West & Co. imp

Drawing of Heart, in Dr. Peacock's case, of malformation.

Digitized by Google

Digitized by Google

orifice of the pulmonary artery was very narrow, being only capable of admitting the point of a small blowpipe, or having a circumference of 6·5 Paris lines (14·62 mm., 3·57 Eng. in.). The orifice was provided with only two semilunar valves which were protruded forward so as to leave deep sinuses behind them. After its origin the vessel increased in capacity, but it was still much below the proper size (18 Paris lines, 40·5 mm. 1·59 Eng. in.), and the coats were thin like those of veins. The artery was also very short, not more than half an inch long; it divided into the usual branches, which were also small. The right ventricle, though of large size and its walls thick and firm, consisted almost entirely of the sinus, the cavity in the infundibular portion, or conus arteriosus, being reduced to a mere chink. The right auriculo-ventricular aperture and its valves were healthy; the auricle was very capacious, and the Eustachian valve natural. The left auricle received the pulmonary veins as usual, and the cavity, together with that of the corresponding ventricle, was small relatively to the right cavities; the walls of the ventricle were of natural width, but loose and flaccid. There was a considerable deficiency in the interventricular septum by which the two cavities freely communicated, and the aorta arose above the septum so as to be about equally in connection with the two ventricles. The ascending portion of the aorta was large and the usual branches were given off at the arch. From the under part of the arch, and immediately beyond the point of departure of the left subclavian artery, two vessels were connected with the aorta. The points of origin of these vessels were about half an inch apart. One of them after a short course opened into the left pulmonary artery; while the other, which was much larger, divided into two or three branches which probably entered the right pulmonary artery and lung, but the precise distribution of this vessel could not be traced from the lung having been cut off before the anomaly was detected. These vessels at their point of departure from the aorta were entirely obliterated, but they remained pervious at their distal or pulmonic extremity, and here would admit of the passage of crow quills. There was no trace of the ductus arteriosus in its proper situation. The foramen ovale was closed. The coronary arteries and veins were natural. The secondary branches at the arch displayed some irregularity; the arteria innominata immediately after its origin gave off a small artery, and a large vessel arose close to the origin of the right carotid artery.

Digitized by Google

The weight and dimensions of the heart were as follows:

Weight of heart after being laid open and washed					8½	oz. avoir.
Transverse diameter	48·	Paris lines	=108·	mm.,	4·26	Eng. in.
Vertical „	36·	„	88·	„	3·19	„
Girth of right ventricle	60·	„	135·	„	5·32	„
„ left „	42·	„	94·5	„	3·72	„
Thickness of walls—						
Of right ventricle—near base	3·5	„	7·8	„	·31	„
midpoint	5·5	„	12·3	„	·48	„
near apex	4·5	„	10·1	„	·39	„
Of left ventricle—near base	3·5	„	7·8	„	·31	„
midpoint	5·5	„	12·3	„	·48	„
near apex	2·	„	4·5	„	·17	„
Circumference of right aur. vent. ap.	39·	„	87·7	„	3·46	„
„ left „	36·	„	81·	„	3·19	„
„ pulmonary „	6·5	„	14·6	„	·57	„
„ opening from right vent. into aorta	33·	„	74·25	„	2·93	„
„ opening from left vent. into aorta	33·	„	74·25	„	2·93	„

The weight of the brain was—

The cerebrum	40 ozs.
The cerebellum	5 ozs.
The pons and medulla	1 oz.
The whole encephalon	46 ozs.

1st. The opinion which was formed of the nature of this case during life was confirmed by the post-mortem examination. From the history and general features of the case it was concluded that the disease of the heart was most probably congenital; and from the existence of a murmur heard with the systole and most distinctly audible in the course of the pulmonary artery, it was inferred that there was some source of obstruction at the commencement of that vessel. As also with congenital disease of the pulmonary orifice the septum of the ventricles is very generally found incomplete, it was thought most probable that there was an aperture in the interventricular septum, so that the aorta received blood from both ventricles. This supposition was supported by the fact that the systolic murmur was also distinctly heard in the course of the aorta. It was further concluded from a systolic murmur being loudly heard at the point of pulsation of the apex of the heart, and being propagated towards the left axilla, and feebly heard at the lower angle of the left scapula, that there was some mitral incompetency; and the

Digitized by Google

murmur audible towards the end of the sternum was supposed to be due to tricuspid regurgitation, of which the jugular pulsation afforded evidence. These conclusions were, it will be observed, in accordance with the conditions detected on examination of the heart after death.

2nd. As regards the nature of the malformation, it seems probable that the first deviation from the natural process of development consisted in the irregular evolution of the portion of the bronchial arch which should have formed the ductus arteriosus. Instead of that vessel being of its proper size and occupying its natural position, the two small branches only existed; and thus the trunk of the pulmonary artery, giving passage at the earlier periods of fœtal life to but little more than the blood which was transmitted to the lungs, remained a comparatively small vessel, and did not adequately expand with the progress of growth. Thus also the blood which entered the right ventricle, having no sufficient outlet through the small pulmonary artery, would continue to pass directly into the left ventricle, and so the growth of the interventricular septum would be interfered with, and a permanent communication between the two cavities would remain; the aorta would retain its connection with both ventricles, and its origin might be drawn further to the right than natural.

It seems probable that the two small vessels connected with the aorta and pulmonary artery are not to be regarded as supplementary branches from the aorta, furnishing a supply of blood to the pulmonary artery in compensation for the small size of that vessel. They must rather be considered as the representatives of the ductus arteriosus, fulfilling, though imperfectly, the functions of that vessel during fœtal life, and undergoing an analogous process of contraction and closure when such function was no longer needed.

This appears from the mode in which their obliteration was brought about, the process of closure having commenced at their aortic extremities and gradually advanced towards their pulmonic ends, which, however, were still pervious at the time of the patient's decease. Had the vessels conveyed blood into the pulmonary artery, the process of closure would probably not have taken place at all, or if it had occurred would have commenced at the pulmonic and have extended thence towards the aortic end, the latter portion instead of the former remaining pervious.

The case thus viewed is certainly a very unusual one. Though

Digitized by Google

various instances of malformation in which compensating branches have been given off from the aorta, and others in which the ductus arteriosus has been in different ways irregular, have been placed on record,[1] I know of none which appear to be precisely identical. I may, however, refer to a case published by Dr. Ramsbotham,[2] to two related by Dr. Chevers, which occurred respectively in the practices of Dr. Babington[3] and Dr. Chambers,[4] and to one reported by Dr. Quain and Mr. John Sibbald in our own transactions,[5] as presenting conditions somewhat similar to those which obtained in this case. *October 8th*, 1870.

---

2. *Malformation of the heart; transposition of the great vessels; cyanosis.*

By C. Kelly, M.D.

F. J—, æt. 2 months, was admitted into King's College Hospital under Dr. Priestley on October 10th, 1870. This child had a dark skin when born, but nothing remarkable was noticed until it was five weeks old, when the parents observed the surface of the body was livid and the extremities cold; at this time, also, it began to have fits.

On admission the surface of the body was of a dusky colour, the lips and nails blue, and the extremities cold and livid; he was much more livid when he cried or coughed.

The respiration was hurried, but there were no physical signs indicating disease of the lungs. A loud systolic bruit could be heard nearly all over the thorax, but most distinctly at the apex; the impulse was stronger than usual and occasionally irregular.

[1] See Dr. Peacock's 'Malformations of the Human Heart,' 2nd ed., 1866, pp. 65 and 124.

[2] 'Med and Phys. Journal,' vol. lxi, p. 548, and Dr. Peacock's work, p. 66.

[3] Dr. Chevers's "Collection of Facts illustrative of the Morbid Conditions of the Pulmonary Artery," 'London Medical Gazette,' from July 1846 to September, 1851, reprinted 1851, p. 14.

[4] Ibid., p. 15.

[5] Vol. viii, 1856–57, p. 167.

Digitized by Google

The child generally had a convulsive attack every morning, the face then twitched, the hands and feet were clenched, there was slight foaming at the mouth, and at times a slight squint. The child was rather thin, but it was fed by a bottle soon after birth. There was no rash nor snuffling, nor did the history of the parents give any evidence of a syphilitic taint.

On November 3rd, when a dense fog prevailed, the surface of the body became colder and more livid, and the breathing was much impaired; it lay in a torpid state, having no convulsions the last two days, and died on November 4th.

The mother has had eleven other children, and it is singular that her first child was affected in a similar way; it "became blue at six weeks, and died when five months old." A medical man who examined the body said that the "arteries of the heart were wrongly placed."

A *post-mortem* examination was made twenty-eight hours after death.

Head.—The brain and its membranes were healthy.

Thorax.—No fluid nor adhesions in pleuræ; the lungs were full of air and crepitant throughout.

The heart was lying in its natural position with the apex between the fifth and sixth left costal cartilages. Pericardium normal.

The apex of the heart was formed by the left ventricle, the auricles were seated in their natural position, and there was nothing abnormal in the external appearance of the heart, except the transposition of the great vessels.

The aorta arose from the right ventricle, and at first was therefore anterior and to the right of the pulmonary artery, which sprang from the left ventricle, and, then dividing, sent a branch as usual to each lung.

The innominate was given off as usual, and then divided into the right subclavian and right carotid arteries; the left carotid was not given off from the aortic arch, but from the innominate just at its origin; the left subclavian artery was normal. Uniting the aorta and pulmonary artery was the ductus arteriosus, which was quite closed, and merely a fibrous cord; it was in the ordinary position.

Both ventricles were of about the same size and the wall of the same thickness in each, so that there was really much hypertrophy of the right ventricle; the columnæ corneæ and the musculi papillares were also thickened.

Digitized by Google

Length of each ventricle	= 1·5	inches.
Thickness „ „	= ·14	„
Width of aortic orifice	= 1·38	„
„ pulmonary orifice	= 1·25	„

The ventricular septum was normal.

The auricles were of the usual size and shape; the venæ cavæ opened into the right auricle, and the four pulmonary veins into the left auricle; these cavities communicated by means of a patent foramen ovale large enough to admit a goose quill; this was, in fact, the only way by which venous blood could be oxygenated.

The valves of the heart were healthy.

The bronchial arteries were as usual, and the coronary arteries came off from the aorta.

No other malformation could be found in the body; all the organs were rather full of venous blood, but otherwise healthy.

Remarks.—Over forty cases have been at various times recorded of transposition of the great vessels, but in most there has been some other deficiency either of the heart or in the distribution of the vessels.

A few cases have occurred in which the foramen ovale and ductus arteriosus have remained open, and so allowed a fair communication between the two arterial systems; such a case was brought before this Society by Dr. Ogier Ward in 1851 ('Path. Trans.,' vol. iii, p. 63).

Four only are narrated in which, with the transposition only, an open foramen ovale has been associated; they are mentioned by Dr. Cockle in a paper on the subject in the 'Med. Chir. Trans.,' vol. xlvi, p. 204, 1863.

The symptoms in each case have been very much alike; cyanosis has generally appeared a few weeks after birth and not at first; death has taken place in 15 weeks, 1½ year, 2½ years, and in 2 years and 8 months respectively, in the cases quoted; convulsions are not common, while in the case now recorded they were of daily occurrence. Considering the very small amount of blood which becomes oxygenated in these cases as compared with the amount in a healthy child, it is somewhat remarkable that life should be so long prolonged, whereas in some cases, where the communication between the currents seemed apparently much greater, death has taken place at a much earlier period. *November* 15*th*, 1870.

Digitized by Google

3. *Malformed heart; defective septum ventriculorum.*

By C. Kelly, M.D.

L. B—, æt. 6, was admitted into King's College Hospital under Dr. Priestley, September 26th, 1870, suffering from acute renal disease after scarlet fever. She seemed to have been a healthy child, nor did she suffer markedly from shortness of breath or palpitation; at no time was she cyanotic. When in the ward a loud systolic bruit was heard just to the left of the xyphoid cartilage, and not quite so well at base or apex.

She died of renal dropsy on October 9th, 1870. At the *post-mortem* examination the heart externally seemed healthy, but on opening the ventricles, the septum was found to be deficient above, and there was a small, round, smooth hole there which allowed interchange of blood between the right auricle and the two ventricles. The adjacent portions of the tricuspid and mitral valves were united above. No other malformation was met with.

November 15*th*, 1870.

---

4. *Sacculated aneurism of the arch of the aorta, simulating aneurism of the innominate artery.*

By Christopher Heath.

The patient, John M—, æt. 45, who was by occupation a porter on the London and North Western Railway, was admitted into University College Hospital, on September the 6th, 1870, under the care of Dr. Wilson Fox.

The patient had always been a very healthy man, had served in the cavalry for some years, and had been in India, where he had suffered from ague and soft chancres, but could not remember any other illness. He had only for the last three years been a porter on the railway; was always accustomed to live well, and drank seldom more than about five pints of beer daily.

He lost his voice from a very severe cold about fourteen months

Digitized by Google

ago, but quite recovered from that and felt well until January last, when he noticed a tumour above the sternum, accompanied by pain in the right shoulder and in the right side of the head, while, from time to time, the glands of the neck on the same side were enlarged,

About that time he was seen at University College Hospital by Mr. Marshall, who diagnosed an aneurism of the innominate artery, probably extending to the arch of the aorta, and then he complained of his right arm having received a severe twist as he jumped off a carriage. Under treatment he improved, but did not continue his attendance long, and went on with his work, although warned against doing so, till two months ago, when he caught fresh cold and all the former symptoms returned; and they, by his own account, are always aggravated by exposure to damp.

On admission.—On the right side of the neck there was a swelling occupying the inner half of the clavicle and reaching beyond the notch of the sternum; it extended an inch and a half above the sternum, was hard, resistant, and evidently behind the clavicle, which was flattened out over it, the sterno-clavicular articulation being pushed forwards. There were ecchymoses on the surface. A pulsation weak and indistinct, like an indistinct arterial pulsation, could be felt at any point, but did not appear to push forwards the mass as a whole. There was no thrill or bruit, but a very faint, blowing murmur in the centre of the mass coincident with systole. The *left* radial pulse was imperceptible; the brachial was felt faintly, but much less than the right; the subclavian indistinct. Both jugulars were distended, and a plexus of veins was visible on the right side, but not on the left. The veins of the right arm were fullest, but not very markedly so, than those of the left. Veins were distended in the upper part of right thorax.

Heart.—Apex beat one inch outside nipple, in sixth interspace, and against seventh rib. The impulse diffused and somewhat thrusting, but not visible at epigastrium; no thrill. Systolic sound prolonged and muffled. Diastolic sharp and accentuated; the same at base and apex. No murmur anywhere. Both sounds are heard very plainly in the tumour.

Thorax (on percussion).—There was absolute wooden dulness over the mass and imperfect resonance to first rib, but the remainder of the front was normal. In the back, the upper third of scapular, and interscapular regions of right side was almost absolutely dull; the

Digitized by Google

middle third was deficient, whilst the remainder of the back was good.

On auscultation.—Respiration was suppressed in the right infra-clavicular region; was weak as low as the nipple and in the upper axilla; the remainder of the front was normal. In right supra-spinous fossa in the back the respiration was very weak and blowing; almost bronchial below the spine of the scapula, weak at the level of the angle of the scapula, and below this normal. The respiration was distinctly higher pitched in right supra-spinous fossa than in left. The whole left side was normal. Vocal fremitus and resonance diminished on right side down to third rib, and in supra-spinous fossa; elsewhere normal. No pulsation was *visible* in the back, but was *heard* in right supra-spinous fossa without murmur.

The patient complained of pain in neck, shoulder, and back on right side. Ordered emplast. belladon., 12 inches × 6, to be applied to upper right thorax. Dysphagia and dyspnœa worse at night, when he is also very restless. Ordered chloral. hyd., gr. 15, om. noct. sum. The sight of the right eye is deficient, but this he attributes to a blow. Temperature normal; pulse 84; respiration 32; urine has a specific gravity of 1017; no albumen or sugar.

Dr. Fox considered the aneurism to involve the innominate and aorta, and asked Mr. Heath to see the patient with a view to an operation—the case being evidently urgent.

September 13th.—The pulsation in the tumour was more distinct than on admission, no bruit heard; a sphygmographic tracing was taken from the left wrist, and the pulse was perceptible to the finger. Mr. Heath decided to ligature the subclavian and common carotid on the right side.

14th.—The patient being well under the influence of chloroform, Mr. Heath proceeded to ligature the subclavian in the usual way, but in making the dissection to expose the artery, a vein was opened lying close under the clavicle. Very severe hæmorrhage took place, and several attempts which were made to apply a ligature failed, owing to the deep position under the clavicle of the bleeding point; during the rest of the operation the flow of blood was stopped by the application of digital compression by an assistant. Great difficulty was experienced in finding the artery, as the parts were altered and obscured, and none of the usual guides to the vessel could be felt; but at last, after a tedious dissection, Mr. Heath came upon a pulsating sac in the position of the artery, which appeared to be the

Digitized by Google

aneurism extending much further than was anticipated. Under these circumstances Mr. Heath thought that the application of a ligature would be impossible, and so firmly plugged the wound with lint dipped in Tr. Ferri Perchloridi. A bandage was placed over this, then a folded towel over the wound, and above all another bandage. When put to bed one third of a grain of morphia was given hypodermically.

The patient had passed a good night after the operation, and said that he felt easier than he had for some time.

He went on well until the fourth day, when he was attacked by violent dyspnœa, and in addition there was some coughing if he lay on his back. Patient was most restless, and the pulsation in the aneurism became greatly increased, while the pulse at the right wrist could scarcely be felt. The face became quite livid, and remained so till the end of the attack (about 11 p.m.). Chloroform, and then ether, were given to be inhaled, and after some time afforded slight relief. The feet remained quite warm all the time, and towards the end the patient broke out into a profuse sweat. Ether, with small doses of opium, was administered internally.

On the fifth morning the plug was removed and the wound washed with carbolic lotion. Though very restless the patient seemed better all day, and did not wander at all. About 7 p.m. the wound broke out bleeding, though not in a jet. The poultices were taken away and a plug of lint dipped in Tr. Ferri Perchlor. reapplied, which stopped all hæmorrhage, though about a pint of blood was lost. A bandage was applied tightly over the shoulder.

20th (sixth day).—The patient seemed much weaker this morning and wanders much; could hardly be roused; asked continually for something to drink, preferring water; feet cold, but he was so restless that a hot-water bottle appeared to do no good; he could not keep quiet for a moment. He had no violent attacks of dyspnœa, but got weaker and weaker, and died at 6 p.m.

Post-mortem examination eighteen hours after death.—The body was well nourished, with a fair amount of fat. On raising the sternum the tumour was seen to have eaten away part of the bone and to have dislocated forwards the clavicle. The portion adherent to the sternum was about one inch in circumference. The right clavicle was flattened out, adherent to, and eaten away by the aneurism. The left innominate vein crossed over the front of the tumour. The

Digitized by Google

aorta was greatly enlarged and much diseased. The aneurism, which was found to be a sacculated one of the aorta, sprang from the arch just in front of the innominate artery, which lay quite behind and hidden by the tumour. The left subclavian was found to be obliterated about two inches from the aorta, but the innominate and left carotid were pervious. The right subclavian occupied its usual position, but was completely hidden by a position of the sac, which reached into the posterior triangle, and was the part seen during the operation. It was this which ultimately gave way. The sac was filled by loose coagula, a part of which hung down into the aorta, and from it there was a small clot running up the left carotid.

The heart was hypertrophied and flabby. The lungs congested, but otherwise healthy. Above the clavicle and at the bottom of the wound made at the operation the tumour was found to be open, coagula stopping up the hole in the sac. There were no appearances of pressure on the trachea either externally or internally.

Remarks.—This case is of great interest as bearing upon the question of the treatment of aortic aneurism by the distal ligature, and taken in connection with the case of Julia W—, who survived a double distal ligature for four years (see last volume of 'Path. Trans.'). The patient in the above case was in a highly dangerous state, and might have died at any moment from bursting of the sac. Under these circumstances I had no hesitation in endeavouring to apply a distal ligature to the right subclavian and carotid arteries, believing that the aneurism involved the innominate artery primarily, and from the amount of dulness present, probably extended to the arch of the aorta also. The operation was much embarrassed by the turgid state of the veins, which gave much trouble, and when after careful dissection I reached an obviously pulsating sac in the position of the subclavian artery, I thought it might be an extension of aneurismal disease along the vessel, and could not have anticipated that it would prove to be a portion of the aortic sac. The ultimate bursting of the sac in this position was doubtless hastened by its exposure, and by the application of lint steeped in perchloride of iron to the wound in order to arrest the venous hæmorrhage. There would have been no difficulty in reaching the right common carotid artery, and it is an interesting speculation as to what would have been the result had I happened to have operated on the carotid first.

Digitized by Google

The fact of the *left* subclavian artery being obstructed is an additional point of interest in the case. In vol. ix of the 'Path. Trans.' I have recorded a case of innominate aneurism opening into the trachea, in which the left subclavian was obliterated close to the aorta by old disease, although the pulse at the wrist was apparently normal; and bearing in mind the probability of similar obstruction in the present case, I had some doubts as to whether the right vertebral and left carotid alone would prove sufficient for the nourishment of the brain. Of this Rossi's case of double ligature, where the left vertebral alone proved insufficient, is a good example.

October 18*th*, 1870.

---

5. *Aneurism of the thoracic aorta; cured popliteal aneurism.*

By John Croft.

S. Grose, æt. 40, a plumber, was admitted into St. Thomas's Hospital on the 22nd February, 1870, under my care, for popliteal aneurism on the right side. The tumour measured three inches in length, and two and a half in breadth. The man had noticed it soon after jumping and heavy walking during a shooting excursion. Flexion treatment was tried without success, and was changed on the third day for continuous instrumental compression. In thirty hours the pulsation had quite ceased, and two hours after, the pressure was discontinued. On the sixteenth day he was well enough to leave the hospital. Seven months after this he returned to consult me about a pain in his chest and symptoms of indigestion. At my request Dr. Stone took charge of him, but though aware of the previous history, after careful examination could not discover signs of cardiac or aortic disease. He attended amongst Dr. Stone's out-patients, seeming constantly anxious and distressed. He complained of pain in his chest, and a fortnight later spat up about an ounce of blood. Soon after, on the same afternoon, he coughed up or vomited a large quantity of blood, and suddenly died. Dr. Stone made a *post-mortem* examination. The *heart* was healthy. The *left lung* was in many places tied down by

Digitized by Google

old adhesions, but between it and the thoracic wall was a collection of about two pints of blood. On separating the lung from the back of the chest, a small aneurismal cavity was broken into. The parts involved in the disease were removed, and they consisted of the aorta, the left lung, and the œsophagus.

The aorta, when cut open, showed an orifice in its anterior wall nearly as large as a florin, opposite the root of the lung; this led into an aneurismal sac, capable of holding a walnut. The sac had a diverticulum. It did not communicate with the œsophagus. By folding the aorta and the lung together, it was seen that the aneurism was shut up between the two. The posterior surface of the lung, especially near its root, was rough, stained with blood, and had a lacerated appearance. On section, that part showed a firm consistence, as if infiltrated with blood. The bronchi had been cut off short.

It appeared probable that the hæmorrhage from the mouth, amounting to about half a pint in all, had found its way through the laceration in the lung.

Dr. Stone dissected out the popliteal artery and aneurism. The sac, as large as a walnut, was situated a little below the middle of the artery, and had been formed on its posterior aspect. Water injected at one end escaped in a small stream at the opposite. When laid open, the interior of the sac was shown to be filled with a firm, partly laminated clot, which still retained a good deal of bright colouring matter. A channel existed between the clot and the anterior wall of the vessel. It was about the size of a crow quill. The only similar case in the 'Transactions' is described by Dr. R. D. Powell in vol. xx, at page 119. In that case the aneurism had been cured; no pulsation could be felt, and the canal was pervious as in the case I have recorded. *January* 3, 1871.

Digitized by Google

6. *Aneurism of the arch of the aorta bursting into the œsophagus.*

By C. Theodore Williams, M.D.

T. H., æt. 38, a labourer, was admitted into the Brompton Hospital under the care of Dr. Quain, December 7th, 1870, complaining of pain in both sides of the chest, extending down the left arm, of dyspnœa, and of increasing weakness. He stated that he never remembered having strained himself severely on any occasion, but that when he was eighteen he had overworked himself, being at that time engaged in loading carts with clay; five years ago he worked as a navvy in the London Docks, and was employed for nineteen hours out of the twenty-four. Eighteen months ago he lost his voice, according to his own account, from a cold, but regained it to some extent afterwards, though at the time of admission it was husky; nine months ago he began to suffer from dyspnœa, and severe pain in the upper left chest, chiefly in the scapular region, which always became worse towards night, or after exertion, but he continued at work till five months later, when the increasing pain and dyspnœa forced him to desist. He had never had dysphagia. Three months ago he had inflammation of the left lung from which he soon recovered. When admitted he had a slight cough, with expectoration occasionally streaked with blood. Dr. Quain, on examining him found the pulse scarcely perceptible, either in the left brachial or radial arteries, but in the right radial it was 102 regular. The left arm was colder than the right; the superficial veins in the upper part of the chest very prominent, and the left side immobile. There was marked dulness in the upper parts of left chest, between the sternum and the angle of the scapula, and over this space the heart sounds were very audible. Tubular sounds were detected above the left scapula. A murmur was heard in the upper parts of the chest, in the carotids, and along the spinal column in the tract of the aorta; it was loudest at the second costo-sternal articulation, and here it was double. Dr. Quain's diagnosis was "aneurism of the transverse and descending portions of the aortic arch." I saw T. H. in Dr. Quain's absence on December 23rd, and found, on examination, that, in addition to the above physical signs, the dulness extended over the whole upper half of the left chest, anteriorly and posteriorly, the breathing was

Digitized by Google

tracheal near the second costo-sternal articulation; the left radial and brachial pulses were imperceptible, but the right radial was 102, regular and weak, and gave the sphygmographic tracings here exhibited, in No. 1 the pressure used being 70 grammes, in No. 2

WOODCUT 5.

No. 1.

No. 2.

333 grammes. The cough had a laryngeal and stridulous character; the temperature of the right axilla was 98·8, and of the left 98·7; the pupils were irregular in size, the left being most dilated. On the 16th of January some pulsation was noticed in the first intercostal space. On the 26th, when at tea, he had an attack of dysphagia, and was nearly choked, suffering from severe pain for some time afterwards. On the 28th the dysphagia still continued; he was only able to swallow liquids. At this time he was confined entirely to the ward. On the 6th February Mr. D. Giffard, the clinical assistant, found the temperature of the right axilla to be 98·6; that of the left 99·6, showing a difference of one degree; and the pulse 90. On the 8th of February, when at the water closet he had a severe fit of dyspnœa and faintness, and after this grew rapidly worse, the pain becoming more severe, experienced chiefly in the right side of the chest in the mammary and interscapular regions; this was relieved by Mr. Giffard's injecting morphia from time to time, and the patient was able to obtain four or five hours' sleep. The dysphagia continued, and on the 19th, on attempting to get out of bed he vomited a pint or more of blood and expired.

On *post-mortem* examination, the mouth was found full of blood, as also the stomach, the blood in the latter being tarry in appearance. An extensive aneurism, the size of two clenched fists placed together, involved the transverse and descending portions of the aortic arch. The pouch was directed chiefly downwards and forwards, and had exercised great pressure on the left lung, which was adherent to it. Posteriorly it had pressed on and opened into the œsophagus,

Digitized by Google

the erosion being about the size of a sixpence, and having a sharp well-defined edge. The aneurism contained a large, firm, fibrinous clot, which could be easily detached from the wall. The left subclavian artery was blocked up, but the other vessels arising from the transverse aorta were pervious. The heart was healthy. The aorta contained large patches of atheroma. Both lungs were healthy, but the left was much compressed, the pleura being adherent.

Remarks.—Aneurisms of the arch of the aorta bursting into the œsophagus are by no means rare, the 'Transactions' containing six instances; but in few of these, as far as can be judged by the reports, was the disease diagnosed during life. The present case much resembles one recorded by Dr. Quain in vol. xvii, where, although the tumour was much smaller, only involving the descending portion of the arch and giving rise to but slight symptoms, it was detected by the physical signs two days before the death of the patient. The chief points of interest are: 1stly, The early diagnosis of the aneurism, which Dr. Quain was able to arrive at two and a half months before the fatal issue. 2ndly, The rapid increase of the aneurism in a posterior direction, and the consequent dysphagia, after it had already extended to some distance anteriorly and downwards, and had caused dyspnœa by pressure on the lung.

March 7th, 1871.

---

7. *Aneurism of abdominal aorta which had burst behind the peritoneum and subsequently into the peritoneal cavity.*

By H. Morris, for Mr. Shout, of Petworth.

Frederick F—, æt. 41, a retired soldier and, of late years, a painter, was admitted into the Petworth workhouse infirmary, under Mr. Shout, on November 4th, 1870, for great weakness in his legs, constipation, a blue line along the gums which were very anæmic, and for pain at the epigastrium of a colicky character, and

Digitized by Google

frequent feeling of sickness. At Christmas there was a small pulsatile tumour, which had been noticed soon after his admission, expanding in every direction, of the size of an egg, situated between the umbilicus and the point of the xiphoid cartilage. No bruit could be heard at the heart, over the tumour or in the back; he was losing flesh rapidly.

On January 7th the tumour had increased, was of the size of an orange as seen from the front, and distinct pulsation could be felt to the right of the spinal column in the lower dorsal region.

On January 30th the patient suddenly became very faint and was supposed to be dying, and a few hours afterwards the tumour was found to be considerably increased.

On February 18th it occupied the whole right half of the abdomen, and bulged into the right lumbar region, where the skin was very thin, deep red, and glistening. [This was at a point three inches to the right of the spinous processes.] Pulsation could everywhere over this side of the abdomen be seen and felt. The man lay on his left side with his thighs drawn up, he feared to move, was in great pain, and extremely emaciated. The tumour continued slowly to increase, and he died suddenly on the morning of March 1st.

Post-mortem examination thirty hours after death.—Body remarkably emaciated. On opening the abdomen a layer of dark clot was seen to form a sheeting over the omentum and viscera. The intestines were pushed over to the left side and into the pelvis, the stomach was below the umbilicus and the liver displaced downwards and to the left, adherent to the false sac of the aneurism. A large tumour, ten inches in its vertical diameter, occupied the whole right half of the abdomen, and bulged forward so as to be adherent, over a large surface, to the peritoneum lining the front and lateral walls of the abdomen. It extended into the right iliac fossa, where the cæcum and ascending colon were firmly bound down to it. Just above this spot was a ragged opening, with soft dark blood-clot around its margin. On laying open the tumour 2 lbs. 14 oz. of clot (some old, decolourized, and in laminæ, and others soft and dark) were removed from a cavity limited by skin behind, and the detached peritoneum and other structures in front. The kidney, its capsule and the vena cava, were pushed far forwards so as to form part of the front limit of the cavity. The aorta opened into this space by a large oval-shaped orifice on its posterior aspect 2 × 1 inch in size. This was

Digitized by Google

situated just above the position of the cæliac axis, and between the lower ends of the pillars of the diaphragm. The bodies of the tenth, eleventh, and twelfth dorsal vertebræ, and the first lumbar vertebræ were extensively carious, as were the right and anterior surfaces of the left transverse processes. All the muscles in the right lumbar region were destroyed.

The heart was normal—the aorta slightly atheromatous at the arch, and a thin depressed and transparent spot, the size of a threepenny piece, was seen on the posterior surface of the arch at the base of the large vessels extending from it.

The organs were healthy, no evidence of syphilis existed anywhere.

Remarks.—A similar case is recorded at page 80 in the first volume of the 'Transactions' of the Society, in which the left lumbar region was occupied by the tumour, and the left kidney was displaced much as the right one was in this instance.

Pathologically, perhaps, this case has no feature of special interest peculiar to it. The aneurism originally, no doubt, was formed by a simple dilatation posteriorly of all the coats of the aorta, for the inner coat is seen to pass over the edge of the orifice in the vessel and to be lost some distance off in the walls of the large tumour.

The clinical points of interest were the extreme emaciation, and the absence of all œdema of the lower extremities. The former condition was due probably to pressure on the thoracic duct, lying, as it does, in close proximity to and on the right of the aorta, or to pressure upon the great sympathetic nerve. The absence of the œdema, to the fact that the vena cava was tilted forwards and lay in the front wall of the tumour, and so had gradually adapted itself to the altered position of parts. *March 7th,* 1871.

---

8. *Aneurism of the coronary artery.*

By Edwards Crisp, M.D.

The subject of the following case was a man 63 years of age, by trade a carpenter; he was a thin spare man, who, in his youth, was intemperate and rather a hard drinker, but of late years he has

Digitized by Google

been more moderate in his habits, and sober. Twenty years since, 1851, he was upset in a boat on the Thames and nearly drowned, having been resuscitated with great difficulty. For a long time he felt the effects of this immersion; he had palpitation of the heart when excited or when he took violent exercise. Three years since he fell from a scaffold and was much contused, but after a few months he apparently recovered from this accident. He had a narrow, prominent chest—was what is called "pigeon-breasted."

On the 7th of December, 1870, I first saw him in consequence of his having lost a quantity of blood from the mouth; the bleeding had continued for two days, and it was said "that he had lost three quarts of blood." I saw about two quarts which had passed from the mouth the second day, and the hæmorrhage continued in smaller quantities for several days, so that he must have lost eight pints of blood. The pulse was imperceptible, the breathing faint, the face pallid and anxious, and the extremities cold. At first sight I thought the blood was probably from an aneurism that opened either into the trachea or œsophagus. I soon, however, altered my opinion. There was so stethoscopic signs of blood in the air tubes, and the large dark coagula soon satisfied me that it came from the stomach, probably from the opening of an artery in a chronic ulcer. Large doses of acetate of lead with a quarter of a grain of opium were given every four hours, and to my surprise the bleeding gradually ceased, and in about six weeks the patient was able to leave his bed.

As the strength improved the stethoscopic signs were more marked; the lung sounds were nearly natural; there was sometimes a slight bellows sound over the base of the heart. I did not suspect the presence of aneurism, but thought that the aortic valves were slightly diseased.

On the 29th of March, 1871, about three and a half months from the first attack of bleeding, he went out for the purpose of doing some carpenters' work, and, after drinking a glass of gin, he fell and died instantly.

I examined the body with Mr. Thurston, of Chelsea (who was called in to see him when he died), on the morning after his death; and, as the coroner's jury were waiting to hear the result, the inspection was necessarily a hurried one. The pericardium was distended with blood which passed from a small orifice which, at first sight, appeared to be at the root of the aorta. The pleuræ were

Digitized by Google

adherent on several parts on both sides; the substance of the lungs was tolerably healthy and that of the liver also, although from the cause already named these organs were not so carefully examined as they should have been. The lining membrane of the stomach was very minutely inspected, and no ulceration or orifice of any kind could be detected. Other parts not examined. The heart was removed and a very careful inspection made. It weighed 14¾ oz., its substance generally in a state of fatty degeneration. The aortic and pulmonary semilunar valves free from disease, as were the mitral and tricuspid. The arch of the aorta contained a small portion of atheromatous deposit. A small tumour was present at the root of the aorta between it and the inner part of the right auricular appendix; at the inner and lower part of this swelling was a very small valvular opening through which the blood had passed into the pericardium. On tracing the right coronary artery the tumour was seen to be occasioned by an aneurismal dilatation (see Plate B) about the size of a small walnut at the commencement of the first branch of the main trunk of the artery, situated about three quarters of an inch from its origin, and passing backwards between the root of the aorta and the auricular appendix. The sac contained adherent coagula; its walls were very thin. The coats of the main artery near to the aneurism were atheromatous, but not to a great extent. All the larger branches of both coronary arteries were opened, and a few patches of atheroma were found in them; but taking the age of the patient into account, there was probably less disease of the coronary arteries than is generally found in men at this period of life.

Remarks.—Irrespective of the rarity of this aneurism, there are many circumstances connected with the case of practical value. Where did the large amount of blood come from at the period when I first saw the patient? I still believe, from the stomach, although no lesion perceptible to the naked eye was found. Mr. Sidney Jones has directed my attention to a preparation in the St. Thomas's Hospital Museum of the stomach of a man who died of fatal hæmorrhage from the stomach, and where the origin of this hæmorrhage was only discovered by injecting the gastric arteries with water, when the orifice was readily seen.

Another interesting question is, as to the cause of this aneurism? I am inclined to believe that the long immersion under water (twenty

Digitized by Google

years before death) might have been the origin of the arterial fracture, and I take credit to myself for having been the first to direct the attention of the profession to the influence of mechanical causes in the production of aneurism. I may mention another important fact to show the progress made in pathology during the last thirty years, and of the value of statistics in all pathological investigations. Lænnec never met with a case of rupture of an aneurism into the pericardium. Hodgson alludes only to two cases, and Hope said "that it was very rare." In my work on 'The Diseases of the Blood-vessels,' 1848, p. 134, of 98 cases of aneurism of the ascending aorta 30 opened into the pericardium. In the appendix to this work, 1851, the number was increased to 134, and 43 of these burst into the pericardium, so that this termination of thoracic aneurism, formerly thought to be so rare, is proved to be the most frequent.

Dr. Peacock, in the first volume of our 'Transactions,' p. 227, related a case of aneurism of the coronary artery, and at that time he thought the example to be almost unique. I have formed the subjoined table of cases that I have met with in various museums, and in the works of different authors. I have not had time to consult many foreign journals, or the number of cases might have been somewhat increased.

Reference.	Sex.	Age.	Occupation, &c.	Pathology, &c.
London Path. Trans., vol. i, p. 227 (Dr. Peacock)	M.	51	Butcher; intemperate; famed for carrying heavy weights	Aneurism of left coronary artery, size of pigeon's egg; contained laminated coagula; artery above ossified; cylinder of bone; a peculiar flipping sound over the heart; death from bronchitis. Weight of heart 13 oz.
Vol. vii, p. 98 (Dr. Bristowe)	M.	22	Sailor	Aneurismal dilations of the coronary arteries, from the size of a pea to that of a tare; some contained adherent clot; no atheroma on the undilated portions of the arteries, and the arterial system generally healthy; fever; paraplegia; death from exhaustion. No peculiar sound observed.

Digitized by Google

Reference.	Sex.	Age.	Occupation, &c.	Pathology, &c.
Vol. viii, p. 134 (Dr. O. Ward)	M.	38	Labourer; subject to rheumatic gout; no symptom referable to the heart	At the base of the aortic convexity, artery dilated into a pouch; at the place of the right coronary an irregular roundish opening the size of a sixpence led to a cavity that would hold a walnut; a minute ulcerated opening into the pericardium; gradual hæmorrhage; death in fifteen minutes.
Dr. Crisp, Dis. & Inj. of Blood-Vessels, p. 21	F.	69	...	Mouths of coronary arteries so much dilated as to resemble small aneurisms.
Dr. Crisp; case above cited	M.	63	Carpenter	Branch of right coronary opened into the pericardium.
Chatham Museum Catalogue, p. 33, prep. 258 (Dr. Stevenson)	M.	...	Soldier	Size of a walnut; above aortic semilunar valves involving the right coronary artery; burst into pericardium.
St. Bartholomew's Hosp. Mus.	M.	11	...	Several small aneurisms of the coronary artery.
Dr. Ogle; St. George's Hosp. Reports, vol ii, p. 285	M.	26	Blacksmith; subject to rheumatism	Stertorous breathing; death not very sudden; left coronary artery pouch the size of a pea with laminated clot; second pouch rather larger in branch of right coronary with fibrinous clot; a third aneurism without clot, the size of a cobnut; rupture into pericardium.
M. Bougon; Bib. Médicale, vol. xxxvii, 1812	M.	...	Old soldier; intemperate; severe domestic distress	Severe pains in chest and back, with sense of suffocation; the right coronary artery aneurismal an inch from its origin; rupture into the pericardium.
M. Peste, 1843; Archiv Gén. de Médicine, tom. ii, p. 274	M.	77	Currier; temperate; had an attack of apoplexy two years before his death	Small aneurism near to the origin of the left coronary artery; rupture into the pericardium.
Otto; Compend. of Compar. Anat., p. 319; trans. by South	M.	40	...	Aneurism of coronary artery burst into pericardium.
Merat; Art. Cœur Dict. de Sc. Med., t. v, p. 484	M.	...	...	Pouch in the coronary artery the size of a large nut; no cardiac symptoms, and death not caused by the aneurism.

Digitized by Google

The last four cases are quoted by Dr. Peacock in the 'Monthly Journal of Medical Science,' 1849, in his paper on Aneurism of the Coronary Artery.

It will be seen that, excluding my first case, which can scarcely be called one of genuine aneurism, all the eleven subjects of this lesion were males, and that in seven examples the aneurism ruptured into the pericardium. I find also a few cases of aneurism of the ascending aorta involving this artery, but in the cases quoted the dilatation was confined to the cardiac artery. As might be expected, in no instance was the presence of this aneurism suspected during life. The supposed aneurism of the coronary artery in St. Bartholomew's Hospital Museum was shown by Dr. Thurnham (as quoted by Dr. Peacock) to be an aneurism of the sinus of Valsalva. *April* 18*th*, 1871.

---

9. *Double subclavio-axillary aneurism; ligature of the subclavian on the right side; death from double bronchitis and pulmonary congestion.*

By John Gay.

The patient, W. B., was admitted into the Great Northern Hospital on the 15th February for a double subclavio-axillary aneurism. He was forty-five years old; had been a sailor, but, for the last few years, a horse keeper at a brewery, and accustomed to lift heavy weights. In August last he felt pain in his right shoulder; but it was not until January that it was discovered by Dr. Simpson, of City Road, to whom he applied for advice, that he had the aneurismal tumours referred to. On admission the tumours had attained a considerable size; that on the right side lay upon the first, second, and third ribs, and projected up behind the clavicle to within a very short distance of the anterior edge of the scalenus. It was very painful on pressure, had a loud bruit and caused considerable pain and numbness in the arm and hand. The tips of the fingers were clubbed and the nails incurvated. The tumour on the left side was not so large,

Digitized by Google

and the pulsation was unaccompanied by bruit; neither was there any pain or numbness in the arm and hand on that side. The patient was robust and florid, and had a remarkably short and thick neck. On admission he had a severe attack of bronchitis on the right side, with dyspnœa. As soon as this, with the excited state of his circulation which coexisted with it, had subsided, and his general health had been improved by rest and treatment, I tied the subclavian on the right side behind the anterior edge of the scalenus.

The patient went on remarkably well for a fortnight. The ligatures on the smaller vessels had come away, and the wound had healed, all but the final act of cicatrization, when on the fifteenth day from that on which the operation was performed symptoms of acute bronchitis reappeared on both sides of the chest. These became very severe; pulmonary congestion set in, the temperature of the body rose to 108°, and the patient died on the 16th of April. The accession of this attack did not appear in any way connected with the operation or any of its consequences.

The *post-mortem* examination showed a large aneurismal sac on the right side communicating with the artery at the point where it passed over the lower edge of the first rib. It was surrounded by the axillary plexus of nerves, whilst the vein lay to its inner side. The sac was filled with firm clot, and so were the main arteries below it, from the seat of the ligature to the wrist. There had been no return of pulsation in these vessels. There was a firm clot in the artery, also on the proximal side of the ligature; whilst, at the seat of the ligature, the vessel had been almost completely divided. A portion of the clavicle, and of the first, second, and third ribs, over and underlying the aneurismal sac had been absorbed. The continuity of the ribs had thus been destroyed.

The aneurism on the left side was in situation somewhat below that of the right, and in character essentially *fusiform*. The aorta innominata, and left subclavian arteries were extensively atheromatous; but the only disease on the right subclavian was that corresponding with the neck of the aneurismal sac. The lungs throughout were severely congested, and the air-cells filled with frothy fluid. The bronchial tubes were intensely inflamed, and bore marks of having been long subject to chronic disease, especially those on the right side. There were pleuritic adhesions also on this side, and beneath the aneurismal sac the pleura pulmonalis had undergone considerable thickening. *May* 2, 1871.

Digitized by Google

10. *Dissecting aneurism of the first portion of the arch of the aorta.*

By T. Whipham, M.B.

The specimen exhibited to the Society was removed from the body of John D., aet. 39, who was admitted into St. George's Hospital, under the care of Dr. Wadham, on February 1, 1871, with pain in the epigastrium and other symptoms, which were at first attributed to dyspepsia. He states that he had been attacked with the above symptoms at Christmas, 1870; that since that time the abdominal pain had become severe, and further that he had suffered from constipation. His pulse on admission was 90, and as no note was made as to its character it may be concluded that there was nothing extraordinary in the pulsations; no abnormal impulse was detected in the heart; the secretions were natural. Though he complained of considerable pain in the epigastrium, no abdominal tenderness existed. With a view of alleviating the supposed dyspeptic symptoms, he was treated with hydrocyanic acid and soda; but failing to derive benefit from these, a mixture of bismuth and carbonate of magnesia was substituted, without any improvement in his condition. Eventually it was thought better that he should leave the hospital for change of air, and on February 15th, the day fixed for his discharge, Dr. Jones, the resident medical officer, noticed that the man looked very ill, and directed him to go back to bed. The heart was then carefully examined, and a systolic bruit audible all over the chest was detected; but it was found impossible to localise the murmur. No increased impulse was perceptible. In the night the patient left his bed and went to the closet, where he was violently sick. Brandy and digitalis were administered, but the vomiting remained uncontrolled, and continued incessantly until his death at 1 a.m., February 16th.

At the examination of the body thirty-seven hours after death, the external appearances were natural. Firm pleural adhesions were found at the left apex. There was extreme vascularity of the bronchial mucous membrane, and much hard inflammatory œdema affecting both lungs. The ventricles of the heart were slightly

Digitized by Google

contracted: the valves and muscular tissue were healthy, but the right side of the organ was very considerably dilated. An aneurism of the dissecting variety, rather larger than a turkey's egg, was found connected with the first portion of the arch of the aorta. It originated in the anterior wall of the vessel, immediately above the valves, and was due to rupture of the middle and internal coats of the artery. The outer coat had then been gradually dissected from the subjacent coverings and a somewhat unusual condition of parts produced. The dissecting process had extended laterally, so that half the anterior wall had been denuded of its outer coat, and upwards for rather more than half an inch. The result of this was, that the portion of the aorta thus stripped of its outer covering lay in the aneurismal sac, and therefore in contact with the blood. The anterior wall of the artery immediately above the valves, for the space of an inch and a half, was wanting (the blood being contained in the dilated outer coat); thus a free edge, rounded, puckered, and evidently of considerable standing, was left dividing the current of blood, expelled from the ventricle to two, one of which was diverted into the aneurismal sac; the other followed the natural course of the circulation, through the transverse portion of the aortic arch. The inside of the sac was rough and blood-stained, and in many places calcareous plates were found in its walls; but around the aorta, where the dissection was most recent, the inner surface, though somewhat rugose, as if from tension, was comparatively smooth and glistening. The walls of the aneurism varied considerably in thickness, and in one place, where it lay in close proximity to the pulmonary artery, it was so thin that, in spite of careful handling at the *post-mortem* examination, rupture took place, causing a communication with the vessel. The aneurism was almost entirely enclosed within the pericardium. The abdominal organs, were congested, and in addition to this the kidneys were granular, with scattered cysts in the cortical parts and fatty epithelium in the tubes.

This case is a good illustration of the truth of Sir Thomas Watson's remark, that, "when aneurismal pouches form, as they often do, at the very entrance of the aorta, . . they often defy detection;" and also of the difficulty, so frequently experienced, in distinguishing between the murmur in an aneurism of the aorta and that arising from valvular disease. There was no impulse, no thoracic pain, no irregularity of the pulse, and the existence of an aneurism was

Digitized by Google

entirely unsuspected. The dyspeptic symptoms were throughout the most prominent feature in the case, and had existed for a considerable time; the man had been an out-patient at another hospital previously to his admission into St. George's, where he had been treated, according to his own account, for indigestion.

The position of an aneurism so close to the aortic valves naturally increased the difficulty of distinguishing the bruit dependent upon it from an ordinary obstructive aortic murmur, and the fact of the free puckered edge of a portion of the aortic walls, being directly opposed to the current of blood, leaving the ventricle, would in all probability produce a sound which it would be impossible, or at all events extremely difficult to distinguish from that of aortic obstruction,

March 7th, 1871.

---

11. *Rupture of aorta; tumour of brain.*

By John Hawkes, M.D.

The specimen consists of diseased heart and aorta, the latter ruptured near its base into the sac of the pericardium. The patient from whose body this specimen has been taken died in the asylum on the 6th inst. He was subject to mania with epilepsy; he also suffered much at times from symptoms of rheumatic gout in his hands and feet. On the morning of the 6th he was observed to be unusually pale; he complained of great uneasiness in the region of the heart and distress of breathing, but was able to walk about the ward. Some medicine was prescribed for the above symptoms (he had just recovered from one of his periodical attacks of gout), and the patient was transferred to the infirmary. About 10 p.m. of the same day he became suddenly worse, and almost immediately expired. The *post-mortem* examination disclosed the subjoined appearances:—Body well nourished; brain forty-eight ounces, softer than normal, and pale throughout. The remains of an extensive old apoplectic clot in the posterior lobe, left cerebral hemisphere, on its outer and

Digitized by Google

under surface. A tumour (enclosed), the size of a pigeon's egg, apparently of a calcareous nature, and emitting when punctured a copious stream of clear fluid with abundance of cholesterine, situated in the left corpus striatum to the outer side of the lateral ventricle; this tumour was supplied by an artery the size of a crow quill, the walls of which vessel were atheromatous. Considerable amount of serous fluid in the lateral ventricles. Pericardium distended by a clot, from which the serum had separated; the clot weighed twenty-two ounces. Heart much hypertrophied; weighed twenty-seven ounces. Aorta considerably dilated and the valves greatly stretched; the rupture rather above the commencement of the aorta, and about half an inch in length. The walls of the vessel separated by the effused blood forming a dissecting aneurism for a short distance on each side. Liver enlarged; seventy-two ounces. Kidneys in the condition of granular degeneration. Spleen much increased in size.

March 7th, 1871.

Report of Committee on Dr. Hawkes' case of tumour of the brain.—We find that the tumour submitted to us for examination is an irregularly lobulated mass, having the shape of a flattened sphere, the diameters of which are rather more and rather less than an inch respectively. It consists of a cyst, now empty, the outside of which is in close relation with those arteries of the circle of Willis which are derived from the left carotid. A large vessel, apparently the middle cerebral, is for the distance of an inch adherent to the outside of the mass, while a small artery, corresponding in position with the anterior cerebral, passes in contact with the cyst for about a quarter of an inch, and then is lost upon its wall, the outer coat of the vessel blending with the external layers of the cyst-wall, and its canal becoming there obliterated. The wall of the cyst consists of firm, old fibrous tissue, the inner layers of which form a distinct lining membrane, having its general smoothness interrupted by hard irregular masses of cretaceous matter imbedded in it, some of which also project into the cavity. These masses consist of granular amorphous matter, yielding bubbles when treated with hydrochloric acid, mixed with plates of cholesterine and bright red masses of hæmatine.

The presence of hæmatine in the calcareously degenerated cyst-wall suggests that the cavity formerly contained blood. The question which next arises is, whether the blood was extravasated or was contained in an aneurismal sac, of which the cyst under considera-

Digitized by Google

tion is the remnant. The intimate relation of the cyst with large arteries, one of which becomes lost on its exterior, is in favour of its aneurismal origin, as also is its position in the subarachnoid space; since an effusion of blood in this situation could not have been circumscribed so as to have formed a cyst, but must have been extensively spread over the base of the brain.

We therefore conclude that the cyst which has been described originated in an aneurism of one of the arteries at the base of the brain.

W. Howship Dickinson.
March 21*st*, 1871. R. Douglas Powell.

---

12. *A case of pleurisy with hæmothorax, complicated by ulceration of the tricuspid valve, and consequent destruction of many of the chordæ tendineæ.*

By T. Whipham, M.B.

The heart only in this case was exhibited; it was taken from the body of Richard R—, æt. 55, a butler, who was admitted into St. George's Hospital under Dr. Wadham's care on June 28th, 1870, complaining of severe pain in the right side. The man was so ill that only a short and imperfect history of his case could be obtained. It appeared that he had enjoyed good health until five weeks previous to his admission, when he was attacked with pain in the right side of the chest, and suffered also from occasional hæmoptysis. The blood-spitting became more frequent and, at the same time, more copious, and when he entered the hospital this last symptom was especially urgent. Owing to his debilitated condition a superficial examination merely was made, when it was found that the right chest, over the base of the lung, was extremely dull on percussion, that the voice sound was increased, and that fine crepitation was distinctly audible. He gradually became worse, and on the day preceding his

Digitized by Google

death delirium set in, and the skin of the whole body assumed a deep sallow hue. The respirations became shallow—66 in the minute—loud râles were heard all over the chest, and the sputa consisted almost entirely of blood.

Examination of the body fourteen hours and three quarters after death.—The body was fairly nourished; the skin of deep sallow colour. On both sides of the thoracic cavity were old pleural adhesions, and in the right chest was a large quantity of bloody turbid fluid, while the pleura itself was here and there coated with a thick layer of soft lymph. In the apex of the right lung were found some cretaceous masses surrounded by dense fibrous tissue; the whole of the lower lobe was in a state of red hepatization and extremely rotten. At one spot in the upper part of this lower lobe the pulmonary tissue had entirely broken down, the visceral pleura had given way, and in consequence some of the disintegrated lung-substance had escaped into the pleural cavity, giving rise to hæmothorax and pleurisy. The left lung was much gorged with blood and very œdematous.

The structure of the heart was natural, as also were the mitral, aortic, and pulmonary semilunar valves. But the tricuspid was extensively diseased. To it was attached a large coagulum, soft and of a light brown colour; and on removing the clot the free edge of the valve was found to be ragged and eroded from ulcerative processes. Many of the chordæ tendineæ were similarly affected, and had been divided by the ulceration about midway between the apices of the columnæ corneæ and the edge of the valve; in this way almost all the cords of one of the flaps of the triscupid valve had been destroyed. In the recent state of the parts the valve was thick, opaque, and of a dull red colour, which contrasted strongly with the transparent and glistening appearance of the mitral. The liver was in an early stage of cirrhosis. The spleen was soft. The kidneys weighed eleven and a half ounces, were coarse in appearance, and much congested.

Cases of disease affecting the tricuspid valve are, comparatively speaking, of so rare occurrence, especially when the remaining valves are natural, that the present instance was deemed worthy of exhibition before the Society; and also because it was difficult to say for certain what was the cause of the ulceration affecting the tricuspid valve. Such cases are met with occasionally in pyæmia, but in this instance such a complication was at all events doubtful. It is true the man had pneumonia, and that shortly before his death the body

Digitized by Google

assumed the sallow hue so often met with in pyæmia. It may be, therefore, that this endocardial ulceration was only the internal manifestation of the blood poisoning. In that case, of course, the pneumonia was dependent upon the same cause, the source of which, in spite of a careful examination of the body, remained finally undiscovered. For the origin of the pulmonary affection, however, it seems scarcely necessary to go as far as pyæmia, for the patient had cretaceous matter deposited in the apex of the right lung. It is quite possible, therefore, that the pneumonia may have been due to tubercle, though against this supposition is the fact that the only tubercle found was in a quiescent state. That the disease was not of rheumatic origin the absence of any history of rheumatism would prove. The case is obscure, but after reviewing the facts it seems most probable that the cause of the ulceration of the valve and of pneumonia was pyæmia, though to what the blood-poisoning was due remained undiscovered. *November 15th*, 1870.

---

13. *Case of sudden death from embolism of the carotid and vertebral arteries; chorea and old mitral disease.*

By C. Murchison, M.D.

Annie C—, æt. 14, was admitted into the Middlesex Hospital on June 7th, and died on June 29th, 1870. When nine years old she had chorea of the left side for one month. The mother attributed this attack to the child having been much frightened by a man tapping at the window, but a week had elapsed between this occurrence and the commencement of the movements. After this she remained well till July, 1869, when the choreic movements returned, chiefly in the left arm and leg, and continued till January, 1870. In December, 1869, she suffered from painful swelling of the left knee

Digitized by Google

and elbow, but she was not confined to bed by this, and at no other time had she had any illness of a rheumatic nature. In April she lost her father and became very depressed in spirits, and on May 20th the chorea returned for the third time on the left side. She had never complained of any cardiac symptoms.

On admission the patient was a thin, pale, anæmic child. She had choreic movements of the left arm and leg, and occasional choreic twitchings of the left side of the face. Pulse 64 and regular. Transverse dulness of the heart three inches; a loud, systolic bellows-murmur at the left apex, audible also at the back; second sound over pulmonary valves accentuated. No œdema of legs, and no pulmonary complication.

June 12th.—Pulse 120; temperature 102°; pericardial friction; no pain in joints.

14th.—Right pupil smaller than left, and right internal strabismus; pulse 120; temperature 102·6°; pericardial friction still heard.

15th.—Much pain in heart and in back of head.

16th.—Pulse 112; temperature 101·5°; pericardial friction still heard; pupils equal.

17th. Pulse 108; temperature 99°; pericardial friction gone; no albumen in urine.

25th.—Pulse 100; temperature 98·4°; is much better in every way, and choreic movements have almost ceased.

28th.—At 6 p.m., while lying in bed eating bread and butter, became suddenly unconscious. Her head became drawn to the right side, and her extremities were extended and rigid. This state of rigidity was followed in a few minutes by occasional convulsive twitchings of the limbs, mostly on the right side. The pulse was 145, and bounding, and there was strong pulsation of the arteries in the neck. Respiration 44. Pupils equal, and rather large at commencement of attack, but subsequently contracted, in both cases not affected by light. Saliva running from mouth, but no paralysis. Temperature 102·5°.

At midnight the patient was still quite unconscious, and had occasional muscular twitchings of the right limbs. Both arms were involuntarily flexed at the elbow, and particularly the right arm, which was drawn across the face, but no other sign of paralysis of either arm or leg was noted. Right pupil contracted; left dilated; both immovable. Vomited beef tea. Urine passed in bed. Remained unconscious until death, at 6 a.m. of June 29th.

Digitized by Google

Autopsy.—One ounce of turbid serum in pericardium, and thin flakes of recent lymph over root of pulmonary artery. Heart six ounces and three quarters. Aortic valves healthy. Soft vegetations on mitral valve. On the edge of the valve are two large, firm excrescences, one of which terminates in two pointed processes, while the other has loosely attached to its free extremity a pale coagulum of blood more than half an inch in length. Spleen large, thirteen ounces and three quarters; it contained numerous, recent embolic masses. Both kidneys also contained numerous, large embolic masses of recent date, and surrounded by rims of congested renal tissue. Left vertebral and left internal carotid artery much distended, hard, and completely blocked by a pale, firm, easily detached coagulum. The left hemisphere was generally more congested and softer than the left, but in no part could any compound granular corpuscles, or other microscopic change, be found. Portions of the brain, medulla, and spinal cord were preserved in chromic acid, and subsequently examined microscopically by Dr. Cayley, who could discover no embolisms of the minute vessels such as have been described after death from chorea. *May 16th*, 1871.

---

14. *Fibrous tumour of the heart.*

By W. W. Wagstaffe.

The specimen exhibited is one which I wish rather to place on record than to give an exhaustive or satisfactory account of. The occurrence of simple tumours of the heart is so extremely rare that it may be useful to bring before the notice of this Society even a specimen which has been brought to light after lying in pickle for fifteen years.

During the present summer the preparation was placed in my hands as a tumour of the heart, and with it a written history drawn up about the time it was removed by the late Mr. Nunn, of Lynd-

Digitized by Google

hurst. This history was apparently drawn up for publication in one of the medical journals, but being, I suppose, too long, was refused, although its importance seems to be unquestionable.

As it appears now after maceration in spirit for fifteen years it is a rather rough globular mass, about two inches in diameter in each direction. It has been cut into for the purpose of examining the interior.

Upon the exterior one can trace muscular tissue on almost every side, and this muscular tissue cannot be dissected off at all readily; it appears to dip into the furrows between the more nodulated portions of the tumour, and to become blended with its substance. In the interior the consistence of the growth is extremely tough, and its structure, upon tearing it, evidently fibrous; its colour is uniform, and there is no evidence to the naked eye of the existence of central or diffused blood clot. There are no points of softening.

There is nothing in the specimen itself upon which it seems possible to determine the position which the growth occupied in the heart, for only the tumour appears to have been retained. Over one portion a smooth membrane passes; this is separated in some places by muscular tissue, and may have been either pericardium or endocardium.

Microscopically, the examination cannot after this lapse of time be expected to be satisfactory. The outer portions are infiltrated with foreign vegetable growth, and the internal structure is not readily made out.

Upon the exterior the muscular substance has all the appearance of that peculiar to the heart, but considerably disintegrated.

Sections made from just below the surface show the muscular structure accompanied by a large quantity of fibrous tissue, together with certain elements probably of a foreign and vegetable nature.

Sections from the interior show, upon being teased out, a network of interlacing fibres, the fibres large, wavy, and apparently identical with white fibrous tissue. Some of them are, however, peculiarly large and hard in outline. They are fully formed and distinct—unlike the appearance found in imperfectly developed lymph or blood clot. There is no yellow elastic tissue visible.

The history of the case is as follows:—

A female child, 3 months of age, of moderately healthy parents, died suddenly. It had been born at full time, was well formed, and

Digitized by Google

gave no sign of imperfect development or nutrition. It had never showed signs of imperfect circulation by lividity or swelling of extremities, had never suffered from difficulty of breathing, and all functions seemed to have been well performed. During the last month before its death it had occasional seizures, in which it threw itself back, extended its limbs, and seemed for an instant to hold its breath; it was not convulsed, and did not appear to lose its senses, but recovered almost immediately, and after a little crying appeared as well as ever again. On the evening of its death it was attacked by one of these fits, but was quiet almost immediately by a few drops of Dalby's carminative. An hour later another attack occurred, and this was relieved in the same manner. In another hour a third attack came on, and in a few minutes the child was dead without any struggling or cry.

At the post-mortem, which was made next day, it was found that the pericardium was distended with a quantity of pinkish serum. There was a patch of granular fibrin on the apex of the heart and on the opposed surface of pericardium. The heart was greatly enlarged, its shape elliptical, the apex nearly as large as the base, and on one side of this, towards the right ventricle, the muscular structure appeared to be thinned, and presented an almost tendinous appearance. On opening the cavities the valves were seen to be healthy, and the foramen ovale perfectly closed, but it was observed that the size of both auricles and ventricles was much diminished, not by a general thickening of the walls, but by the projection into them of the septum. When the thumb was placed in one ventricle and the forefinger in the other, instead of almost meeting they were felt to be separated by a tough inelastic mass of considerable thickness. An incision was made corresponding with the line of the septum, and a pinkish-white tumour fully the size of a hen's egg exposed. It lay between the muscular layers of the septum, which it had dissected from one another, from base to apex, and it was this distension which had given rise to the thin and tendinous appearance of the heart-walls when seen from the outside. There was no effusion into either pleura. The lungs were healthy. The other viscera were not permitted to be examined.

The specimen I have ventured to call fibrous tumour of the heart upon both negative and positive grounds.

The very complete account given declares it to have been taken from the heart, and although the preparation, as I now have it, does

Digitized by Google

not show this clearly, the microscopical examination of the muscular fibres covering it bears out the statement.

It being recognised as a heart tumour, it will be a question whether it may not be of the same nature as the majority of so-called simple heart tumours, *i. e.*, organised lymph or clot. Its enormous size (nearly equal to the size of the heart itself), and its occurrence before the early age of three months, are opposed to these suppositions; and the perfectly formed character of the fibrous tissue in it could not well be explained upon such an hypothesis. With regard to blood clot it would be difficult to imagine it to have been the source of the growth at this age, and the absence of blood crystals points in the same direction.

That it is not of a malignant character with a fibrous matrix appears pretty evident from the abundance of well-developed fibrous tissue in the growth, for such tumours have been with but two or three exceptions encephaloid.

The positive evidence of its right to be considered a fibrous tumour rests upon the abundance of this element found in the microscopical examination of sections from all parts. One of these results of section and tearing I have represented in the accompanying sketch. (Plate V.)

Of the importance of this specimen a proof is to be seen in the rare account, even in the 'Transactions' of this Society, of simple tumours of the heart. Dr. Peacock has shown in the sixteenth volume of the 'Transactions' that cancer of the heart is much more common than is generally supposed. But I have hitherto been unable to find more than a single case of simple heart-tumour not parasitic in its nature. This single case is one contained in the sixth volume, and is one in which a cyst containing curious beaded fibres was connected with the heart and burst into the pericardium. Rokitansky ('Path. An.,' vol. iv, 209) says he has never observed fibroid tissue in an heart under the form of an independent fibrous tumour.

Besides the rarity of such a tumour, the case is important as showing the extent to which a growth can encroach upon the cavities of the heart without interfering materially with their functions.

February 21*st*, 1871.

Digitized by Google

15. *Cancerous growths on endocardium, in liver, lympathic glands, and body of vertebræ; organized thrombus, perhaps cancerous, in iliac vein.*

By J. F. Payne, M.B.

Martha H—, æt. 41, admitted into St. Mary's Hospital, December 2nd, 1870, died January 18th, 1871. She had been feeling ill only three months, and complained of epigastric pain, worse after food and vomiting. There was a well-marked enlargement and nodulation of the liver, with other symptoms, which left no doubt that she was suffering from hepatic cancer. There was jaundice accompanied by extreme cachexia and feebleness, to which the patient ultimately succumbed.

At the *post-mortem* examination the body was found to be greatly emaciated, with a slight yellow tint on the skin. The lungs and pleuræ were perfectly natural, except for a few of the minute fibrous granulations often met with. The pericardium was natural. Within the right auricle of the heart, in the corner of the auricular appendage, was a small nodule of new growth the size of a pea, projecting into the cavity among the trabeculæ. It was very distinct from the muscular tissue of the heart, and was only just perceptible on the outside of the auricular wall. A similar nodule was found in the apex of the left ventricle, and was also contained among the muscular columns without appearing to involve them. These masses were of a whitish colour, and on microscopical examination presented very definite cancerous structures. They were not covered by the endocardium or by any fibrous structure resembling it; but the outer layer of the new growth consisted of a condensed cellular structure, with some approach to fibrillation. It was, when examined, either on section or from above, quite different from the endocardium. Inside the iliac veins, just at their function, but more in the left than in the right, was a mass resembling a blood clot, but of a peculiar pinkish colour and spongy texture. One piece of this, about three quarters of an inch long, in the left iliac

Digitized by Google

vein, was very firmly adherent to the wall, and was especially examined. It consisted of a pink, spongy substance, which on section looked organised and vascular. Sections of pieces hardened in chromic acid showed a network of organised tissue enclosing areas of red blood-corpuscles. The organised network was coloured very deeply by carmine; it consisted of a mass of small indifferent cells, resembling the cells of granulations, and therefore not to be directly distinguished from white blood-cells, and was traversed by blood-vessels with distinct walls, while part was distinctly fibrous. The ordinary fibrous network formed by blood coagulating was seen only in some parts of the mass, and not in the parts just described.

There were further considerable masses of undoubtedly cancerous growth in various organs, especially in the liver, which was greatly enlarged by the presence in it of tumours, some of which were four inches in diameter, and one quite six inches. It weighed more than eight pounds. The lymphatic glands round the hepatic vessels, and others surrounding the aorta, were converted into cancerous masses, and a continuation of these growths, in the connective tissue surrounding the aorta and vena cava, was very closely adherent to the veins at the point where they contained the mass before described, but the venous wall was not obviously perforated. The lumbar vertebræ were also connected with the mass, and the body of the last but one was found to be infiltrated with cancerous growth.

Remarks.—Cancer of the heart is in itself very rare, and more especially so is the occurrence of growths of this kind within the cavities. In this specimen the precise position of the new growths was remarkable and suggestive. They occurred in those two situations, viz. the appendage of the right auricle and the apex of the left ventricle, where clots formed during life are most frequently found, and where it must be supposed that some retardation in the blood current favours coagulation or deposition of fibrin. This fact irresistibly suggested the possibility of some germs or cells having been brought by the circulatory current and deposited there; more especially as the growths were clearly endocardial, and had not penetrated the heart from outside, or apparently originated in its substance. The mass afterwards detected within the iliac vein was accordingly very closely examined, but, as has been said, though it was clearly an organised new growth replacing or formed out of a thrombus, it had not any very definite characters of cancer, or, at least, was only in the nuclear or rudimentary stage. It cannot,

Digitized by Google

therefore, be clearly decided that there was any mechanical transference of the disease from the veins to the heart. As, moreover, the disease appeared on both sides of the heart, the infecting material, whatever it was, must, on such a supposition, have traversed the pulmonary circulation without producing any lesion.

March 21*st*, 1871.

Digitized by Google

IV. DISEASES, ETC., OF THE ORGANS OF DIGESTION.

(A) TONGUE AND DIGESTIVE CANAL.

1. *Cancer of the tongue and simple stricture of the œsophagus.*

By EDWARDS CRISP, M.D.

THE patient from whom the specimen was taken was a female, 64 years of age, who first came under my care in March last (1870), when she suffered from an attack of bronchitis. She complained, at the same time, of a little uneasiness about the angle of the right lower jaw, where there was a slight swelling. She had also some pain in the throat, especially when in the act of swallowing. The bronchitis subsided, and for a short time she appeared to improve in health. In July she went into the country for a month, but was not much benefited by the change.

I saw her again in October, when she was reduced in strength and had lost flesh; her countenance was anxious, and the pulse quicker. She had now three hard swellings along the seat of the lymphatic glands on the right side of the neck, and one on the left side; there was slight uneasiness when swallowing liquids, and solids produced pain and coughing. The tongue could not be fully protruded from the mouth, and the parts about its base were red and swollen; the enlarged glands in the neck were often very painful, lancinating pains extending to the right temple. It was difficult to get the mouth sufficiently opened to ascertain the exact condition of the fauces. She gradually declined in strength and died December the 12th. For three weeks before death she was kept alive by rectal injections of strong beef tea, milk, Liebig's food, and wine. A drop of liquid was instantly rejected, and produced great distress. The pain was chiefly referred to the nuchal swellings on the right side, and but little uneasiness was felt on the tongue.

On examination after death I found the lymphatic glands of the right side of the neck hard and fibrous, and, on section, exuding a

Digitized by Google

white milky fluid. A dark ulcerated surface existed at the base of the tongue, and the epiglottis was also ulcerated and of a dark colour. The tongue wide and shortened, with a hard elevated spot in the centre.

Above the chordæ vocales, and behind the epiglottis, was a grayish, softish tumour about the size of a nut, which narrowed the epiglottideal opening and altered somewhat the direction of the air tube. The anterior part of the epiglottis was of a reddish colour and slightly ulcerated; the œsophagus on a line with the upper part of the cricoid cartilage was considerably narrowed, and a membranous valvular fold was so placed as to prevent the introduction of a probe from above downwards.

The costal pleuræ were firmly adherent on both sides, but the lungs appeared to be in a normal state. Other parts not examined.

As the specimen is to be referred to the Committee on Morbid Growths, I do not give the microscopical appearances.

Remarks.—This patient for three weeks before death was unable to take even a particle of fluid, and was entirely nourished by anal injections. The cause of the inability to swallow, I believe, arose from the valvular stricture in the œsophagus, occasioned, probably, by the altered course of the air tube, for slight quantities of fluid appeared to pass into the pharynx, and were immediately rejected. The condition of the epiglottis might also account for this symptom. There had been slight difficulty in swallowing for some time before I saw her, but the total obstruction to the food came on rather suddenly. *January 17th*, 1871.

---

2. *Cancer of the œsophagus, with a fistulous opening into the trachea.*

By Edward Headlam Greenhow, M.D.

Edward Ward, æt. 59, by occupation a hall porter, was admitted into the Middlesex Hospital under my care on Febuary 4th, 1871.

Digitized by Google

In April of the previous year he had been attacked by some acute illness attended by violent headache, sickness and delirium, from which, however, after about three weeks' confinement to bed, he had recovered rapidly and had continued well until the end of August, when he began to experience difficulty in swallowing, together with a feeling of choking in the throat. Solids were more difficult to swallow than liquids, and a piece of bread or meat would stick in his throat until by an effort he made it pass downwards or return upwards. From that time the difficulty of swallowing gradually increased, until he felt, as he expressed it, as if there were a cavity in the gullet in which his food lodged, and from which it was dislodged and driven upwards as if by a blast of wind, attended by cough. He had, therefore, been unable for many weeks before his admission to take a sufficient amount of food, especially of solids. The last solid he had been able to swallow was some stewed maccaroni on January 28th, and the difficulty of swallowing even liquids had gone on increasing until on February 3rd, the day before his admission to the hospital, he ceased to be able to swallow anything and had an attack of choking, attended by so much difficulty of breathing that he thought himself at the point of death. He repeatedly pushed his fingers down his throat in order to force a passage for air, and about three hours from the commencement of the attack of dyspnœa he had a violent fit of coughing and brought up a large quantity of thick coloured expectoration, amongst which was a pale red fleshy looking lump, about the size and something of the shape of an almond in its shell. The mass was smooth, but rather irregular on one surface, which seemed to have been adherent; on the other surface it was flocculent and more rounded. After the escape of this mass he had become free from dyspnœa, but had continued unable to swallow even liquids, and had had almost constant cough.

On admission he was much emaciated. There was marked arcus senilis in both eyes. His voice was hoarse and he coughed almost incessantly, the cough having a laryngeal twang and being accompanied by a copious thin, frothy, opaque expectoration, for the most part muco-purulent and of a gray colour, but containing also many sputa of a bright yellowish hue, as if tinged with liquorice. Both the expectoration and the patient's breath had a very offensive gangrenous odour. He was all but totally unable to swallow. When he took a mouthful of milk or beef-tea it evidently passed the glottis and a small quantity may have reached the stomach, but

Digitized by Google

almost as soon as it seemed to have passed into the œsophagus the patient began to cough violently and brought up through mouth and nose a quantity of the above-described expectoration mixed with the liquid he had attempted to swallow. His tongue was furred; pulse 108, rather full and jerking, but very compressible; respirations 24; temperature 101·5°. There was no swelling nor tenderness on examination of the larynx and trachea externally, but there was slight tenderness on firm deep pressure immediately behind the right posterior border of the larynx. The chest was generally resonant on percussion, but there was slightly impaired resonance over the inner third of the right clavicle. The breath-sounds in front were obscured by loud tracheal breathings; posteriorly they were normal. On examination with the laryngoscope it was seen that the right vocal cord moved very imperfectly and did not approximate to the left one; the larynx appeared somewhat reddened and the right margin of the glottis excoriated. The right ventricle of the larynx seemed to be dilated, and a frothy secretion identical in appearance with the sputum flowed out freely, so as greatly to impede the view.

A weak solution of carbolic acid was thrown into the larynx in the form of spray five or six times a day, which greatly diminished the gangrenous odour of the breath and sputum, and the patient found comfort and relief from the application. Every endeavour was used to sustain life by means of enemata of beef-tea, brandy &c., but the patient's strength became exhausted and he sank and died on the evening of Febuary 10th.

At the *post-mortem* examination the canal of the œsophagus was found to be narrowed at one part by an ulcerated cancerous mass, in the middle of which was a fistulous opening into the trachea which would admit the point of a finger.

After maceration in spirit the separation of soft portions from the cancerous mass formed a second opening, divided from the first by a transverse band.

Dr. Cayley has kindly examined the specimens, and furnished me with the following report:

"The mucous membrane of the larynx was healthy. The whole inner surface of the œsophagus, commencing at the level of the cricoid cartilage and extending downwards for three inches, was occupied by a sloughy tract of ulceration, with ragged cancerous outgrowths, some almost detached. The margin of this tract of ulceration was raised and hard, and on microscopical examination

Digitized by Google

presented characteristic features of epithelioma, with well-developed laminated cell-nests. About the centre of the ulceration there was a perforation leading into the trachea measuring an inch in diameter, and divided into two by a band of slonghy tissue. The margins on the tracheal aspect were raised and sloughy, and at one point it appeared as if a portion of tissue had been detached. Extending upwards from the perforation as high as the cricoid cartilage, the posterior wall of the trachea presented a bulging surface, due to an infiltration of cancer into the submucous coats. This bulging corresponded to the interval between the cartilaginous rings. Some of the glands in the neighbourhood of the trachea and œsophagus were infiltrated with cancer. A small diverticulum was present in the œsophagus some inches below the ulcerated part.

"The fleshy looking mass expectorated from the larynx during life was soft on the exterior, but towards the interior firmer and more fibrous, and it had a very offensive gangrenous odour. On microscopical examination the softer portions presented long villous processes, filled with oily and granular matter, and not furnished with any epithelial covering. The firmer part consisted of tracts of connective tissue, and contained here and there small deposits of the laminated cell-nests characteristic of epithelioma."

March 7th, 1871.

---

3. *Cancer involving pharynx, larynx, neighbouring lymphatic glands, and lungs.*

By J. S. Bristowe, M.D.

Mrs. P—, a married woman, 48 years of age, was admitted into St. Thomas's under my care on the 27th February, 1871. She had had good health until twelve months ago, when she first complained of sore throat and difficulty in swallowing. From that time the difficulty in swallowing has increased, and she has been getting thin and weak, and low-spirited. Last October the glands on the right side of the neck began to enlarge and grow hard. They suppurated two months ago and were opened, since when a fistulous

Digitized by Google

opening has remained. She has been unable to swallow solids for the last two months, and during the last two weeks has refused fluids as well.

On admission she was very feeble and much emaciated. She had a group of enlarged glands on the right side of the neck, a little outside and below the angle of the jaw. These were exceedingly hard, adherent to the skin, and presented one or two openings, which discharged a little fetid sanies. The pillars of the fauces were healthy, but the right tonsil was enlarged, smooth on the surface, and very vascular. There was some tenderness in the course of the larynx and trachea, and these seemed set, as it were, in hard indurated tissue. She was unable to swallow either solids or liquids without choking. Her voice was a hoarse whisper. She had a slight cough, without expectoration, and breath of excessive fœtor, like that of a patient suffering from gangrene of the lung.

The patient survived her admission into the hospital five days only, during the greater part of which time she was in a moribund condition. She swallowed nothing, and it was endeavoured to nourish her by the periodical administration of nutritive enemata.

At the *post-mortem* examination the cervical glands on the right side of the neck, the right tonsil, and some of the glands along the trachea and about its bifurcation, were enlarged, indurated, and apparently affected with hard cancer. The right side of the epiglottis was in great measure destroyed by ulceration, as well as the right aryteno-epiglottidean fold, these parts being involved in an extensive and deep ulcer occupying the base of the tongue and right side of the pharynx, and encroaching on the lower part of the tonsil and the upper part of the œsophagus. The mucous membrane of the upper part of the larynx was congested and œdematous. The soft tissues about the larynx and trachea and the thyroid body were somewhat indurated, but not distinctly cancerous.

There were old adhesions in both pleuræ. The right lung was somewhat large and heavy, non-crepitant in parts, and of a greenish hue. It contained a large mass of cancer, which was excavated in the centre into an irregular cavity with gangrenous walls. The left lung was generally crepitant, and contained several small cancerous nodules. All other organs were fairly healthy.

On microscopic examination the diseased masses were found to contain abundance of large irregular epithelium-like cells, which

Digitized by Google

escaped in the juice, and groups of which occupied tracts hollowed out in the stroma. The masses were, in fact, an ordinary form of cancer. *May* 16*th*, 1871.

---

4. *Cancer of œsophagus; employment of stomach-pump; free communication between œsophagus and trachea; death by perforation of common carotid; paralysis of left vocal cord.*

By J. S. Bristowe, M.D.

J. Q—, a man, 51 years of age, was admitted into the hospital on the 22nd July, 1870. He had been ill, he said, since the middle of March, when he began to suffer from difficulty of swallowing and some difficulty of breathing. The former of these symptoms gradually increased in severity, so that for some time past he has been able to take food in very small quantities only, and latterly he has swallowed nothing but liquids, his appetite all along, however, having been very good. He has been getting weak and thin; his voice has been weak and a little hoarse from almost the commencement of his illness.

He was, on admission, pallid, emaciated, and weak, had difficulty in swallowing, and choked when he endeavoured to swallow solids. His voice was weak and a little husky. There was no obvious difficulty of breathing as he lay in bed, and he had little or no cough. Chest resonant; breath sounds feeble, and attended with slight rhonchus; heart sounds feeble, but healthy. No evidence from auscultation or percussion of aneurismal or other tumour within the thorax. There was a little fulness (it was thought) deep-seated in the lower part of the right side of the neck in front. On examining the larynx with the laryngoscope the vocal cords appeared to be healthy in colour and in form, but the left one was motionless, remaining in the position of closure. So far as could be ascertained, the abdominal organs were all healthy. There was no sign of arcus senilis. The arteries at the wrist were tortuous and rigid.

The patient, for a week after his admission, and again for ten days

Digitized by Google

before his death, was under my care, but during the intermediate period of two months was under the charge of my colleague, Dr. Clapton. The details of the progress of his case and the details of treatment it is unnecessary to give. He gradually became weaker, and also more and more incapable of swallowing, though still retaining a good appetite. Under these circumstances an endeavour was made to pass a stomach-pump tube into the stomach; an obstruction was discovered about opposite the upper margin of the sternum, but was surmounted with little difficulty and no apparent injury, and through the tube a meal was administered. For a short time the tube was passed periodically, but before long it was thought best to retain it in the œsophagus, and for about the three weeks immediately preceding his death, it was never removed from thence. Abundant fluid nourishment was given to him by this means twice a day, and there can be no doubt that, although there was no very obvious improvement in health, his life was thus prolonged.

For a month, or perhaps even longer, before his death he brought up at times a little offensive mucus from the throat, and during the last fortnight it increased in quantity, was hawked up, and was excessively fetid, and a similarly fetid odour tainted his breath. There was no material difficulty of breathing and no cough, and his stomach did not rebel against the food which was administered. He gradually got weaker, but his death, which occurred at 1 a.m. on the 13th October, was sudden, being immediately preceded by a very copious escape of blood from the mouth.

At the *post-mortem* examination very extensive destruction of the œsophagus was found, commencing on a level with the lower border of the thyroid body, terminating below at the arch of the aorta, occupying about two inches of the length of the œsophagus, and involving the whole of its circumference excepting only a narrow band at the back and towards the left side. There existed, in fact, in this situation, interrupting the course of the œsophagus, an irregular excavation capable probably of holding a hen's egg, the margins of which were for the most part shreddy and gangrenous. The destruction of tissue had taken place chiefly to the front and towards the left side, and had involved the posterior and left half of the circumference of the trachea for about an inch of its length (so that the œsophagus and trachea in this situation formed a common cavity), and had led to perforation of the left common carotid artery by a minute aperture at about one and a half inch from its origin. There was a small

Digitized by Google

pharyngeal ulcer at the back of the cricoid cartilage, partly exposing the cartilage, and there were several greatly enlarged lymphatic glands above and to the right of the œsophageal ulcer, and lying between the common carotid and subclavian. These had been recognised during life.

The lungs were small and crepitant, and the bronchial tubes contained blood, but there was no disease in them. And all other organs throughout the body were fairly healthy.

On microscopical examination the diseased lymphatic glands in the neck were found to be distinctly cancerous, and traces of the same kind of disease were recognised in the parietes of the œsophageal ulcer. The greater part of the parietes of this ulcer was, however, slough of otherwise healthy tissue. The ulcer over the cricoid cartilage was free from cancerous taint. The left recurrent laryngeal nerve was not dissected out, but it was obvious from the position of the gangrenous cavity connected with the œsophagus that its continuity was destroyed.

Remarks.—This case resembles another case of cancer of the œsophagus which I brought before the Society at an earlier period of the session, in the fact that the voice was affected, and the left vocal cord was paralysed by the involvement of the left recurrent laryngeal nerve. The chief interest of the case, however, is connected with the fact of the extensive communication which was found to exist between the trachea and œsophagus. No one can doubt that this communication must have existed for some little time before death, and that the patient must have succumbed much earlier than he did had he not been kept alive by the administration of food by the stomach-pump; and, indeed, no one can doubt that the destruction of tissue which was found after death could never have become so extensive had not the patient been artificially sustained during its progress. But, on the other hand, it seems certain that the small ulcer (in itself trivial) at the lower part of the pharynx must have been caused by the presence of the tube, and the question naturally arises as to how much of the ulcer lower down was due to the irritation of the same instrument. That some was thus caused must, I think, be considered certain. On the whole, it seems to me that the case, while showing very clearly the advantages which may result from the use of the stomach-pump in such cases, points equally clearly to the danger which may follow upon that treatment.

May 16*th*, 1871.

Digitized by Google

5. *Cancer of stomach, liver, lungs, lymphatics of the thorax, with involvement of the left recurrent laryngeal, and paralysis of the left side of the larynx.*

By J. S. Bristowe, M.D.

W. P—, a potman, æt. 49, was admitted into hospital under my care on the 12th April, 1870. He stated that he had had perfectly good health until just before last Christmas, when he began to suffer from pain at the chest after food, with sickness coming on a few minutes afterwards; that these symptoms had gradually increased upon him, and he had become thin and weak and pallid; that he vomited suddenly three pints of blood six weeks before admission, since which time his voice has been feeble and husky; and that for the last month he has been compelled to keep his bed.

He was emaciated and feeble, and very anæmic. He spoke in a hoarse whisper, but had no pain or difficulty in swallowing, and no cough. Chest resonant; heart and breath sounds healthy; P. 100. Complains of some tenderness on pressure in the epigastrium, and hepatic dulness extends for about one inch below the ribs, but there is no abdominal enlargement and no sign of tumour. Tongue clean; slight appetite; bowels constipated; urine free from albumen; no anasarca. He remained in the hospital until the 9th June, during which time he undoubtedly got more and more feeble, although, on the whole, the pain in the chest after food diminished, the sickness left him almost entirely, and he had a fair appetite, indeed at times a craving for food. About the middle of May he began to complain of some special difficulty in swallowing fluids; they were apt to get into his windpipe and choke him; about the same time also slight œdema of the legs was detected, and a slight cough came on. During the remainder of his stay the œdema continued, the difficulty of swallowing fluids increased somewhat, and became more severe and attended with mucous expectoration. No abdominal tumour, however, could at any time be detected, and excepting the presence of a little variable rhonchus the breath sounds remained healthy. His larynx was examined several times with the laryngoscope, and it was

Digitized by Google

ascertained that the vocal cords were healthy in appearance, but that the left cord was paralysed. The right moved freely; the left was motionless, occupying permanently the position of closure.

I came to the opinion that the patient was suffering from malignant disease of the stomach, associated with similar disease of the lymphatic glands behind the stomach and along the posterior mediastinum, and that through the latter the left recurrent laryngeal nerve had become implicated.

On the 9th June he left the hospital at his own wish, but returned again on the 7th July. He was then very ill indeed; much weaker, and almost a skeleton; extremely anæmic, and œdematous in his eyelids and lower extremities. There was little change as to his voice or power of swallowing, and there was still no obvious lump to be detected in the abdomen. But his cough had become very much more severe, and his expectoration very abundant and streaked with blood. On examining the chest the lower third of the right lung in front and the lower two thirds behind were found dull on percussion, the former part yielding abundant subcrepitation and creaking, the latter part well-marked tubular breathing and increased vocal fremitus, and at the base of the left lung in front there was a little subcrepitation.

No new symptoms showed themselves, but he rapidly sank, and died on the 13th July.

Post-mortem examination.—Chest.—The left pleura was healthy; the right contained a few ounces of turbid serum, and was lined with an abundant recent false membrane. The lower lobe of the right lung was consolidated, of a grayish tint, lacerable, and yielding purulent fluid on pressure. Numerous cancerous nodules were scattered throughout both lungs, varying in size from that of a millet-seed up to that of a hazel-nut. The glands of the posterior mediastinum were enlarged, and largely affected with the same kind of morbid growth. The larynx, trachea, and indeed the bronchial tubes also, were for the most part healthy; but on the left side of the trachea, a little below the thyroid gland, was a cancerous mass about the size of a filbert, through which the left recurrent laryngeal nerve passed, and in which it appeared to be lost. Pericardium and heart healthy.

Abdomen.—Peritoneum generally healthy. The liver weighed 58 ounces, and presented many variously sized cancerous masses. The gastro-hepatic omentum and the glands behind it were also the seat

Digitized by Google

of cancerous growths, which were adherent to the liver above and to the posterior and upper part of the stomach below, the mucous membrane of the stomach being ulcerated in this situation. All other organs were healthy.

Microscopic examination.—The tumour had the usual characters of cancer, presenting a great abundance of large irregular-shaped cells, with large nuclei, arranged for the most part in groups or masses.

October 18*th*, 1870.

---

6. *Case of gout in the stomach (?) and phlegmonous colitis.*

By W. Moxon, M.D.

The patient from whom these specimens were procured was a man, æt. 39, who had suffered much from rheumatic gouty symptoms, for which he had been in Guy's Hospital a year before his death, and was again admitted September 14th with albuminuria and diarrhœa, under which symptoms he sank without dropsy or coma.

The body was spare and thin, the muscular system especially spare. There was some proportional excess of fat. Both lungs showed early spreading phthisis, with a few clusters of recent tubercles in each.

The heart was hypertrophied, weighing 15½ ounces.

The stomach was rather thick-walled and rigid through inflammatory infiltration, its cavity empty, and its surface alkaline; its interior was remarkable from the state of the mucous membrane, which was patched unevenly, though almost universally, with a yellowish or buff coloured layer of fibrine, which was adherent, and on removal appeared to bring away with it some part of the mucous membrane.

The small intestines were fairly healthy, but the colon showed another curious condition. There were boil-like phlegmons in the submucous tissue, some just forming, some already small abscesses with the mucous surface over them coated with lymph, others as ulcers with a ragged base, and others yet showing similar ulcers nearly and others quite healed, showing a blackish cicatrix. The

Digitized by Google

general face of the membrane was irregular and contracted from this furuncular process, which appeared to have been going on for a long time; on the whole, a large part of the membrane was not destroyed by the boils.

The kidneys were small and contracted, the cortex much wasted, the surface irregularly granular, the pyramids contained grains of urate of soda.

The great toe- and knee-joints formed beautiful specimens of gouty deposit in the cartilage, which was made uniformly opaque white by the urate of soda.

Whether the disease in the stomach and rectum in this case is rightly referable to the gout is, of course, open to question. I have never seen in any other cases similar severe inflammation of the stomach in gout. Although gout in the stomach is a frequent expression, I am not aware that it rests on any anatomical observations, rather it is used to express the sudden occurrence of severe gastric symptoms in gouty subjects. I could not, however, learn that this man had given any sudden and remarkable signs of gastric disturbance, or more than consorted with his dysenteric state. Nevertheless, as both the state of the stomach and of the colon were decidedly unusual, I thought their association with gout was worth noting. Apart from this association the occurrence of follicular gastritis is so rare that it appears to be deserving of record. This is the third time I have seen phlegmonous colitis associated with gastritis—once also phlegmonous. In a case of nitric acid poisoning the colon, though still occupied with scybala, and not reached by the bloody produce of the nearly destroyed stomach, yet showed a very remarkable enlargement, opening, and incipient, ulceration of the mouths of its follicles, which were converted into little red-edged sores of the size of a millet-seed to a lentil. These instances of sympathy between stomach and rectum might be aided from the history of cancer.

October 18*th*, 1870.

Digitized by Google

7. *Fatal hæmorrhage from simple ulcer of the stomach.*

By E. Crisp, M.D.

The specimen was furnished by Mr. Paddon, of Putney, who has also supplied me with notes of the case.

Susannah Underhill, æt. 62 years, a tall spare woman, of abstemious habits, was in her ordinary health on November 9th, 1870, on the evening of which day she was assisting as a waitress in a family. On returning home that night she was suddenly seized with violent vomiting of blood, ejecting more than a quart of bright red fluid blood.

The following morning (the 10th) I was sent for, as sickness had recurred, and I found her vomiting bright red fluid blood into a hand-basin (about a quart); after this she expressed herself as being more comfortable and feeling much relieved. The patient had, however, a peculiar waxy looking colour, almost suggesting the cancerous diathesis, and at first, I was inclined to think she had malignant disease of the stomach. She informed me that she generally enjoyed fair health, but often suffered from indigestion and bilious attacks. No further vomiting occurred for the next two days, although from the character of the stools blood was doubtless passed on two occasions with them. The patient was, however, sensibly weaker, the pulse being 120.

On the 13th vomiting of blood again recurred (about a pint), and soon after symptoms of severe prostration set in, the pulse going up to 140. She died on the morning of the 14th.

Fearing from the quantity of blood lost on each occasion, from its bright red colour and its fluidity, and from the age and spare habits of the patient, and from no enlargement of the liver or spleen being detectable, that this was not a hæmorrhage due to hepatic congestion, gallic and sulphuric acids were given internally, and beef-tea injections administered per rectum.

Post-mortem, ten hours after death:

Abdomen only opened.

On removing the stomach an ulcer was easily seen on the visceral surface, of the size of a threepenny-piece, with the mouth of an

Digitized by Google

eroded artery opening into it. At the time of the removal there was a red areola around the margin of the ulcer, that looked like blood-staining, but there was no thickened or raised edge. The ulcer had not gone beyond the submucous coat, the peritoneal surface of the stomach being perfectly free and nowhere adherent.

The pyloric extremity was quite healthy.

Liver not enlarged, healthy in structure, but pale.

Spleen healthy.

Duodenum healthy.

Remarks.—Our 'Transactions' contain six cases of fatal hæmorrhage from ulceration of the stomach—by Dr. Peacock, vol. i; Dr. Hare, vol. xvi; Dr. Robinson, vol. xviii; Dr. Murchison, vol. xxi (2 cases); Dr. Peacock, vol. xxi. The two cases related by Dr. Murchison in the last volume of the 'Transactions' bear some resemblance to the above. In the seven cases (including the above) four of the ulcers were simple, without indurated edges, and in the others the edges were thickened. *January 17th*, 1871.

---

8. *Recent specimens of acute dysentery from Sedan.*

By John Murray, M.D.

An opportunity was afforded me, while resident for a short time at the ambulances at Sedan, of seeing a large number of cases of dysentery, a disease which became prevalent amongst the troops after the series of engagements so well known to all the members present.

The specimens presented to the notice of the Society were brought to England for the museum of the Middlesex Hospital; but as recent specimens of acute dysentery are rarely to be seen in this country, I thought it might not be out of place to bring them here to-night.

The specimens are ordinary examples of those met with at the seat of war, and were taken from the bodies of German soldiers.

Digitized by Google

For some days prior to the crowning victory at Sedan the troops had been fed on a very insufficient supply of food, and that often of a doubtful character, and they had been exposed to great exposure and fatigue in their forced marches. They appeared to have borne up pretty well at first, but the reaction consequent on the fighting, the vitiated atmosphere from decomposing bodies, the continued short rations and bad water, and the inclement weather to which they were exposed after the battle, proved too much for them, and disease soon began to show itself. Within a few weeks a large number of the German troops remaining at Sedan were seized with dysentery and typhoid fever, of which some five or six hundred were crowded into and treated at the spinning manufactory, and a few outlying houses at Pont Mougy, two and a half miles out of Sedan. It was chiefly at this ambulance, by the kind permission of Drs. Schwab and Pachmayer, of the Bavarian Medical Staff, that I availed myself of the opportunity of studying the cases when free from my other duties at the English ambulance of Dr. Frank. As I directed my attention chiefly to the morbid appearances found after death, and as my notes are not sufficiently copious to afford a full or faithful account of the clinical features of the disease, I shall merely give an outline of the *post-mortem* appearances I usually found in examining the bodies.

The ordinary appearances observed after death were great emaciation of the body. The mucous membrane of the entire large intestine was the seat of great tumefaction and redness, which was most marked in the lower half of the colon and the rectum. The lining membrane of these parts was softened, ulcerated in variously sized patches, and covered with mostly white and minute aphthous patches of exudation. The transverse rugæ seemed to suffer most. The mucous membrane of the large intestine, and chiefly so towards its lower half, was more or less gone, in some cases the colon and rectum being almost completely denuded, in others in patches the size of an adult hand. The muscular coats of the bowel were in some parts, and not infrequently, laid completely bare. Submucous extravasations of blood were frequent. The small intestine, and generally the stomach also, were intensely and diffusely injected, and the lining membrane of the ileum swollen and inflamed, with sometimes ulceration of Peyer's patches. The intestines contained a variable quantity of thin and very offensive greenish-brown fæces, mixed with blood and the products of the inflammatory changes

Digitized by Google

going on in the bowels. The mesenteric glands were frequently much enlarged and congested, and this was specially observed where the Peyer's patches were in any way ulcerated. The spleen appeared to bear some relation to this condition of Peyer's patches, and was generally enlarged and congested. The liver was generally congested; the gall-bladder sometimes full, at other times empty.

In none did I observe any signs whatever of hepatic abscess. The kidneys were congested; the lungs in some cases gorged with blood, in others pale and collapsed, with some hypostatic congestion of their bases. The heart was generally flabby, and its cavities contained dark and loose clots. *October* 18*th*, 1871.

---

9. *Case of enteric fever with constipated bowels, proving fatal by intestinal hæmorrhage on the twenty-seventh day.*

By C. Murchison, M.D.

John D—, æt. 24, was admitted into the Middlesex Hospital on March 10th, 1871, on the twentieth day of an attack of fever. He had been taken ill on February 19th, and had kept his bed since the 21st. His symptoms had been rather severe headache and general pains, prostration, thirst, loss of appetite, nausea, and constipated bowels. After admission his symptoms were temperature varying from 101·8° to 104·8° Fahr., and pulse from 98 to 128; no characteristic spots, but marked *taches cérébrales;* irregular perspirations; a dry brown tongue; no abdominal pain, distension, or gurgling; occasional retching of bilious fluid, but bowels acting only once in two or three days; motions rather loose and light-coloured; sleeplessness, followed by stupor, deafness, and subsultus; occasional epistaxis; congestion of the lungs, and a considerable quantity of albumen in the urine. On the evening of March 15th (twenty-fifth day) the patient had an ochrey motion, not very loose; his temperature was 104°. During the ensuing night he was very restless and delirious, and on the following morning he passed a motion containing a considerable quantity of fluid red blood.

Digitized by Google

Turpentine and acetate of lead were prescribed, and all this day there was no further action of the bowels; the temperature was only 102·8°, and the pulse about 108. On the following morning (March 27th) the temperature had fallen to 100·8°, but the pulse had risen to 128. Three dark motions had been passed in bed during the night; the bloody motions recurred three or four times in the course of the day, and the temperature fell to below 100°. From 6 p.m. till death at 9 p.m. he was almost constantly discharging bright red blood from the bowel, and the surface of his body was blanched, cold, and clammy.

On examination of the body after death there was found to be extensive disease of Peyer's patches, and of the solitary glands in the lower five or six feet of the ileum. The hæmorrhage did not seem to have proceeded from one ulcer in particular, but to have been due to a fungating condition of the morbid material in many of Peyer's patches nearest to the cæcum, corresponding to which were dark-red spongy excrescences firmly attached to the subjacent ulcerated surface. The spleen and mesenteric glands were enlarged. The kidneys together weighed 11 oz.; they were congested, but showed no sign of old disease.

This was one of many cases which have come under my notice where a patient with enteric fever has died suddenly by intestinal hæmorrhage or perforation, although previously there had been no diarrhœa nor other evidence of intestinal mischief. In regard to diagnosis, it is important to remember that diarrhœa may be absent in enteric fever and present in typhus. At a previous meeting of the Society ('Trans.,' vol. xvi, p. 124) I exhibited the intestine of a typhus patient who died of exhaustion consequent on diarrhœa, but in whom there was no disease of the intestinal glands. Fall of the temperature with a rise of the pulse is a common indication of hæmorrhage in enteric fever. *April 4th*, 1871.

Digitized by Google

10. *Concretions in the appendix vermiformis, causing ulceration, perforation, and fatal peritonitis.*

By C. Murchison, M.D.

These were three small concretions, the largest about the size of a pea, removed from the appendix vermiformis of a girl, æt. 18, who died in the Middlesex Hospital on December 15th, 1870, on the sixth day of an attack of acute peritonitis. She had all her life enjoyed excellent health till the evening of December 9th, when she was suddenly seized with acute abdominal pain followed by vomiting. She was brought to the hospital on December 12th. On the previous day the bowels had been freely moved by castor oil, and four hours before admission the catamenia had appeared. There was no gonorrhœa, and no evidence of injury or of old organic disease. By the eliminative process perforation of the appendix vermiformis was diagnosed to be the cause of the peritonitis.

After death there were all the signs of general acute peritonitis, which culminated in the region of the cæcum. The appendix vermiformis was extensively ulcerated on its inner surface corresponding to the concretions.

This case was an exception—the second which has occurred in my practice—to the general rule, that perforation of the appendix vermiformis from concretions or foreign bodies chiefly occurs in males. Of 52 cases collected by Volz and Crisp, 46 were males and only 6 females. The preponderance of this accident in the male sex has not yet been satisfactorily explained, but is probably due to some anatomical difference in the appendix. *April 18th*, 1871.

---

11. *Polypus of rectum.*

By J. W. Hulke.

A young woman was admitted into the Middlesex Hospital in the summer of 1870, complaining of occasional loss of blood from

Digitized by Google

the rectum, and pain during defecation. On examination a small hard tag of thickened skin was found at the margin of the anus and in the rectum, attached by a slender stalk; just above the level of the internal sphincter was a polypus of the size of a bean. The stalk was tied and it was cut off. It consisted of a central mass of a delicate, finely fibrillated, and nucleated stroma, pervaded by large and numerous blood-vessels, the walls of which were very thin. Externally the stroma became closer and less vascular, and at its outer surface it bore a distinctly papillated layer. This was covered by a thick epithelium, the deeper cells of which were small and round or roundly oval, and the superficial ones squamous. This form of epithelium is remarkable, because the normal epithelium of the rectum, like that of the small intestine, is columnar.

I find only three examples of rectal polypi recorded in our 'Transactions,' and the minute structure of these is only briefly mentioned. One exhibited by Mr. Bryant (vol. viii, p. 295) was about the size of a bean, very vascular, and it had a fibro-cellular structure. The second was shown by Mr. Holmes (ix, p. 213); its interior is described as soft and not very vascular, and somewhat resembling imperfectly formed gland-tissue. Both these had a long slender stalk. The third was brought before the Society by Mr. Jessop (vol. xviii, p. 94); it differed from the above in being multiple, and it is said to have been composed of simple fibre.

A small stalked rectal polypus which I examined several years ago consisted of a mass of glandiform tubuli resembling those of Lieberkühn, and this was the structure of a similar polypus described by Mr. Paget. Förster and Billroth give excellent figures of this form.

It appears, then, from the data we at present possess, that three forms of polypi occur in the rectum—*glandular* polypi, which may be regarded as local overgrowths and outgrowths of the normal glandular elements of the mucous membrane; and *fibro-cellular* and *fibrous* polypi, which are probably evolved out of the submucous tissue, the former having a more delicate stroma and numerous blood-vessels, the latter possessing a firmer stroma and fewer vessels. *February 7th*, 1871.

Digitized by Google

12. *Direct inguinal hernia in the female.*

By W. Squire.

The patient from whom this specimen was removed after death had long suffered from hernia. She was subject to winter cough, and had not worn a truss. On Christmas Day the hernia became impacted after a fit of coughing; the symptoms were not urgent, and it was not till the 28th that an operation for the reduction of the mass seemed to be necessary. Some doubt as to whether the hernia was direct or oblique existed at the moment of operating, but, following the rule of dividing the stricture directly upwards, this doubt was immaterial. The protrusion was entirely omental; the operation gave complete relief from pain; no febrile disturbance followed, but the patient sank and died, apparently still under the influence of shock, on the third day, December 30th, 1870. *January 3rd*, 1871.

---

13. *Strangulated femoral hernia; reduction en masse.*

By Henry Morris, M.B.

The subject of this occurrence was a widow, æt. 78, who had for some time been suffering from bronchitis and general failing of health, and was admitted into the Middlesex Hospital on Wednesday, January 11th.

She stated that on Sunday, January 8th, while coughing, she felt something give way in the right groin; that during the night and the next morning she suffered considerable pain in the lower part of the abdomen, and vomited several times. On Tuesday morning she applied for relief, when the rupture was detected, and its reduction by taxis and afterwards by ice attempted; again, during the

Digitized by Google

day of Wednesday taxis was employed by two medical men, but without producing any diminution of the size of the tumour; she was then sent to the hospital. On her admission the swelling in the right groin was the size of a large pigeon's egg; it gave no impulse on coughing, and she was sick, the vomited matter being stercoraceous. Chloroform was at once administered, and Mr. Lawson, in Mr. De Morgan's absence, proceeded to operate. Before doing so, however, he for a few moments tried the effect of taxis with the aid of chloroform, and, causing no alteration, he forthwith cut down upon the tumour, but without opening the sac. After freeing all constrictions outside the neck of the sac, and gently pressing upon the rupture, the tumour at once disappeared. During the night and next morning the symptoms of strangulation continued, so that at midday Mr. Lawson deemed it advisable to re open the wound and make a careful examination of the parts. On doing so his finger passed into a pouch, which he immediately felt was not the peritoneal cavity, and in this he detected a small tumour; no coils of intestines, however, impinged against the finger. As it was conclusive, therefore, that the previous reduction had been one of reduction *en bloc*, and that the neck of the sac was still constricting the contained gut, a free incision was made into Poupart's and Gimbernat's ligaments, and the tumour hooked up from behind the pubis into the canal. The sac, which bore a strong resemblance to omentum, was laid open, the stricture at its neck divided, and a small coil of deeply congested bowel returned into the peritoneal cavity. The sac was then ligatured at its neck, and the portion below cut off; the end of the ligature was left hanging from the wound, and the parts brought together in the usual way. From this time all signs of strangulation ceased, but the wound had to be again opened to check hæmorrhage; this was done for the time, but a good deal of *oozing* subsequently occurred, and she died from exhaustion in the evening of January 13th, thirty hours after the second operation.

Post-mortem.—At the post-mortem examination, which was made nineteen hours after death, there was, in the right crural region, a longitudinal wound rather more than two inches in length, through which passed a stout silk ligature. When traction was applied to this, some dark stringy areolar tissue and a good deal of blood-clot were extruded, and the ligature was seen to surround a pedicle of tissue having the appearance of omentum. On passing the finger

Digitized by Google

through the wound in the crural region it could be moved readily about in a large cavity, in which no intestines could be felt, and the walls of which were granular and rough to the touch; this reached upwards for about two inches behind the right rectus muscle downwards to a considerable depth into the pelvis, outwards towards the iliac fossa, and inwards behind the pubis and in front of the bladder. A good deal of black blood-clot was turned out from the pouch, and the lower end of the rectus muscle was lacerated and projected into it from above. The posterior wall of this large pouch was seen on opening the abdomen to be formed by the peritoneum detached from this part of the abdominal and pelvic walls, strengthened everywhere by the subperitoneal fat and fascia, and below by the front surface of the bladder, which latter organ, with the uterus, was displaced backwards towards the sacrum. The abdominal wall contained a thick layer of fatty tissue, and the peritoneum and subperitoneal fascia were but loosely connected with the rest of the wall, so that everywhere the peritoneum with its fascia could be easily separated.

No trace of peritonitis existed, but the ileum, which was lying free within the peritoneal cavity, was congested in two places. One portion, an inch and a quarter in length and barely involving the entire circumference of the bowel, was of a deep port-wine colour, excepting at the points of stricture, where the surface was soft and yellowish; the other portion, similar in extent and about eight inches above the former, was much less deeply congested. On the inner surface of the peritoneum, corresponding to the point of application of the ligature, was a rosette-like puckering, which had evidently formed the neck and orifice of the hernial sac.

Remarks.—The rarity of this complication of femoral hernia is, I think, sufficient apology for bringing the case under the notice of the Society.

Le Dran, the surgeon who first noticed reduction *en masse*, met with it first in a man with femoral hernia. Mr. Hulke has recorded a case in the forty-seventh volume of the Medical and Chirurgical Society's 'Transactions', in which the neck had been ruptured from the body of the sac, and the intestines lay in a large abdominal pouch outside the peritoneum; and Mr. De Morgan has mentioned to me a case which he has seen, but which is not recorded, where this same accident had probably occurred, and a false membrane lined a pouch formed between the peritoneum and pelvic wall.

Digitized by Google

In the third volume of this Society's 'Transactions' a case is also reported by Mr. Avery of femoral hernia reduced in mass.

Several instances of this mode of reduction are referred to by Mr. Luke and Mr. Birkett, in their papers in the Medical and Chirurgical Society's 'Transactions,' but these are all cases of oblique inguinal or inguino-scrotal herniæ.

The greater frequency of this accident in oblique inguinal than in femoral hernia does not accord with the results of the experiments made by Jules Cloquet. He found that it was effected most easily in direct inguinal, then in crural, and lastly in oblique inguinal herniæ.

This is probably to be explained by the fact that in his experiments on the dead body Cloquet produced the reduction of the entire sac and its contents; whereas, according to Mr. Birkett, when reduction *en masse* is produced in oblique inguinal or inguino-scrotal herniæ, it results from the escape of the contents through an opening in one side of the neck of the sac.

In the present case, however, there can be no doubt that the neck and body of the sac were separated from the tissue surrounding without rupture of the neck, both because of the flocculent appearance of the exterior of the sac, which gave it the look of omentum, and because the intestine was at once, after opening the sac, returned into the peritoneal cavity, and not again into the pelvic pouch, as would have happened had the orifice of the sac been pushed back by a rupture of the neck.

Many conditions have been named as favorable for the reduction *en masse* of a rupture, but those most essential are, no doubt, the small size of the orifice of the sac, and the looseness of the connection between the sac and its neck and the surrounding parts. This latter is possibly an aggravation by age or debility, or some asthenic disease, of the pathological condition which permits of the occurrence of hernia at all.

It is impossible to say what amount of taxis had been employed before the patient was brought to the hospital; but the force used after her admission and at the time of the reduction was not only not great, but very slight, and it was seen at the *post-mortem* examination that the connection between the deep layers of the abdominal parietes was very loose and easily destroyed.

February 21*st*, 1871.

Digitized by Google

(B) DISEASES, ETC., OF THE LIVER.

14. *Biliary fistula in the abdominal parietes discharging bile.*

By C. MURCHISON, M.D.

ON the 11th of October, 1869, I was requested by Mr. Curling to see with him a married lady, about 40 years of age, who had a biliary fistula. For many years she had been liable to sudden paroxysms of severe pain in the right hypochondrium, accompanied by vomiting, but never followed by jaundice. In March, 1869, she first noticed a painful swelling in the abdomen, below the right ribs in front. Different opinions respecting this swelling were expressed by different medical men who were consulted. One was that it was a fibrous tumour, and another that it was an hydatid. The swelling increased, and as fluctuation became more distinct an opening was made into it in May, and many ounces of viscid, opaque, yellow fluid, without any trace of bile, came away. On June 3rd, a biliary concretion, not larger than a hemp-seed, was discharged through the opening, and early in September four others, somewhat larger and with distinct facets, came away. On September 18th she began to suffer from much pain about the liver in front and stretching round to the back, and after two or three days two other small concretions were passed and the pain was relieved. One week after this she awoke in the night with agonising pain in the right hypochondrium and back, and violent retching. After a few hours these symptoms subsided, but two nights later (September 27th) they returned and next morning she found her night dress and the bedding saturated with bile. From that time until I saw her, fourteen days afterwards, there had been a steady discharge of dark green bile from the fistulous opening, which was situated half way between the umbilicus and the lower edge of the ribs in the right nipple line. The fluid was discharged from the opening at the rate of from one to two ounces in the hour, sometimes more and sometimes less. It was usually increased after a meal. It had all the characters of pure dark green bile. The patient was losing flesh and strength rather rapidly, and suffered much from pain and flatulence after meals. The urine was dark and contained bile-pigment, and the motions were clay coloured, with no vestige

Digitized by Google

of bile, but there was scarcely any jaundice of the skin and conjunctivæ. Three days after I saw the patient (October 14th) another small biliary concretion was discharged from the opening, but there was no improvement in the general symptoms, and the patient continued getting weaker until about the 7th of November, when she had another attack of severe pain in the right side and vomiting, and next day she found that the discharge from the fistulous opening had almost stopped and that there was plenty of bile in the motions. Soon after this the opening in the abdominal parietes closed, the patient's general health gradually improved, and within a few weeks she was able to sail for the West Indies, where she has since enjoyed tolerably good health.

Although in many respects this case was a very remarkable one, the sequence of events can be easily explained. The several stages of the illness appear to have been as follows:

1. A concretion, which had formed in the gall-bladder, entered the cystic duct, causing paroxysms of hepatic pain and vomiting. It did not reach the common duct, and therefore there was no jaundice.

2. The cystic duct being closed, no bile could enter the gall-bladder; the bile already there was absorbed; the gall-bladder took on inflammation, and became distended with an opaque viscid fluid, forming a tumour which was appreciable though the abdominal parietes.

3. An opening was made into this cyst and its contents evacuated. A fistulous opening remained, which discharged viscid fluid and gave exit to several small gall-stones.

4. With a fresh attack of biliary colic and vomiting the concretion in the cystic duct was dislodged and passed into the common duct, which it obstructed. The result was that the bile was prevented entering the bowel, and, passing along into the gall-bladder, escaped by the fistulous opening.

5. With another attack of biliary colic and vomiting the concretion escaped into the duodenum, the flow of bile was restored to its proper channel, and the fistulous opening closed.

This appears to be the only possible explanation of the facts of the case, but on this view it is extraordinary that a concretion which had blocked the cystic duct for many months should ultimately have been dislodged and passed into the common duct; and that the common duct should have become pervious after complete obstruction by a

Digitized by Google

gall-stone for nearly six weeks was also almost more than, under the circumstances, there was a right to expect. Fistulous openings into the gall-badder, where the cystic duct is closed, are not very uncommon, but they are very rare in cases were the cystic duct is pervious and the common duct is closed. I have been able to find the records of only two such cases.[1] It is, of course, only in these last cases that bile is discharged from the fistulous opening. The quantity of bile secreted by the liver in this case could not have been much under two pints in the twenty-four hours, and this though the patient was taking very little food. This and other observations show that the quantity of bile normally secreted by the liver is much less than what is passed from the bowel, and that a large proportion of it must be constantly reabsorbed into the blood. Under ordinary circumstances the bile becomes transformed as soon as it is reabsorbed, and thus jaundice is prevented, but in certain morbid states of the blood or of the nervous system the normal metamorphosis does not take place, and jaundice, independent of any obstruction of the bile-duct, results. Again, calomel, podophyllin, and other aperients, when they bring away a great deal of bile from the bowel, do so, not in virtue of their increasing the secretion of the liver, but in consequence of their sweeping away the bile which has passed into the bowel before there has been time for its absorption.

I only saw the patient whose case I have now recorded on one occasion, and she was much too ill to warrant any experiments with regard to the action of drugs on the secretion of bile.

January 3rd, 1871.

---

15. *Sequel of a case in which gall-stones were discharged by a fistulous opening through the abdominal parietes.*

By C. Murchison, M.D.

In April, 1868, I communicated to the Society[2] the particulars of a lady between 50 and 60 years of age who had discharged gall-stones

[1] G. Robinson, 'Med.-Chir. Trans.,' vol. xxxv, p. 471; and Fauconneau-Dufresne, "La Bile et ses Maladies," 'Mém. d'Acad. Roy. de Méd.,' 1847, xiii, p. 325.

[2] 'Trans.,' vol. xix, p. 260.

Digitized by Google

through a fistulous opening in the abdominal parietes. In the autumn of 1866 she had suffered from an attack of biliary colic and jaundice, and in February, 1867, what was believed to be an abscess of the liver pointed below the right ribs and was opened. Nearly a pint of yellow pus, without any gall-stones or bilious tint, escaped. Pus and glairy mucus continued to drain away from the fistula resulting from this wound. The first gall-stone came away on the 28th of July, 1867, after considerable suffering, and eight other stones were discharged between that date and April, 1868.

Early in June, 1868, another stone, the tenth and last, came away. The opening continued to discharge thin pus, and it did not finally close till August, 1869, but since then it has shown no sign of reopening, and there has been no pain or induration in the vicinity of the cicatrix.

On September 27th, 1868, more than three months after the passage of the last stone, and while the fistulous opening was still discharging, the patient was again suddenly seized with rigors, vomiting and fever, but this time associated with urinary symptoms—frequent micturition, intense burning pain in the meatus urinarius, and the presence of blood in small quantity, and subsequently of pus, in the urine. These symptoms subsided after about a fortnight, but on November 8th pain, vomiting, and fever, returned in an aggravated form, and a very tender deep-seated swelling, about the size of a small orange, could be felt in the right groin half way between the crest of the ilium and pubes. The urine was now perfectly limpid and free from pus or blood. Sir Henry Thompson, who saw the patient with me in consultation, agreed with me in thinking that the swelling was connected with the right ureter. After a few days pus returned to the urine, which also contained many cystals of lithic acid, but no stone could ever be found. The tumour in the right groin could still be felt on November 30th, but it was much smaller, and it soon entirely disappeared, and the patient regained her usual health, the urine, however, still containing a little pus. In August, 1869, about the same time that the fistula in the abdominal parietes closed, the pus disappeared from the urine.

From this time the patient remained in good health until September 7th, 1870, when she was again suddenly seized with rigors, vomiting, violent paroxysmal pain in the region of the right kidney stretching round to the cicatrix, and in the right hip, much fever and frequent micturition, but the urine contained no blood or pus,

Digitized by Google

and there was no induration or swelling in the neighbourhood of the cicatrix. These symptoms continued in a more or less severe form till September 26th, when suddenly several ounces of pure pus were discharged with the urine, and on the following morning the stone (now exhibited) was passed from the urethra. All the severe symptoms at once subsided, and although the urine for some weeks contained a good deal of pus, this at last disappeared and the patient is now in good health, except that she suffers occasionally from aching and dragging pains in the region of the liver and right kidney.

The dimensions of the stone were as follows:—Length, $\frac{2}{3}$ inch; width, $\frac{1}{3}$ inch; thickness, $\frac{3}{20}$ inch. Its weight was 3 grains. It was analysed by Mr. Thomas Taylor, who found it to be composed of uric acid.

Before the passage of the stone, the previous history of the patient and the fact that the symptoms were evidently connected with the right kidney suggested the idea that a biliary calculus might have ulcerated its way into the pelvis of the right kidney, and obstructed the right ureter. There are at least two well-authenticated cases on record where biliary calculi have been voided with the urine, apparently owing to the formation of a fistula between the biliary passages and the pelvis of the right kidney.[1] One of the patients passed nine small and four large calculi; the other voided 200 small calculi within a week; in both patients an operation was necessary to remove one of the calculi from the urethra. In both cases the calculi were analysed and found to consist of cholesterine and bile-pigment, and in one the analysis was made by Gmelin, who also found bile-pigment in the urine. Neither of the patients ever had jaundice, and in both the symptoms were those of urinary rather than of hepatic disease; both recovered.

The analysis of the stone passed by my patient left no doubt that she was the subject of both renal and biliary calculi.

January 3rd, 1871.

[1] Fauconneau-Dufresne, 'Mém. de l'Acad. Roy. de Méd.,' 1847, xiii, p. 66; and 'Gaz. Méd. de Paris,' April 18th, 1840.

Digitized by Google

16. *Case in which a biliary calculus was passed from the umbilicus.*

By Dyce Duckworth, M.D.

T. W—, æt. 50, a gray-haired, rather pallid, but fairly nourished man, came to St. Bartholomew's Hospital on March 2nd, 1871, complaining of discharge from his navel, which he noticed first three days previously. On examination I found a slight purulent oozing from a small papilla at the superior and outer aspect of the umbilicus. There was swelling round this, and some induration likewise. The tumour received slight pulsation also. There was no other ailment. A linseed poultice was ordered to be applied at night, and some quinine was given. No further change occurred, and the same symptoms continued till the 29th March, when, on cleaning the wound, a hard substance was seen to protrude. With some difficulty and considerable pain a small concretion was caused to extrude. A little bleeding followed, but no further discharge, and on the 30th, when I next saw the man, the wound had closed and the swelling had almost subsided.

The patient was a wool-packer, and had always been a healthy and temperate man. For five or six months previously he confessed to have had uncomfortable sensations about the epigastrium, especially on stooping down. Never had jaundice or any illness corresponding to passage of a gall-stone.

The calculus weighed in its recent state thirty-one grains, when dry only eighteen grains. It floats in water. There is an appearance of a facet at one point. On section the calculus is seen to be disposed in layers, with a more or less white nucleus. On examination it is found to contain a large amount of cholesterine, with some bile-pigment.

It is not easy to speculate on the course this calculus may have taken, but it seems most probable that it had passed from the fundus of the gall-bladder to the umbilicus, and had not entered either the cystic or common bile-duct. *April* 18*th*, 1871.

Digitized by Google

17. *Fistulous communication between the gall-bladder and colon.*

By C. Murchison, M.D.

This specimen was obtained from the body of a woman, æt. 60, who died in the Middlesex Hospital on February 7th, 1870, of peritonitis following epithelial cancer of the uterus. She had always enjoyed good health till five months before death, when she was seized with severe abdominal pain, coming on in paroxysms, and attended by nausea and retching. She kept her bed for two days, but had no jaundice, and there was no evidence of her having passed any stone. This attack was followed by more constant pain in the uterine region, and possibly the severe initiatory pain may have been, as was thought during life, merely the first symptom of the uterine cancer.

At the autopsy the gall-bladder was found to be shrivelled into little more than a duct; it contained a little mucus not tinged with bile; the channel of the cystic duct was obliterated, and the fundus was inseparably adherent to the transverse colon, with which it communicated by a circular orifice, with smooth well-defined edges, and about four lines in diameter. There were signs of old inflammation about the fissure of the liver, the capsule of which was thickened, but the outer surface was smooth. The substance of the liver was firm and fibrous, but there were no cancerous masses, either here or in the neighbourhood of the gall-bladder or colon.

The fistulous communication in this case was probably the result of a large gall-stone having ulcerated its way through the fundus of the gall-bladder and the coats of the adherent colon. When, however, a stone escapes by this direct route into the bowel, it usually passes into the duodenum, and then, if the stone be large, it may cause fatal obstruction of the small bowel. I have collected the records of twenty-eight cases of fistulous openings between the gall-bladder and duodenum, mostly, if not all, from gall-stones; but the same search only yielded seven cases of a fistula between the gall-bladder and colon, and six of these seven were due to cancer.[1] In

[1] 'Clin. Lec. on Dis. of Liver,' 1868, p. 514.

Digitized by Google

the present case, although the patient died of epithelioma of the the uterus, the fistula was independent of any morbid growth.

April 18th, 1871.

---

18. *Jaundice from gall-stones, followed by acute atrophy of the liver, with puriform deposits.*

By C. Murchison, M.D.

James H—, æt. 66, was admitted into the Middlesex Hospital on October 11th, 1870. As a tailor he had led a sedentary life; he had lived well and had drunk a good deal of beer, but at no time been intemperate. Excepting slight cough and occasional symptoms of indigestion, and three attacks of gout in the big toe, he had enjoyed good health until seven weeks before admission, when he was suddenly seized in the night with violent pain in the epigastrium and right hypochondrium, frequent vomiting, rigors, and cold perspirations. On the following day he found that he was jaundiced. The jaundice disappeared after a few days; the pain and sickness continued to recur at frequent intervals, and a week before admission he had a severe attack, followed by jaundice, which persisted.

On admission, jaundice was the patient's prominent symptom; there was much bile-pigment in the urine, but none in the fæces. The liver was enlarged, measuring five and a half inches in the right nipple line. Excepting the jaundice, the patient's general aspect was that of a healthy man for his age. Pulse 60; skin cool; tongue coated; solid food was at once rejected by vomiting; bowels open by medicine. No albumen in urine.

On the following day, October 12th, the patient's condition was entirely changed. Pyrexia had set in; the pulse was 96, and the temperature 101·2°. The expression was heavy and stupid. No pain was complained of.

October 14th.—Tongue dry and brown down the centre. Jaundice and vomiting persisted. No rigors or perspirations.

Digitized by Google

16th.—Tongue dry all over; much thirst; bowels not open; frequent hiccup; drowsy and heavy, but did not wander. Pulse 92; temperature 100·6°; no rigors or perspirations.

17th.—Pulse 68; temperature 97·2° in morning, and 101·6° in evening. Urine contained much bile-pigment, and also crystals of tyrosine and leucine, but no albumen.

18th.—Pulse 84 to 120; temperature 100·1° to 103·1°. Much hiccup. Urine passed involuntarily.

19th.—Stupor increased. Urine still contained tyrosine, but no albumen. Liver appeared to be diminishing in size, and did not exceed four inches in the right nipple line.

22nd.—Pulse 80 in the morning, 140 in evening. Temperature 96·6° in morning, 102·2° in evening. Less hiccup; abdomen distended and tympanitic. Still much jaundice, but motions now contained bile. All day he lay in a heavy drowsy state, but in the evening he became very restless, tossing about and throwing off the bed-clothes. Hands tremulous; occasional delirium.

26th.—Pulse 100; temperature 101·2°. Urine still contained tyrosine and fair amount of urea, but no albumen.

27th.—Pulse 96; temperature 98·4° to 100°. Considerable delirium, and frequent attempts last night to get out of bed. Still no rigors or sweating. Urine contained a trace of albumen.

28th.—Pulse 128; temperature 103·2°.

November 2nd.—Pulse 80; temperature 96·8°; last night it was as low as 95·5°, and at no time during last two days has it exceeded 98·2°. Patient was still very restless, but much weaker. He was now almost unconscious, with occasional muttering delirium. Hepatic dulness in right nipple only three and a half inches. Jaundice decidedly less; bile in the motions. Urine copious; it contained very little bile-pigment, but a good deal of tyrosine, and about one twelfth in volume of albumen.

3rd.—Pulse felt with difficulty; temperature 98·6°.

4th.—Pulse scarcely to be felt; temperature 96·6°; voice feeble, and could not speak articulately; quite unconscious, restless and moaning; tongue dry and brown. Urine scanty; contains one twelfth in volume of albumen and much leucine and tyrosine, but very little urea; less jaundice; complexion dusky; no purpuric spots.

In the early part of the following night acute delirium set in, followed after some hours by great restlessness. At 5 a.m. of November 5th he became quiet, but his respirations were quick

Digitized by Google

(48). At 11.30 a.m. death occurred, being preceded by slight convulsions.

Autopsy.—Body thin; only faint jaundice of skin and tissues; no purpura-spots. No peritonitis, old or recent. Surface of liver smooth; capsule not thickened. Liver large and heavy, 94 oz., but not so much as three inches apposed to wall of chest and abdomen, the organ being soft and folded upon itself, and overlapped to an unusual extent by the right lung. On cutting into the liver it presented numerous patches of yellow opaque fluid having all the naked-eye characters of pus contained in cavities with well-defined walls, which were apparently dilated bile-ducts. These cavities varied from the size of a pea to that of a small cherry. Under the microscope the yellow fluid was found to contain a few pus-corpuscles, but to be made up chiefly of oily matter. The hepatic tissue was unusually soft, and of a yellowish or rhubarb colour. It contained many tracts where it was impossible to trace any outline of lobules, and where the liver cells were replaced by oil, granular matter, and round nuclei. No leucine or tyrosine could be found at first, but after the liver had been for some time in spirit it was found to contain many crystals of tyrosine. The gall-bladder contained more than twenty polyhedral calculi, about the size of peas. The cystic duct was so dilated that the little finger could be inserted into it. The hepatic and common ducts were also much dilated; the tip of the index finger could be passed into either of them. The duodenum for three or four lines round the orifice of the common duct was ulcerated. The duodenum contained bile, which could also be squeezed into it from the gall-bladder. All the ducts in the interior of the liver were dilated, and the hepatic duct contained three calculi larger than those in the gall-bladder, each being about half the size of a cherry. No gall-stones were found in the bowels. Spleen large and soft, 7¾ oz. The kidneys were congested; each weighed 6½ oz.; both were marked by old cicatrix-like depressions on the surface, and there were several small cysts in the cortex of the right; both kidneys also contained a few minute opaque yellow soft masses of pus; in other respects they appeared healthy. Heart 14 oz.; valves healthy. Lungs congested posteriorly, but otherwise healthy.

Remarks.—This patient's symptoms left no doubt that his illness commenced with the passage of gall-stones; but it was equally clear that there was some cause other than gall-stones, for jaundice which

Digitized by Google

persisted long after the motions contained bile, and which was accompanied by pyrexia, and the cerebral and other symptoms of the typhoid state.

Jaundice with fever and cerebral symptoms, and with bile in the motions, is due to one of three causes:—

1. A specific poison, such as that of yellow fever, relapsing fever, or typhus.
2. Pyæmic abscesses of the liver.
3. Acute atrophy of the liver.

With regard to the first cause there was no evidence that the patient was suffering from any of the acute specific diseases, so that the question to be decided was whether the patient had acute atrophy or pyæmic abscesses of the liver. The latter view was favoured by—*a*, the large size of the liver, and *b*, the fact that gall-stones are known to cause ulceration of the biliary passages, with secondary pyæmic inflammation of the liver. It was contra-indicated, however, by—*a*, the absence of rigors or profuse perspiration throughout the entire illness, although both these symptoms are sometimes absent in pyæmia from internal causes; and *b*, the fact that the liver diminished in size, instead of increasing as the disease advanced. Acute atrophy of the liver was contra-indicated by—*a*, the large size of the liver, and *b*, by the comparatively chronic course of the malady; but two facts were strongly in favour of it, viz., *a*, the circumstance that the liver diminished in size as the disease advanced; and *b*, the presence of leucine and tyrosine, and the diminution of the urea in the urine. The diagnosis arrived at was that the liver had become enlarged from obstruction of the bile-ducts by gall-stones, and that atrophy of the liver had supervened on this, and had continued after removal of the obstruction. Such cases are referred to by Frerichs in the following passage of his work on 'Diseases of the Liver.'

"In some cases when obstruction of the bile-duct has lasted for several months, it gives rise to an atrophy of the gland, which in many points resembles acute atrophy. The organ diminishes in size and becomes soft; the cells of the parenchyma, which are infiltrated with bile, become disintegrated into a finely granular débris, mingled with oil-globules and particles of pigment, while at the same time large quantity of leucine and tyrosine may be detected."[1]

[1] Syd. Soc. Transl., vol. i, p. 237.

Digitized by Google

In the case now recorded it is to be noted that the process of atrophy continued after the removal of the obstruction.

The autopsy in this case, however, disclosed not only atrophy of the hepatic tissue, but puriform collections in the liver. It is true that these collections were composed mainly of oily matter, yet the ulcerations at the duodenal orifice of the common duct, the great variations in the temperature observed during life, and the fact of a few minute deposits of pus being found in the kidneys, all suggested that the patient was the subject of pyæmic inflammation, as well as of acute atrophy of the liver. *January 3rd*, 1871.

---

19. *Malformation of the gall-bladder and hepatic duct.*

By H. H. Crucknell, M.B.

The specimen was taken from the body of a man, æt. 49, who died in the Great Northern Hospital under the care of Dr. Cholmeley.

The excretory apparatus of the liver is here so arranged that the whole of the bile must have passed through the gall-bladder on its way to the intestine.

The gall-bladder itself is much smaller than usual. When laid open it measured two inches in length and rather less in breadth. It would hold about two drachms of fluid.

In its upper or attached wall there are two openings, the larger one near the centre is the orifice of the principal hepatic duct, the smaller one nearer the fundus is the orifice of a cysto-hepatic duct.

The large ducts of the left lobe pass across the longitudinal and transverse fissures, where they become superficial, and join the principal duct of the right lobe shortly before it opens into the gall-bladder.

The cystic duct, which appears to be the sole channel of communication between the liver and duodenum, is, at its commencement, constricted, so as to admit nothing larger than a probe, but immediately below it dilates considerably.

Digitized by Google

I regret that at this point it was divided, and that the specimen fails to show the lower part of the duct and its termination in the duodenum.

The liver presented no other structural irregularities.

I have been unable to find any record of a similar case.

It is stated by Quain and Sharpey[1] that cysto-hepatic ducts, that is, ducts which pass directly from the liver to the gall-bladder, are occasionally found in the human subject; but in these cases it may be presumed that the principal hepatic duct retains its normal relation to the gall-bladder.

The arrangement described in this case, which appears to be so abnormal in man, is the normal one among some of the lower animals.

Thus, Professor Owen states[2] that in certain fishes (wolf-fish, erythrinus, lepidosiren), the bile is conveyed to the gall-bladder by hepato-cystic ducts, and thence by a cystic duct to the duodenum.

Again, in certain reptiles[3] (siren, amphiuma), the hepatic ducts communicate with the cystic or with the gall-bladder, and the bile is conveyed directly by the cystic duct to the beginning of the intestine.

In mammalia, on the other hand, as a rule, all the ducts unite into one trunk, which, in those having a gall-bladder, joins the cystic duct to form the ductus communis choledochus.

May 16*th*, 1871.

---

20. *Columnar epithelioma of the liver.*

By T. Whipham, M.B.

The history of the patient Eliza H—, æt. 34, from whose body the portion of liver exhibited to the Society was taken, extends over a period of two years. She was first admitted into St. George's Hospital under the care of Dr. John Clarke on Dec. 28th, 1868, in

[1] Fifth edition, vol. ii, p. 1077.

[2] 'Anatomy of Vestelvater,' 1866, vol. i, p. 427.

[3] Vol. i, p. 451.

Digitized by Google

order to undergo treatment for an abdominal tumour, which she had first noticed four weeks before her application to the hospital. Dr. Clarke pronounced the tumour to be ovarian, and kept her an in-patient for a few months. The disease, however, steadily increased, and she was sent out for change of air, as her health began to suffer from confinement in the hospital. On April 21st, 1869, she was readmitted. The abdomen was much distended—its circumference measuring thirty-three inches; fluctuation was distinct over the whole belly, and dulness existed everywhere but in the right flank; the part was, moreover, extremely tender. On June 1st parcentesis abdominis was performed and eight pints of clear orange-coloured fluid came away, and on the last day of the month she went out relieved. On Aug. 30th following, she was readmitted with burning pains in the iliac regions, which were, however, soon relieved by poultices; and on Sept. 3rd, she was again tapped, when about ten pints and a half of clear straw-coloured, albuminous fluid were removed. On the 29th she was discharged. Again, on Nov. 13th, she was readmitted and tapped. Again, on Jan. 15th, 1870, and for the fifth time on March 12th, when pus appeared for the first time in the contents of the cyst: the fluid removed on this occasion is described as "smoky." Between this last date and Aug. 19th five tappings took place, and on the last occasion eight pints of clear fluid with six pints of pus were withdrawn. She died eventually on Dec. 4th.

Examination of the body thirty-four hours after death.—The upper parts of the trunk and arms were much emaciated, while the legs were œdematous. The lungs were emphysematous, with some congestion and serous infiltration of the lower parts. The right side of the heart contained decolourised coagulum, and both ventricles were semicontracted; the mitral valve was thickened. On opening the abdominal cavity, a large sac, distended with fluid contents, presented itself, between which and the abdominal walls firm and extensive adhesions existed, both anteriorly and laterally. The intestines lay behind it. The fluid contents were found to be thick creamy pus, and springing from its inner surface were several smaller cysts, also containing pus. Many other cysts varying considerably in size were found involving both ovaries, but from the extent of the disease it was impossible to determine in which of these organs it had originated. A clear gelatiniform fluid filled some few of the cysts in which suppuration had not yet commenced.

Digitized by Google

This fluid, when examined microscopically, was found to be structureless, and its enclosing wall simply fibrous tissue, in which no traces of malignant growth could be detected. The uterus was natural. The spleen was large, dark-coloured, and though lardaceous in appearance gave no reaction with solution of iodine.

The kidneys were anæmic, with smooth surfaces and prominent Malpighian tufts. They were not lardaceous.

The liver weighed seventy-seven ounces, was of a pale yellow colour, and the margins of any section were sharp, as in lardaceous disease. No reaction, however, was obtained from the application of the iodine solution. To the naked eye the organ was undoubtedly fatty, and in addition to this degeneration it was characterised by the presence of a number of rounded growths, scattered throughout its substance, but more numerous on the surface, immediately beneath the capsule, than in the interior of the organ. These growths were on an average of about the size of a common marble, some rather larger, others less—considerably. There were all of an uniform pink colour, and semitransparent appearance; they were not elevated above the surface of the liver, as, for example, are the nodules of encephaloid cancer,—if anything, the centre of each mass was, in the recent state, somewhat depressed. But little juice could be squeezed from the cut surface of any of them, and in no single instance was any tendency to softening discovered. Sections of the least of these growths (for whether large or small their naked-eye appearances did not differ) were examined microscopically, when various differences were observed in the characters of the tumours. In some parts large, irregularly shaped, nucleo-nucleated cells were found packed together and enclosed by fibrous walls, after the manner of ordinary cancer. But in other places the growth was found to consist of flat cells, also contained in fibrous walls, forming loculi of various shapes; some round, others oval, others elongated, so that with the enclosed walls an appearance as of a gland tube somewhat convoluted and lined with epithelium was produced. The various shapes of these cell-containing cavities were, however, doubtless due in some measure to the direction in which the section was made. The most remarkable point, however, in these growths lay in the character of the epithelium lining the tubes. In some parts of each section examined, the cells in these elongated cavities were flat or angular, in fact, they had very much the appearance of those seen in ordinary epithelioma, while in other parts their

Digitized by Google

epithelium was distinctly columnar, the cells being arranged perpendicularly to the walls of the tube; the resemblance to a gland structure being thereby rendered more complete. The tubes themselves were without definite arrangement, and were separated only by delicate fibrillated stroma, among the meshes of which bright nuclei were scattered. In other parts of the section large oval-shaped growths were found, whose walls, composed of dense fibrous tissue, enclosed a delicate stroma with nuclei scattered in its meshes. From the outer side of these fibrous walls offshoots were given, which enclosed and formed loculi for such of the tubular growths as were in the immediate neighbourhood; and in many places the cellular masses were aggregated around these fibrous capsules. In parts of the liver, unaffected by the epithelial growth, a fibrillated network with nuclei, similar in all respects to that contained in the above-mentioned fibrous capsules, encroached upon and compressed the liver cells. In other places the microscope confirmed the naked-eye appearances of extreme fatty degeneration; so much so, that in sections, which had been mounted in Canada balsam, almost all traces of the cells had disappeared.

Cornil and Ranvier,[1] in their account of epithelioma, have described two forms of the disease, which they call "épithéliôme tubulé" and "épithéliôme à cellules cylindriques," and to both of these the disease in the liver exhibited bears considerable resemblance. Those tubes in the growth which were lined with paviment epithelium answer in the main to the description of épithéliôme tubulé, but with these differences—that they did not anastomose, that they were of a pink, not gray colour, nor did they show any tendency to break down: three points which, according to these pathologists, for the most part characterise épithéliôme tubulé. On the other hand, the tubes lined with columnar epithelium answered in great measure to the description given of the latter, viz., épithéliôme à cellules cylindriques. But even here some remarkable differences existed: according[2] to Cornil and Ranvier when columnar epithelioma is, as often happens, propagated to the liver, it presents all the appearances of encephaloid cancer. In this case, supposing the disease to have been secondary to that found in the ovaries, their statement is not corroborated, for the semitransparent pink colour of each tumour, together with the depressed centre serve, to distin-

[1] 'Manuel d'Histologie Pathologique,' p. 276.

[2] Ibid., p. 281.

Digitized by Google

guish this disease, even in the absence of the microscope, from encephaloid cancer as ordinarily seen. Again, at page 283 of their work, the tendency of this form of epithelioma to soften, is especially insisted upon, when the disease affects mucous cavities, and the softening is ascribed to the action of various fluids, such as the gastric juice, with which it may be brought into contact. In this instance, however, as the growth occurred in the liver no such conditions were present, and consequently the total absence of any softening is no argument against its being columnar epithelioma. Rindfleisch, in his 'Lehrbuch der Pathologischen Gewebelehre,' page 405, under the head "Cancroide," has described an adenomatous growth in the liver, to which the specimen exhibited bears some resemblance in many places; but in his description the tubes are placed in such close proximity that their shape is altered by mutual pressure, whereas, in this case an intertubular, fibrillated stroma was constant, and no alteration in the form of the tubes had taken place. Again, according to Rindfleisch, the epithelium in this cancroid disease is of the pavement variety, a fact which distinguishes it from a growth, such as that exhibited, where the cells were distinctly cylindrical. Moreover, with regard to the naked-eye appearances in "Cancroide," he states that the tumours are soft, elastic, of a light liver-brown colour, but that occasionally some few of the nodules are somewhat darker, whereas the tumours shown differ from this description entirely, save only that they were more or less elastic. A tendency to soften in these adenomatous growths, mentioned as characterising them in their later stages, also more or less distinguishes the two diseases.

A most interesting point in this case would seem to be the question as to whether the disease affecting the liver was primary or secondary. In favour of its being secondary is the fact that both ovaries were alike affected with cystic disease, which may possibly have been of a malignant nature. But against it is the fact that no traces of cancerous growth were, after careful microscopical examination, discovered. Moreover, cysts of a non-malignant nature are frequently found affecting both ovaries in the same subject. Again, supposing the disease in the liver to have been secondary, it seems improbable, seeing that the stomach and intestines were perfectly healthy, that with such abundant growth in that organ others intermediate in the circulation should have escaped. Cornil and Ranvier, at page 284 of their manual, assert

Digitized by Google

that columnar epithelioma, save in the case of the ovary, never occurs primarily except in mucous tracts whose epithelium is columnar in the normal state, *i.e.* (among others) in the biliary canals. The present case may be an instance of this, though, owing to the extent of suppuration in the ovarian cysts, which may have obliterated the evidence of cancerous disease, the matter must unfortunately remain undecided. *April 4th*, 1871.

Report of the Committee on Morbid Growths upon Dr. Whipham's case of columnar epithelioma of the liver.—We have examined thin sections from the masses in the liver, and have to report that whilst these nodules present all the naked-eye characters of secondary deposits in their number, small size, and general appearance, their microscopic structure is of singular interest. We have little to add to the description already furnished by Dr. Whipham, from which it is evident that the growths correspond in most respects with the columnar-cell epithelioma, as described by Förster, Cornil and Ranvier, and other pathologists. There are, however, certain points about these tumours which have not been generally described in this form of disease. Thus, whilst in some places the alveolar fibrous stroma limits small round and oval spaces which are distinctly lined by large columnar epithelium, in others a different structure is apparent. In these the cells are contained in like alveoli, but differ greatly from columnar epithelium in shape. Such cells are closely packed, have no arrangement resembling a regular lining of the alveolar walls, and are of various sizes and shapes, round, oval, or compressed into the varied forms of the cells commonly met with in ordinary carcinoma. Indeed, from their general appearance and distribution, these cells and their alveoli could not be distinguished from such cancer as is met with in the female breast. They are neither so large nor so coarse as the cells of a squamous epithelioma, nor is there any apparent indication of the formation of "globes épidermiques." Besides these two structures, which make up the bulk of the growths, there are singular masses of growing fibrous tissue—the so-called adenoid tissue. These masses are more rich in nuclei and stain more deeply with carmine at their margins, and frequently enclose in their midst a divided bile duct, or at least a small cavity lined with columnar epithelium. Occasionally, tracts of the like fibroid tissue stretch out from these larger islets, which seem to be transverse sections of the largest of such bands, but they

Digitized by Google

cannot be traced to bear any constant and definite relation to the other parts of the new growth.

There would seem, therefore, at first sight to be in this case two different forms of disease, viz., ordinary carcinoma and epithelioma. Might it not be possible that these tumours were secondary to a primary growth elsewhere of an ordinary carcinomatous structure, which, infecting largely the bile ducts, led to a correspondingly large proliferation of cells conforming more or less closely to a columnar epithelial type?

WM. CAYLEY.

16*th May*, 1871. HENRY ARNOTT.

Digitized by Google

V. DISEASES, ETC., OF THE GENITO-URINARY ORGANS.

(A) KIDNEYS, BLADDER, ETC.

1. *Cyst connected with the left kidney, associated with medullary cancer of the liver, lungs, and left kidney.*

By HENRY MORRIS, M.B., for Mr. MORRIS, of Petworth.

THE man from whom the tumour and viscera were removed was a patient under Mr. Morris, of Petworth, from whom the following notes were obtained. He was sixty-nine years of age, and had enjoyed good health till two years and a half ago, when he came under treatment for a swelling the size of a cricket ball situated to the left and somewhat below the level of the umbilicus; it gave him no pain and did not follow any injury. His urine was albuminous, and once or twice contained a little blood. This, however, soon passed away under treatment, but the tumour very slowly increased. At Christmas, 1869, it was prominent, firm, globular, not fluctuating, and appeared more like a fibrous tumour of the abdominal wall than anything else. There was no dulness in the loin.

In August, 1869, the tumour had much increased, occupied the whole of the left half of the abdomen and reached somewhat over the right side of the median line; it fluctuated distinctly and in every direction, was fairly movable laterally and from above downwards, and the abdominal wall was tightly stretched over it. During this and the two or three preceding months he had several attacks of syncope, which occurred generally after taking exertion or eating his midday meal. A puncture with a fine trochar and canula, made in the most depending and elastic part, succeeded in drawing off only a drop or two of dark bloody fluid.

In July, 1870, the tumour occupied nearly the whole abdominal cavity and projected forwards, looking exactly like an ovarian tumour. There was still marked fluctuation throughout. He was emaciated and debilitated to a degree, and his face was haggard

Digitized by Google

looking and pinched; there was no albumen, blood, or pus, in his urine. From this time he continued to lose strength rapidly; for the last eight weeks of his life he entirely kept his bed, and he died on October 4th.

Post-mortem examination.—The greater part of the abdominal cavity was occupied by the large fluctuating cyst which sprang from the left side of the lumbar vertebra and projected forwards from behind the peritoneum, pushing the small intestines, which were quite free of the tumour, downwards into the right iliac and the pelvic regions. The transverse and descending colon were adherent by their mesocolon to the growth, and formed an arch over and towards the posterior aspect of it. Posteriorly, the head of the pancreas and the lower end of the spleen were adherent to it. The tumour was intimately connected and removed from the body with the left kidney, the ureter of which with the spermatic artery and vein took a very curved direction to the groin along the back of the cyst. Before removal, the left kidney occupied a nearly transverse position in the loin; its upper half, or that nearest the supra-renal capsule, was normal, but the rest was spread out in a thin layer over the surface of the base of the cyst. In this expanded portion was a second small transparent cyst the size of a currant. The capsule of the kidney was continued over the cyst. The pelvis of the kidney was not much dilated, but some of the calyces were seen extending into that part of the kidney that was spread out over the base of the cyst. The ureter, near the pelvis of the kidney, was large enough to admit the little finger, but in the greater portion of its course it was of normal size and closely adherent to the back of the cyst. The cyst itself (which weighed about sixteen pounds and measured, after it had been in spirit some time, twenty-nine inches in vertical and twenty-six inches in transverse diameter), was filled with a dirty brown fluid, and coffee-ground coloured blood clot. This clot was deposited in layers within the cyst, and on section cut like firm butter, and presented a yellowish-brown appearance. There were indication of recent blood extravasations. The cyst wall was not of uniform thickness throughout but averaged about one eighth of an inch. Its outer surface was smooth except where uncovered by peritoneum, and was marked by large veins passing over it; branches of the renal artery and vein were traced into and on to it. In the upper portion of the left kidney was a soft white nodule, the size of a marble, of medullary cancer; another

Digitized by Google

smaller nodule existed close to the junction of the cyst and kidney. The right kidney was small and contained several cysts, varying in size from a pin's head to a large pea or larger.

The liver contained several nodules of medullary cancer; those in the left lobe were the largest, but did not vary in size much; one was as large as a walnut; those in the right lobe were smaller and seated chiefly near the surface. Both lungs and their pleural covering contained many nodules studded upon and within them; these also had a true medullary character.

This cyst evidently sprang from the kidney substance, and was not formed, like cases of hydronephrosis, by a dilatation of the pelvis from obstruction in the ureter or elsewhere. The presence of the cancer was, no doubt, merely a coincidence and had nothing to do with the size or character of the tumour.

The appearance presented by the growth in the later stages of its existence exactly simulated ovarian tumours and might, had it occurred in a female, easily have been mistaken for that disease. Not so, however, in its early and middle stages for then its position would have contra-indicated its origin: it grew not from but towards the pelvis.

The large quantity of blood clot in the cyst no doubt explains the attacks of syncope which occurred at intervals.

October 18*th*, 1870.

---

2. *Encephaloid disease of the kidneys.*

By John W. Trotter.

They were removed from the body of a soldier, æt. 30, of twelve years' service. He was of muscular frame, and had always enjoyed good health up to the time of admission into hospital, July 15th, 1870, for an attack of hæmoptysis, at which time there was comparative dulness, with prolonged expiration below the right clavicle; subsequently, till his death on November 3rd, 1870, he had frequent attacks of hæmoptysis; the right lung became rapidly dis-

Digitized by Google

organised, and ultimately there were all the physical signs of a large cavity.

Post-mortem examination.—There was a small tumour on the right side surrounding the fifth rib, at its junction with the cartilage, and another on the left side over the centre of the fourth rib. They were both unconnected with the neighbouring tissues, and encephaloid in character. The upper lobe of the right lung was entirely destroyed, and the others infiltrated with malignant deposition. The left lung was non-adherent, but had aggregated masses of malignant disease scattered throughout, but in no part was there any softening.

The normal structure of the upper lobe of both kidneys had disappeared and been replaced by malignant deposit, encephaloid in character. No trace of the disease was found in any of the other organs. The urinary secretion had been profuse throughout his illness; nor had anything abnormal been detected in it.

Portions from the several specimens were examined under the microscope and pronounced to be encephaloid cancer.

December, 1870.

---

3. *Unnatural extension of kidney.*

By Heywood Smith, M.B.

Dr. Heywood Smith exhibited an enormous kidney removed from the body of a woman, the subject of pyonephrosis, who had died in the Hospital for Women after the kidney had been tapped for the fourth time. The origin of the mischief was found to be an irregular calculus lodged in the lower angle of the pelvis.

The following is a sketch of the history of the case:

M. R—, æt. 27, married four years, was admitted into the Hospital for Women, December, 1870. She had had one child three years ago, having been delivered, 'with instruments,' of a fœtus between the seventh and eighth month of utero-gestation. She recovered well. Had always had good health up to the time of her confinement. Four months afterwards began to feel pain and swelling in the left

Digitized by Google

lumbar region, which gradually increased. About six months afterwards she was admitted into St. Bartholomew's Hospital, under Dr. Greenhalgh, and transferred to Dr. Southey, then to Mr. Savory, who tapped her three times. The first time only a little bloody fluid escaped; the second, thirty ounces of thick yellow matter; and the

WOODCUT 7.

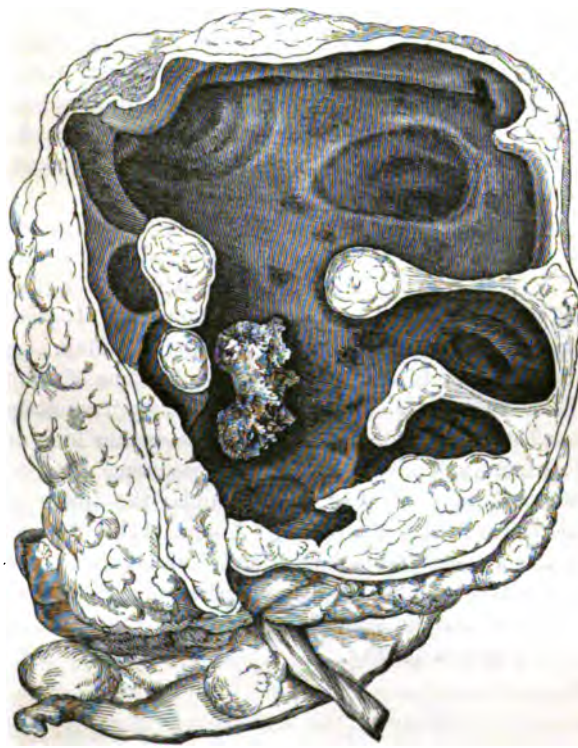

third time, twenty-four ounces of fœtid pus. The operations did not reduce, but for a few hours, the size of the tumour. Says the urine has been thick for eleven years. The urine is neutral; it has a sediment of pus equal to one third of the bulk of the water; there is also a little blood. She became out-patient at the Hospital for

Digitized by Google

Women in November, 1870. The vaginal examination then revealed a somewhat hard semi-elastic mass bulging into the vagina to the left of the uterus; the uterine sound passed two and a half inches towards the right foramen ovale. There was a large tumour extending from below the edges of the ribs on the left side down to the pelvis; it was hard, and rather tense; fluctuation was distinct in the lumbar region, and also, but indistinctly, through from the abdomen to the vaginal portion of the tumour. In the region of the liver was a mass (liver), very hard and extending across the mesial line.

December 12th, 1870, the patient was tapped through the abdomen with Dr. Protheroe Smith's exhausting needle trocar, when twenty-eight ounces of a very fœtid, pale brown, thick fluid was drawn off, which partly coagulated after its removal. The patient sank the next day, probably from some of the fluid escaping from the puncture into the cavity of the peritoneum.

Necropsy.—Liver very much enlarged, albumenoid, and slightly fatty. A tumour occupied the whole of the left side from the false ribs to the pelvis, extending about one inch and a half across the mesial line; it reached backwards to the spine. It proved to be the left kidney; on being opened it was found to contain about half a pint of fluid similar to that drawn off at the time of the tapping. Rather below the centre of the pelvis lay a very irregularly shaped and somewhat rough calculus, about three inches long and four-fifths of an inch in diameter; it weighed one ounce.

The whole kidney weighed nine pounds; the lower part was wedged downwards into the pelvis. A remarkable feature in the specimen was a considerable deposit of fat between each pyramid.

The *right kidney* was slightly hypertrophied, but otherwise healthy; *spleen* enlarged somewhat; *uterus* pushed to the right side of the pelvis; *ovaries* healthy. *January 3rd*, 1871.

Digitized by Google

4. *Atrophied kidneys, causing fatal uræmia, in a youth aged eighteen.*

By C. Murchison, M.D.

This was one of the most remarkable cases of renal disease which has ever come under my notice, and was a good illustration of the value of temperature in assisting diagnosis.

Walter F—, æt. 18, a footman, was admitted into the Middlesex Hospital on May 9th, and died on May 13th, 1871. His family history was good; his father and mother were both alive and well; he had one brother and one sister, also alive and well, and there had been no others in the family. When a child he had passed through measles and hooping-cough, but he never had scarlet fever or small-pox. Five years ago he was confined to bed for four months with great pain and swelling in the throat and neck, with dysphagia. He was quite unable to swallow solid food. There was no rash or desquamation of the skin, and neither then nor at any other time of his life had he ever dropsy. He drank about a pint and a half of beer in the day, and his habits had at all times been temperate.

Ten days before admission, and a day or two after entering upon a new situation, he was seized rather suddenly with pain at the pit of the stomach, palpitations, and dyspnœa on exertion. Two hours before, he had carried a heavy tray full of plates for a distance of fifty yards, and although he had experienced no inconvenience at the time he attributed his attack to this cause. The symptoms just mentioned continued; he lost his appetite, and was obliged from the first to give up all work, although he did not take to bed up to the time of admission into hospital. Five days before admission he first complained of shivering and pain in the loins, and after that he became very drowsy; but he had no fit and no headache, and stated that he had passed urine as usual.

His state on admission was as follows:—His body was well nourished and showed no sign of chronic disease, and there was no notable anæmia, and not a trace of œdema. He still complained of pain in the back and epigastrium, and of great debility. He had a

Digitized by Google

heavy, stupid expression of countenance, and was very drowsy, but he could be easily roused, and he answered questions correctly. Tongue dry and brown all over; breath ammoniacal and very offensive; sordes on teeth; thirst, but no appetite; bowels open; no vomiting or tenderness at the epigastrium; pulse 88, regular, soft; apex of heart beats between fifth and sixth ribs rather tumultuously; transverse dulness does not exceed one inch and three quarters; no bellows-murmur; respirations 26, irregular and sighing; nothing abnormal could be discovered in lungs; no eruption on skin; shivered and complained of a feeling of great cold; temperature in the axilla, and also under the tongue, 95·4° Fahr. No urine had been passed for five and a quarter hours before admission. A catheter was at once introduced, but only three fluid ounces could be obtained. This was limpid and colourless, like water; specific gravity 1007; it contained phosphates and a decided, though small, trace of albumen. A warm bath, croton oil by the mouth, and a mixture of acetate of potash and ammonia and digitalis, with diluents, were prescribed.

May 10th.—Temperature 95·6°. Urine sixty-six fluid ounces in twelve hours; specific gravity 1010; contains rather more albumen and 277 grains of urea. Appearance somewhat improved; rather less drowsy; slight headache; bowels acted, but not freely. The croton oil was repeated.

11th.—Temperature 97·6°. Urine forty-two fluid ounces in twenty-four hours; specific gravity 1010, and contains one twelfth in volume of albumen, and only 194 grains of urea. More drowsy and less easily roused; bowels opened.

12th.—Temperature 96. Pulse 72. Urine only twelve fluid ounces in twenty-four hours; specific gravity 1010; contains a mere trace of albumen and only sixty-three grains of urea. General condition worse. More prostrate and heavy; great restlessness, and noisy, irregular breathing; less easily roused, and mind wanders occasionally. Tongue dry, crusted, and tremulous. A bladder of ice was applied to the head, two drops of croton oil were given by the mouth, and a drachm of the infusion of digitalis was ordered to be taken every three hours.

13th.—Temperature at 10 a.m. 84° Fahr. in the rectum. Surface of body and breath cold. Urine twenty-three fluid ounces in twenty-four hours; none passed in bed; albumen increased to fully one sixth of volume of urine; 121·9 grains of urea. Pulse at wrist imper-

Digitized by Google

ceptible. Respirations 24 and noisy. At 6 a.m. this morning had slight general convulsions, followed by semi-coma and twitchings of the limbs. At 5 p.m. he had a return of general convulsions, and at 6.25 p.m. he died comatose.

Autopsy.—Blood everywhere dark and liquid. Brain healthy; no increase of cerebral serosity or of blood in cerebral vessels. Heart and blood-vessels healthy. Lungs moderately congested, but in other respects healthy. Liver intensely congested, but otherwise healthy. Spleen small, weighed only three ounces; no fibrinous deposits or scars. Supra-renal capsules of normal size and structure. The only organs diseased were the kidneys, both of which were extremely small, the right weighing only one ounce and a quarter and the left three quarters of an ounce. Their measurements were as follows:

Length	right 3· inches;	left 1·9 inch.
Breadth	„ ·2· „	„ 1·1 „
Thickness	„ ·7 „	„ ·7 „

Both organs were divided into lobules by deep fissures, and the capsules were adherent, particularly at the parts corresponding to the fissures. The outer surface, after removal of the capsule, presented no granulations, but at one part of one kidney there were a few small cysts visible to the naked eye. On section the organs presented no division into cortical and pyramidal substances, but only a uniform, pale, firm tissue, which on microscopic examination showed very much the same characters as those of an ordinary contracted granular kidney. There was a great increase of the fibrous tissue separating the tubes and surrounding the Malphigian bodies, and there were also numerous microscopic cysts. The epithelium in the uriniferous tubes contained a considerable amount of oil. The renal arteries were about one third of the normal size, but pervious. There was no dilatation of the pelvis, calices, or ureter of either kidney. The bladder and urethra were healthy.

The blood from the cerebral sinuses and veins was analysed by Dr. Cayley, and found to contain a considerable quantity of urea.

Remarks.—The sudden commencement of the patient's illness, its short duration, and the typhoid symptoms which he presented when brought to hospital, at once suggested the idea that he was suffering from some specific fever or acute local inflammation. There was, however, no eruption on the skin, and no other pathognomonic

Digitized by Google

symptom of any known acute, general, or local disease, while the temperature was of itself sufficient to exclude both of these conditions from being the cause of the typhoid symptoms, and to direct attention to the kidneys. Analysis of the urine made it clear that the symptoms were due to some disease of the kidneys interfering with the elimination of urea, but it was not so easy to say what the nature of the renal disease was. It was not acute nephritis, for there was neither anasarca nor pallor of the surface; the characters of the urine were very different from the smoky, highly albuminous urine containing blood, renal epithelium, and casts, of acute nephritis; and, moreover, in this disease the temperature, in the first instance at all events, is above the normal standard. Fatty kidney was negatived by the short duration of the symptoms, by the absence of pallor and anasarca, and by the urine containing only a trace of albumen and no fat-cells or casts. Lardaceous disease of the kidney was highly improbable from the absence of a history of any of the known antecedents of lardaceous disease, from the absence of any disease of the liver or spleen, from the small quantity of albumen in the urine, and from the fact that lardaceous disease rarely gives rise to uræmia. Destruction of the secreting tissue of the kidneys by pyelitis could not be accepted as the lesion, for there was no pus in the urine, and there was no history of renal calculus, tubercle, or urethral stricture. Altogether, the facts of the case—the absence of dropsy and pallor, the urine of low specific gravity, containing only a trace of albumen, and the uræmic symptoms—were most in harmony with the characters of the contracted or granular kidney. Moreover, it is well known that this form of renal disease may exist for years in a very latent form, there being no suspicion of its presence until the occurrence of uræmic symptoms, which prove fatal in a few days. Cases answering to this description have not unfrequently been sent into the London Fever Hospital, the attack having been mistaken for one of typhus. But what was extraordinary on this view of the case was the patient's age. Uræmia from contracted granular kidneys is rarely met with in persons under forty-five years of age. My patient was only eighteen; and, moreover, he had led a temperate life and had never suffered from gout, nor was there any evidence of gout in his family. All that could be said positively during life respecting the nature of his attack was, that there was a disease of the kidney which had in great measure destroyed the secreting tissue, which clinically was analogous

Digitized by Google

to the contracted gouty kidney of elderly people, but which was probably pathologically distinct.

This view of the case was confirmed by the post-mortem examination, which still left some doubt as to the true pathological origin of the renal lesion. The deeply fissured condition of the kidneys, and the intimate adhesion of the capsule to these fissures, suggested that the kidneys had at one time been the seat of fibrinous deposits similar to those which are ascribed to embolism, but which are now known to occur in certain morbid states of the blood independently of actual plugging.[1] These fibrinous deposits may have taken place during the serious illness from which the patient suffered five years before death, the history of which more resembled one of diphtheria than anything else. But from whatever cause resulting, they would destroy extensive portions of the renal tissue, and in process of time would become absorbed, leaving fissures corresponding to those actually present in the kidneys now before the Society. The fissures, however, in the kidneys did not exactly resemble the scars resulting from old embolisms, and the lobulated character of these organs had, on the whole, more the appearance of a permanent fœtal structure, or that of the kidneys of some of the lower animals. It is to be noted also that there were no signs of embolism in the spleen.

Whatever view be taken of the renal lesion, it is quite clear that it had existed for a long time prior to death, and it may seem extraordinary that the patient should apparently have enjoyed good health until the sudden outburst of the symptoms which terminated in death. But, as already stated, a similar observation is every now and then made with regard to the contracted granular kidneys of middle and advanced life. The secreting tissue of the diseased kidneys may suffice for the ordinary work of elimination, but some alteration in the diet, an act of intemperance, or a slight and transient febrile disturbance of the system, throws additional work upon the kidneys, which at once break down. It is quite possible, with regard to the patient whose case is now recorded, that the change of living consequent upon his entering a new situation may have helped to precipitate the fatal attack. At all events, it is difficult to conceive

[1] See for example case recorded by me in the last volume of the Society's 'Transactions' (Vol. XXI, p. 414), of relapsing fever, with fibrinous deposits in the kidneys, spleen, &c.

Digitized by Google

how the cause to which the patient himself referred his last illness could have had much to do with it. *May* 16*th*, 1871.

(B) MALE GENITAL ORGANS.

5. *Cancer of an imperfectly descended testicle, with greatly thickened peritoneum.*

By Henry Arnott.

The patient from whom I removed this specimen was lately admitted into the Middlesex Hospital under my care with the following history :—The man was a butcher, æt. 50, and had always enjoyed good health. Fifteen months ago, whilst endeavouring to tether a calf, the animal butted at him from behind as he stooped, and struck him severely on the perinæum. After this he soon noticed the left testicle, which had never completely descended into the scrotum, to be swollen and tender. Last May it began to increase rapidly, with much pain, and in July the man came to me at the hospital. There was then no sign of constitutional taint, but a large, pear-shaped, hard mass lay in the left side of the scrotum, adherent to the skin, nodulated, and evidently fluid-containing in some positions. The hard swelling extended far up the course of the cord. After tapping and so evacuating two or three ounces of thin bloody fluid, an irregular hard mass occupying the site of the testis remained, and the swelling along the inguinal canal was unaffected. The hardness and nodulation of the swelling suggested enchondroma rather than cancer, and it was resolved to remove the testicle. This was done in the usual manner, and I found that the swelling in the inguinal canal was due to an enormous thickening and induration of the peritoneal pouch, which had descended with the testicle, so that my finger could be passed up the rigid tube into the belly. This tube was tightly tied before the tumour was removed, and the man recovered without a bad symptom.

On cutting into the mass after removal it was found that the

Digitized by Google

whole testicle was converted into soft cancer, the tunics being greatly thickened and indurated.

Examined under the microscope, the following structure was displayed :—The main bulk of the tumour, that portion which apparently took the place of the body of the testis, had no longer in any part true testicle-tissue remaining. In its place was a richly cellular tissue, so rich as to seem to consist wholly of cells when a thin section of the softer outside portion was examined by a low power. More careful search discovered a well-marked fibrous network running amongst the cells and dividing these into clusters of variable size. Beyond this there was, except in some few portions, no trace of granular substance between the cells, which seemed to float in a clear fluid. Hence, around the borders of such sections innumerable cells were always seen floating out into the glycerine in which the slice was immersed. The cells themselves, of various size and shape, were for the most part of a round or oval figure, and contained a single large nucleus. Some, however, were tailed or of other irregular shapes, and a few contained multiple nuclei. The same description applies to the part of the tumour which from its position and comparative size probably occupied the site of the former epididymis. I have said that there was comparatively little trace of fibrous stroma. Sections taken from the portion of the tumour invested with the thickened remains of the tunica albuginea and tunica vaginalis, and carried through the thick membranous structure, showed beautifully the transition from the fibrous to the cellular portion and the relations of these to one another. Thus, the thickened tunic itself was made up of broad, dense, homogeneous-looking bands, partially fused together and leaving at irregular intervals narrow slit-like meshes, in which, perhaps, a few granules or a minute corpuscle or two were imbedded—in short, the structure familiar to those accustomed to examine inflammatory induration-tissue, whether this occur in the lungs of a patient with so-called "fibroid phthisis" or in the floor of an indurated ulcer. But as this tough fibroid tissue approached the soft mass of the growth the slit-like meshes increased in size, and in place of the granules or small round corpuscles a few large nucleated cells were met with, and then, perhaps, the fibrous bands would cease abruptly and broad tracts of cells come into view, running into which would be seen detached, narrow, homogeneous fibres of the induration-tissue, which then formed the open mesh-work pervading the whole mass.

Digitized by Google

The specimen is exhibited as much on account of the difficulty attending the diagnosis of the case as for the interest of the microscopic sections illustrating one form of extension or development of cancer.

The tumour is now in the museum of the Middlesex Hospital.

November 1st, 1870.

---

6. *Scrotal tumour; hæmorrhage into subcutaneous cellular tissue, with great subsequent inflammatory thickening of the surrounding parts.*

By Henry Arnott.

The patient from whom the specimen was obtained was a Spaniard, unable to speak English, and unable to give any clear history of his symptoms. The only points definitely stated were that the scrotum had been greatly swollen for many months, that there had been no blow to cause the swelling, that this had been increasing gradually, and that the Spanish surgeons consulted being unwilling to operate on what they deemed a cancerous tumour, the gentleman had come to England, and in June, 1870, sought the advice of Mr. Quain. Mr. Quain, thinking more favorably of the case, resolved to remove the tumour, and was good enough to allow me to assist at the operation and subsequently to examine the mass and bring it to this Society.

The man was between fifty and sixty years old and seemed in good health. The left side of the scrotum was the site of a firm tumour, the size and shape of a cocoa-nut, somewhat elastic, but hardly fluctuating, the skin over it tense and bound to the mass beneath. There was a large reducible inguinal hernia, which could be kept out of the way with a truss, and the inguinal glands were not enlarged. On thrusting a small trocar into the swelling no fluid issued until it had penetrated for nearly two inches, when a stream of thin brown fluid escaped with considerable force. An elliptical piece of skin was removed with the mass, the remainder being with difficulty stripped

Digitized by Google

from it, the spermatic cord secured and divided, and the whole tumour dissected out from the scrotum. When divided longitudinally after removal, a large cavity was opened in its centre, containing a quantity of brown fluid and much débris of blood-clot. The walls of this cavity were in most places about two inches thick, composed of dense, white, fibrous-looking tissue incorporated with the skin and subjacent tissues, and inside was much reticulated friable tissue of red-brown colour, from which a thin blood-stained fluid slowly drained away—clearly the remains of an old hæmorrhage. The testicle was not at once apparent, and the case appeared to be one of hæmatocele with great subsequent inflammatory thickening of its walls, matting them with the adjacent structures. On more careful dissection, however, the testis was found imbedded in the posterior wall of the cavity, with a perfectly healthy structure, although considerably flattened and compressed, and investing it were the tunica albuginea and tunica vaginalis, both quite healthy save that a portion of the parietal layer of the tunica vaginalis was involved in the thickened wall of the blood-containing cavity. Careful microscopic examination of this wall revealed only results of inflammatory changes, fibro-nuclear tissue, and in some parts tracts of spindle and other shaped cells developing into fibrous tissue. The solid and looser contents of the cavity were seen to consist of old blood-clot, with here and there attempts at organization.

The explanation of the case therefore seems to be that (as the result, probably, of some slight injury) an abscess formed in the cellular tissue of the scrotum, into which profuse hæmorrhage accidentally took place, or a large extravasation of blood in the same position was followed by inflammatory thickening of the tissues to an unusual degree.

The preparation is now in the museum of the Royal College of Surgeons. *February 7th*, 1871.

Digitized by Google

(c) FEMALE GENITAL ORGANS.

7. *Procidentia uteri with ovarian cyst.*

By CHRISTOPHER HEATH.

THE uterus exhibited was from a woman, æt. 39, who had suffered from complete procidentia uteri and prolapse of the bladder from the date of a confinement nineteen years before. The uterus habitually protruded from the vulva, was ulcerated extensively around the os, and the uterine sound passed for five and a half inches. Efforts at relieving the patient by mechanical means having proved useless, she was admitted into the Hospital for Women under Mr. Heath's care in October, and on the 13th the uterus was partially replaced, but came down again the next day. By leeching and poultices the size of the uterus was considerably reduced, and reduction became possible. The urine contained pus, but, as the bladder was prolapsed with the uterus, this was thought to be due to imperfect evacuation of that viscus and consequent chronic cystitis.

On October 29th Mr. Heath stitched up the vulva so as thoroughly to retain the uterus. The wound united completely, and the sutures were removed on November 3rd. Three days later diarrhœa came on, and the quantity of pus in the urine considerably increased. The patient gradually got weaker, and died on November 17th.

At the *post-mortem* examination the uterus was found to be three and a half inches in length, and the ulceration about the os was healed. The posterior lip was much thickened and indurated. There was a cyst of the right ovary larger than a cricket-ball, and rising half-way above the brim of the pelvis and to the right side, thus pushing the uterus quite over to the left. (This was, doubtless, one element in the difficulty of returning the prolapsus.) The left ovary was doubled round and attached to the posterior surface of the uterus by old adhesions.

The bladder was contracted to the size of a tennis-ball. The right kidney was enlarged, and the pelvis and upper three inches of the

Digitized by Google

ureter much thickened and distended, and contained a quantity of pus. There was no calculus, but the kidney had evidently been affected with chronic pyelitis, all the calices being much dilated. The substance of the kidney was pale, but the cortical portion of normal thickness. The left kidney was rather smaller than natural, and contained a little pus. *December 6th*, 1871.

Digitized by Google

VI. DISEASES, ETC., OF THE OSSEOUS SYSTEM.

1. *Ulceration of the transverse ligament, in consequence of caries of the vertebræ; dislocation of the head forwards; extravasation of blood beneath the arachnoid of the brain and spinal cord.*

By T. Whipham, M.B.

The parts exhibited to the Society were the four upper cervical vertebræ in a carious condition, with subsequent ulceration of the neighbouring soft parts, and also of the transverse ligament. The ligament had in consequence given way, and the head had become dislocated forwards. Secondly, a section of a portion of the brain, showing extensive extravasation of blood into the ventricles.

The history of the case is brief. The patient, Esther S—, æt. 40, was admitted into St. George's Hospital on August 24th, 1870, under the care of Dr. Fuller. For three months preceding her admission she had suffered severe pain in the neck and back of the head, together with much aching in her arms and shoulders. For this she was blistered on the nape, and a seton was inserted. Some slight relief in her symptoms followed the treatment, but she failed to derive from it any permanent benefit. For some weeks previous to her admission into the hospital her appetite had failed; she had lost flesh and had suffered from diarrhœa.

On admission she was unable to move her head without the aid of her hands, and suffered great pain in the neck and occiput, and also in the throat during the act of deglutition, but on examination of the fauces no lesion could be detected. The tissues at the back of the neck were infiltrated and brawny. Her speech was rather thick and indistinct. She obtained but little sleep at night, by reason of the pain. The bowels were regular. On August 27th it was noted that the cervical glands were rather enlarged, that pain on swallowing was increased, and that she experienced some difficulty in opening her mouth. On the 29th the pains in the occipital region

Digitized by Google

and neck were much worse, and she was unable to move her head. In the evening, while taking her tea, she had a rigor, and in ten minutes' time turned upon her side and died.

Necropsy 20¾ hours after death.

The body was anæmic, but well nourished. There were a few old pleural adhesions on both sides, and a little viscid mucus was found in the bronchi, but the pulmonary tissue was natural. The ventricles of the heart were semi-contracted; its muscular structure and valves were healthy. The liver was gorged with dark-coloured blood; the spleen was diffluent. The left kidney weighed 10½ oz. and was considerably congested; its surface was slightly uneven, and the capsule adherent. The calibre of the renal artery on this side was much greater than in the normal condition. The right kidney, on the other hand, weighed only 3½ oz. The cones, pelvis and ureter were greatly dilated, evidently owing to pressure caused by some obstruction below. After careful examination, however, no hindrance to the flow of the urine could be detected. The renal artery was much smaller than natural. The bladder was in all respects natural, and contained no calculi.

In front of the upper cervical vertebræ the soft tissues were hard and extremely thick, and on removing a portion of these thickened structures a collection of pus was found, lying anterior to the fourth cervical vertebra. The pus had burrowed among the soft parts, both in a lateral and upward direction. A sinus also was found in this position, which led down to a small piece of loose and necrosed bone lying between the third and fourth cervical vertebræ. Caries of the bodies of these bones existed, with ulceration and considerable erosion of the intervertebral discs; the disease of the bones, however, was only superficial. There was, moreover, extensive caries of the anterior arch of the atlas, of the articulating surfaces of the atlas and axis, and also of the root of the odontoid process. The transverse ligament was ulcerated, and had been ruptured close to its attachment on the right side, in consequence of which the head had become dislocated forwards, the odontoid process pressing on the spinal cord. Beneath the spinal arachnoid was an extensive extravasation of blood, which formed a perfect sheath (at the upper part of great thickness) for the spinal cord. The blood extended downwards almost as far as the cauda equina, and upwards over the base of the brain. The spot at which this sheath of blood was thickest corresponded exactly to the point at which the rupture of

Digitized by Google

the transverse ligament had taken place. The blood was of a dark colour, and had evidently been recently effused. The spinal marrow itself was firm, and to all appearance natural.

The convolutions on the surface of the cerebrum were somewhat flattened, and in the cavity of the arachnoid was a little clear fluid, while the lateral ventricles contained a large quantity. In each anterior cornu was discovered a dark-coloured blood-clot, which in shape precisely resembled a common leech when in its contracted state; the "head" of the leech pointed backwards. A large recent coagulum filled the fourth ventricle, and had extended forwards, through the iter a tertio ad quartum ventriculum into the third; both the iter and third ventricle were full of blood-clot. The central ganglia were uninjured, and no blood was found in the middle or posterior cornu of the lateral ventricles. At the base of the brain, beneath the arachnoid, was a large recent coagulum, which covered all the structures contained in the circle of Willis; it extended upwards on to the superior surface of the cerebellum, and was continuous with that occupying the cavity of the fourth ventricle. Laterally the blood followed the course of both middle cerebral arteries, each of these vessels being encased in a sheath of coagulated blood. At the point where each middle cerebral artery divides into its first set of branches, the edges of the clot were partially decolorised. Finally, on the left side of the pons and medulla oblongata was a small circumscribed patch of soft lymph.

Remarks.—The one great point of interest in this case is the fact of an extensive extravasation of blood having accompanied the rupture of the transverse ligament, such a complication being of extreme rarity. Unfortunately the origin of the effusion must necessarily remain a matter of comparative uncertainty, and for this reason—that no such lesion was anticipated, and it was only when the laminæ of the vertebræ and the cord itself had been divided that the blood-clot was discovered. So many vessels had in consequence been cut across that the task of discovering the exact source of the hæmorrhage was at once rendered hopeless. However, the fact that the blood-coagulum was more extensive and much thicker at the point where the odontoid process pressed upon the spinal cord affords room for conjecture that at the moment of the rupture of the ligament, and consequent dislocation of the head, some vessel of considerable size was torn across, and that from it blood flowed downwards beneath the spinal arachnoid, and also upwards to the

Digitized by Google

base of the brain and into its ventricles. It is stated in the notes of the case that while taking her tea the patient had a rigor; that in ten minutes' time she turned on her side and died quietly. This rigor was, then, in all probability the immediate cause of the fatal rupture of the transverse ligament, and of the concomitant hæmorrhage. Another point in the case is worthy of notice, viz. that the blood, after passing through and filling the third and fourth ventricles, had avoided, as it were, the middle and posterior cornu of each lateral ventricle. The position of the patient may explain this somewhat unusual occurrence.

The rigors, as has been stated, came on while the patient was taking her tea, and when she was (as the nurse affirmed) sitting up in bed. Supposing, then, that at the moment of the rupture of the ligament and extravasation of blood the woman's head to have fallen forwards on to her chest, a little of the blood, by this movement, would run forwards directly into the anterior cornu, and the shape of the coagula seems certainly to bear out the idea that the blood must have been suddenly tilted, as it were, into these anterior horns; but no large quantity overflowed in this manner, by reason of the patient's head resuming, or being caused to resume, its proper position almost immediately.

The cause of the caries of the vertebræ must remain doubtful, as there were no signs of tubercle in the body, nor was any history of syphilis obtained from the woman during her life. At the same time the occurrence of caries of bone in the upper cervical vertebræ inclines to the belief that, in all probability, a syphilitic taint existed.

The state of the kidneys seemed to show that, although no obstruction of the right ureter existed at the time of death, the bladder being also free from calculi, doubtless the ureter must at some time have been blocked by a concretion, which eventually passed into the bladder, and then accompanied the urine through the urethra. *November* 1*st*, 1870.

Digitized by Google

2. *Caries of the vertebra, with dislocation of the axis.*

By R. Douglas Powell, M.D., for Dr. Quain.

H. R—, æt. 18, of medium height and stout build, a labourer, came under the care of Dr. Roche, of Chelmsford, in May, 1869. He had then several enlarged glands in the neck, chiefly posterior to the sterno-mastoid muscle; in other respects he seemed in average health. His previous habits of life were very irregular, being an habitual drunkard, &c.

From the time of his admission to the 20th of July, 1869, he was constantly treated with cod-liver oil, iodide of potassium, &c., when the glandular swellings seemed to have entirely subsided. His diet was mixed and sufficient during the whole time he was under observation, and there was no history of an accident or of any labour likely to account for his subsequent disease.

He worked the "treadmill" for several months, and prisoners usually hold the head in a very stiff position while at this labour.

However, he had done no work of this kind for several months previous to his last and fatal illness. On the 1st of April, 1870, he complained of "biliousness" with headache, which was relieved by simple treatment, and his diet was then improved, as he appeared pale and languid.

On May 7th, 1870, there was a slight febricula, which continued for three or four days, during which time he complained of severe pain all over the occipital region and darting towards the front, and he held his head in an immovable position, rather inclined to the left side, on which the muscles appeared rigid. His face assumed a peculiarly anxious look, which continued until his death.

On the 18th of May, 1870, there was an eruption of boils on the sides of the neck. The pain was constant in the back of head to his death, and there seemed a constant and great fear of moving the head in the slightest manner. With the exception of the febricula of May 7th and following few days, there was no constitutional disturbance during his illness; his pulse was invariably 66 to 72; his

Digitized by Google

tongue clean, his secretions healthy, bowels regular, and urine contained nothing abnormal except phosphates. His appetite was good and his general strength unimpaired.

On the 20th of June he died suddenly as he was making an effort to raise himself in bed. His pulse was 66 and steady during several gasping efforts to breathe.

During the febricula in May his case was diagnosed as "caries vertebræ, and probably, of the atlas or axis," and for this he was treated during the remainder of his life. His head was kept immovable by an apparatus (leather splint) which fitted closely to the occiput, neck, and shoulders. Cod-liver oil, iodide of potassium, and steel, with a generous diet, were given.

On viewing the back of the neck after death, there was a distinct prominence of the axis (posterior spine) and a sulcus above. The body was well nourished, and there were no other unusual appearances.

On dissecting down it was found that there was considerable congestion around the parts to be afterwards referred to, and the odontoid process of the axis pressed heavily on the spinal cord, which was almost flattened from the pressure. There was scarcely any pus, except between the atlas and the articulating surface of the occipital bone.

The atlas, axis, and three following cervical vertebræ were removed and examined by Dr. Powell, who has drawn up the following report:—

"The specimen consists of the atlas and axis, with three other cervical vertebræ attached. The disease involves the right upper articulating surface (occipito-atloid) of the atlas, the corresponding side of the odontoid process of the axis, and the anterior (external) surface of the prolongation of the dura mater forming the sheath of the cord.

"The articular surface of the atlas has been entirely denuded of its cartilage, leaving a rough carious surface at parts soft and pulpy. The capsular ligament of the joint (occipito-atloid) has been partially destroyed at its insertion into the anterior, internal, and posterior margins of the articular surface. The bone is eroded by carious disease immediately around the tubercle for the insertion of the transverse ligament of the odontoid process, but the insertion of the ligament itself is intact. On the right side of the head of the odontoid process, immediately below the attachment of the cheek

Digitized by Google

ligament there is a small carious surface, which extends round posteriorly as far as the centre of the articular surface for the transverse ligament, destroying in part the cartilaginous surface there. The root of the odontoid process is also bared at its posterior aspect, with the exception of a few ligamentous shreds, and opposite to it the spinal dura mater is hollowed into a pouch, which projects backwards, encroaching upon the arachnoid space of the spinal canal, with which it communicates by an irregularly triangular opening. There are no signs of spinal meningitis, the parietal arachnoid is at this part of a tawny-yellow colour. The visceral arachnoid is perfectly healthy, but is adherent at one spot to the margin of the opening in the dura mater above named.

The above particulars point to the fact of there having been an abscess on the right side of the vertebral canal, involving and destroying the right occipito-atloid articulation, partially destroying the articular surface for the transverse ligament of the odontoid process, denuding the base of that process at its posterior aspect, and pointing posteriorly through a pouch-like projection of the sheath of dura mater into the arachnoid space of the spinal canal.

There are no signs of inflammation about the cord, which looks, however, as if it had been compressed at this point, though one could not affirm this in its present state. All the ligamentous structures in the half of the ring of the atlas involved in the abscess, including the transverse ligament, have been more or less completely softened and destroyed. *March 7th*, 1871.

---

3. *Fibroma springing from inferior costa of scapula and aponeurosis of subscapular muscle.*

By John D. Hill.

This specimen, exhibited at the last (November 15th) meeting of the Society a few hours after removal by operation, consists of the lower two fifths of the infra-spinous portion of the left scapula,

Digitized by Google

with a large tumour attached to its inferior costa and to the aponeurosis of the subscapular muscle.

The chief points of interest comprise its rapid growth, unusual situation, and anatomical connections; and although these are perhaps as much clinical as pathological questions, they, at any rate, serve to show the probable influence of position and pressure on the shape and size which morbid growths sometimes assume.

The patient, Harriett B—, æt. 33 (widow, with two healthy children), was admitted into the Royal Free Hospital under my care on the 10th of last month (November). She had always enjoyed good health until nine months ago, when she first felt a pricking pain in the shoulder, soon afterwards attacking the infra-clavicular, mammary, axillary, and infra-scapular regions.

About a month later she noticed a lump as large as a walnut at the back part of the axilla, which, during a further period of six weeks, had attained the size of an egg; pain, at first erratic, now became constant, of a very stabbing character, and increased with the growth of the tumour, and the movements of the upper arm became impeded, particularly in regard to elevation, adduction, and rotation inwards.

During the four or five ensuing weeks the swelling apparently remained stationary, but after this she became sensible of its gradual increase; she then applied embrocations and lotions with more or less relief during the ten weeks following, and although the tumour had sensibly increased, she thought there was not more difficulty in moving the arm. Soon afterwards, first pricking and then numbness of the hand and arm, and occasional puffiness of the extremity, caused her discomfort; and, finally, losing all use of the limb, she sought advice at the Royal Free Hospital.

On examination.—The arm was semiflexed, partially abducted, and advanced in front of its fellow.

Viewing the patient from the left side, a smooth, oval, dense, inelastic tumour about five inches in its greatest diameter, and four inches in thickness, occupied rather more than the posterior half of the axillary space, with the axillary artery pulsating over its upper surface; extending towards the axillary apex it seemed fixed to the chest, and was apparently immovable. Posteriorly it was firmly attached to the scapula, and, on rotating the latter, the lower part of the tumour was felt to move slightly; inferiorly, it extended just below the eighth rib.

Digitized by Google

The integument freely glided over the tumour, and at each respiration it was seen to rise and fall with the chest. After three days' absolute recumbency its size had somewhat diminished, and it was found slightly movable upon the chest from above downwards, and with the scapula more movable from side to side; there was also a partial return of power in the arm.

On the fourth day the operation was performed, an incision was carried from the axillary apex to the inferior angle of the scapula, and from the latter along the posterior costa to the insertion of the rhomboideus minor muscle. The dense areolar connections with the chest and axillary vessels and nerves were next severed, the muscular attachments divided, and the operation was completed by sawing the scapula across immediately above the tumour.

Examination of tumour.—This consists of two portions which are partly bisected by the scapula; the larger portion, which projected in the axilla, is somewhat kidney-shaped, but smaller above than below, and firmly attached to the periosteum of the inferior costa of the scapula for two inches in extent; it receives some fibres from the subscapular muscle which are adherent to its posterior surface. The smaller portion is flattened out and attached to the aponeurosis of the subscapularis nearly as far back as the posterior costa; the longest diameter measures five inches, and its entire thickness about three inches. On section it conveys a sense of firmness and resistance to the scalpel, and even with a sharp one cuts very tough. To the naked eye it appears composed of two textures (1, a white, glistening fibrous substance; 2, a firm sarcomatous texture, faintly straw coloured).

There is a very thick fibrous capsule from which white fibrous bands extend in every direction, apparently forming a firm strong network; this appears to enclose the sarcomatous texture, to which it seems firmly interwoven by dense areolar tissue. Some of the fibres appear to take a wavy course, others more or less straight, and a third an arborescent direction. On a section of the subscapular portion the texture is more compact than the axillary, and to the naked eye appears to consist chiefly of fibrous tissue. Under the microscope I observed a uniform filamentous stroma containing slender fusiform nuclei, which are placed in regular order in curved tracts, these cross one another at various angles, and appear to be developing into fibrous tissue.

My friend Mr. Arnott, who has kindly examined a portion micro-

Digitized by Google

scopically, bears me out in this description; he says: "On staining some thin sections of the tumour with carmine and placing them in glycerine, I find that the structure is everywhere (in the bit I examined) that of a fibroma, *i. e.* there is an abundant homogeneous or fibrillated stroma, imbedded in which are slender, oat-shaped nuclei, arranged in a regular order of waving tracts, which cross one another in various directions. In some parts the nuclei are plumper and more closely set—suggesting the idea of a spindle-cell sarcoma—but everywhere the structure is clearly rapidly developing into fibrous tissue, with no appearance of fatty or other degeneration."

November 15*th*, 1870.

---

4. *Congenital dislocation of wrist.*

By James E. Adams.

This specimen having been taken from the body of a woman in the dissecting room of the London Hospital Medical College, is without any history. All the tendons had their usual insertions, and their relations were but slightly disturbed; they lay in healthy sheaths, and neither they nor the ligaments present any evidence of disease. The dorsal aspect of the bones being exposed, it may be seen that the proximal end of the metacarpal bone of the first finger, normal in size and shape, articulates with the lower end of the radius, towards its inner side. The end of the metacarpal bone of the second finger is opposite to the interval between the radius and ulna, but is separated from them by a small piece of bone, with which it articulates: I believe this to be the remains of the os magnum.

The fifth metacarpal bone articulates with the unciform, which is closely attached to the inner side of the ulna. On the radial side of the unciform a process of bone reaches from the ulna to the base of the fourth metacarpal bone. This I take to be the styloid process of the ulna. On the palmar surface the unciform process and the pisiform bone project; they are of normal size and shape, but so placed that a line passing through their centres has a direction parallel to the axis of the ulna.

Digitized by Google

The metacarpal bone of the thumb articulates with the remains of the trapezium. A horizontal section through the projecting carpal bones shows them to be anchylosed together as far as can be seen, *i. e.*, scaphoid, semilunar, and cuniform. The inferior radio-ulnar joint is partially anchylosed, but the compact tissue of each bone is perfect. The remains of the carpal bones form a considerable projection in front. The axis of the little finger and the axis of the ulna are inclined to one another at an angle of about 130°.

November 15th, 1870.

---

5. *Destructive and reparative processes in two hip-joints.*

By Richard Davy.

A man had suffered from morbus coxæ (right) for four years. After death a large abscess surrounded the hip-joint, and an aperture of the size of a penny piece existed in the acetabulum, allowing the eroded and of the femur to rotate freely in the pelvic cavity.

A woman, fifty years before her death, broke the neck of her left thigh bone. On cutting it out after death, complete and very perfect union had occurred; the joint was obliterated by bony anchylosis, and a large amount of osseous exaggeration existed in the immediate neighbourhood of the hip-joint. *November 15th*, 1870.

---

6. *Necrosis of the patella.*

By C. Kelly, M.D.

R. Laura A—, æt. 7 years, was admitted under Mr. Wood's care in King's College Hospital, on August 3rd, 1870. She stated that a fortnight previously she ran a dirty fork into her left

Digitized by Google

forefinger. In a few days she had some shivering, and the left knee began to swell and be very painful; the temperature was high and oscillated two or three degrees during the day. At this time she had distinct pyæmic symptoms.

On August 6th the knee-joint was opened and a little pus escaped; an abscess also formed in the finger, which was opened and discharged freely.

Early in September, the knee being more swollen and painful, it was again opened and a good deal of pus escaped.

On Sept. 19th, while dressing the wound, the house-surgeon found the patella lying loose near the surface and removed it with a pair of forceps. The bone was quite dead, of a yellowish colour, and had a worm-eaten appearance on its lower border and posterior surface; when dried it weighed 1·485 grammes.

By this time the wound in the finger had healed, and the girl was improving in her general health. She recovered from this time, and early in November she left the ward quite convalescent. No new bone had apparently formed up to the date of her discharge. Both wounds were treated by Mr. Wood after his carbolic acid method.

November 15th, 1870.

---

7. *Gunshot injuries of bone.*

By W. MacCormack (introduced by Dr. Quain).

At the suggestion of the President I venture to present for the inspection of the members of the Pathological Society a few examples of gunshot injuries of bones. They have been taken without any particular selection out of some sixty others of a similar description. All of them exhibit the results of gunshot injuries received during the recent battle of Sedan, where I happened to be present under circumstances unusually favorable for pursuing the practice of military surgery. I much regret that pressure of work prevented me from cataloguing and describing the specimens I was able to preserve as I should have wished, and that many examples

Digitized by Google

of unusual injury were altogether lost. There was little or no opportunity, indeed, to occupy oneself with any but the most urgent and pressing work, and for that even the time at our disposal was often quite insufficient.

These examples of gunshot fracture, however, need but little description from me, they speak for themselves, and serve very well to illustrate in what respects gunshot injuries differ from the fractures of bone usually met with in civil practice.

The following is a descriptive list of gunshot injuries of bone selected from a very large number, and showing the features peculiar to gunshot fractures as distinguished from ordinary fractures.

No. 1. Femur removed by secondary amputation. A Bavarian bullet, much altered in shape, is impacted in the lower third of the external aspect of the right femur. The external condyle is split off, and the bone otherwise a good deal split and comminuted.

No. 2. Extensively comminuted fracture of the middle of the right femur. The upper end of the lower portion of the shaft is bifurcated, and in the fork rests, projecting outwards, the upper portion of the shaft. The comminuted fragments of bone were driven considerable distances into the soft parts round the seat of fracture. This patient was admitted under my care when too late to perform any operation, and he soon sank exhausted. Some callus has been thrown out, while the femur has been removed with portions of muscle attached to retain the fragments *in situ*.

No. 3. The upper third of femur, just below the trochanters, and lower third of tibia are smashed by Chassepôt bullets. The splintering effect of the bullet is very apparent in the tibia. In these cases amputation at the hip-joint was performed, but without success.

No. 4. Prussian bullet lodged between the condyles of the femur after perforating the patella.

Amputation in the middle of the thigh.

No. 5. Pulverisation by a Prussian bullet of the internal condyle of left femur. Secondary amputation.

No. 6. Smashing and pulverising of the upper end of left os tibia by a Prussian ball.

Amputation was performed at Balan.

Digitized by Google

No. 7. Destruction of the lower extremity of the tibia and fracture of the fibula. Great comminution and pulverising by a Prussian bullet.

Amputation also at Balan.

No. 8. Upper and middle third of the right tibia extensively split into large fragments, probably *par éclat d'obus* striking the bone in front. The fibula is intact, and with that exception the injury is similar to the fractures of the leg met with frequently in civil practice from direct violence.

No. 9. *Broiement* (the most suitable word to express the condition) of the os calcis. This specimen shows the effect caused by a Prussian projectile passing through the bone.

No. 10. Parts removed by amputation (secondary) of leg, on account of a Prussian bullet lodging in the right astragalus. The bullet entered posterior and internal to the ankle-joint. Its whereabouts was not discovered, nor was the amount of damage done recognised. An attempt to save the limb failed. Amputation became necessary on account of the large amount of suppuration and diffuse inflammation. It was performed at Balan.

On examination subsequently, the astragalus was found to be completely comminuted. The upper surface of the calcis is grooved slightly by the ball, which is seen resting upon the upper surface of that bone.

Could an exact diagnosis have been arrived at in this patient it would have proved a typical case for resection of the astragalus, which has been in civil practice a satisfactory and successful operation.

No. 11. Left humerus completely severed by a ball passing through it at a high velocity. There is no splitting, and a portion of the bone has been carried away.

No. 12. This is a specimen to which a special examination should be devoted.

The patient from whom it was taken was wounded on the 1st Sept., and died from exhaustion on Sept. 28th. There were no symptoms present of spinal injury, and he died, we believed, from a penetrating chest-wound. He had had profuse hæmoptysis for three days. He only came under our care on Nov. 9th, when it was

Digitized by Google

impossible to make any complete examination of the nature of the wound. The ball had entered the anterior edge of the left trapezius muscle, just about its middle. The point of exit was through the posterior fold of the right axilla.

The *post-mortem* examination revealed extensive pleuritis of the right side, condensation of the right lung, and large purulent effusion in the right pleural cavity. The spine and lamina of the seventh cervical vertebra have been carried away by the ball, as also the spine of the first dorsal vertebra. The spinal canal was laid open, and a piece of cloth was found lying in it.

The second and third ribs are fractured, and splinters from them were found imbedded in the pleura.

No. 13. These are the fragments of bone removed from the right shoulder and the right elbow-joints of a Chasseur de Vincennes, who had also received a bayonet thrust in the cheek.

This man refused absolutely to part with his arm, which, indeed, we had no desire he should part company with; and lest we should take any unfair advantage of him, declined to take chloroform while the excision of the shoulder-joint was being performed. We forced him, however, to have some while the elbow-joint was being removed.

In spite of great fever, of threatened pyæmia, resulting in abscesses, this man's almost superhuman courage has, I trust, triumphed.

The operation was performed on the 14th September, two days after his admission to the hospital. He was wounded on September 1st like the others.

I have a report about him up to the 21st November, which I only yesterday received from the Dutch surgeon in whose charge I left him.

This gentleman writes under date December 1st:—"The wound of the shoulder is healing up quite well, but at the elbow large abscesses formed which undermined his constitution considerably. However, during the last few days he was again improving." I have taken every means within my reach to secure an account of the ultimate result of this, I believe, unique case. At some future time I hope to make it public.

I think a cursory inspection of these fractures will point at once to the conclusion that they are more severe, more extensive, and present a larger amount of comminution and splitting than the

Digitized by Google

fractures we usually meet with. Besides, they are invariably compound fractures, and the wound of the soft parts is a contused wound and incapable of uniting under most circumstances by the first intention, a condition which must modify the treatment, and render, *cæteris paribus*, the prognosis less favorable. I think that in some of the specimens the marked difference in kind between the bone wound caused by the Prussian ball and by the Chassepôt is very apparent. The former projectile, the heavier of the two, and ovoid in shape, crushes, and, as it were, roughly pulverises where it strikes a bone, and the splitting is not extensive. The Chassepôt bullet, much lighter, and of a conical shape, but having a higher initial velocity, comminutes extensively and splits the bone often to very long distances. The Bavarian bullet is different in shape, but it, too, is conoidal, and acts somewhat similarly to the Chassepôt. Much, however, depends upon the length of range at which fire has been delivered.

Nothing is more deceptive than the external appearances of gunshot injuries as compared with the amount of deep-seated damage, especially if the bone be struck.

I am convinced that nothing short of a thorough examination by the finger, just after the receipt of injury, can ever be wholly satisfactory in the case of gunshot wounds, and it would, I submit, be well to lay this down as an invariable rule of practice, whenever it is at all practicable. In no other way can a true and adequate knowledge be acquired of the extent of bone damage. Of course these remarks are intended to apply to wounds of the limbs, and not to penetrating wounds of the head, chest, or abdomen. In such cases, the less meddling that is indulged in the better for the patient.

There can be little doubt that in such a case as is illustrated by Specimen No. 2, a thorough examination would have determined amputation in the first instance, and the man's life might have been saved.

I may sum up my conclusions by saying that while in hospital practice at home, we very properly lean strongly towards what is termed "conservative surgery." Such opinions must be materially modified if we would practise military surgery with advantage. I am firmly convinced that in military service we must depend more upon what we may term *radical surgery;* and that by adopting radical measures many more lives will be saved, and the saving of life is the end which every true surgeon, uninfluenced by any secondary considerations, will steadily keep in view. *December 6th*, 1870.

Digitized by Google

8. *Large and multiple exostoses of the skull with hyperostosis.*

By James E. Adams.

This skull, sent to me by Mr Champneys, was removed from the body of a man named Reilly, who died at the age of forty-nine, in the summer of 1858. There were no symptoms of interference with the functions of his brain; his death was sudden, and supposed to be from heart disease. The disease was first noticed fourteen years before death, and he himself attributed it to his having been injured in an explosion of fire-damp, after which he said he was insensible for a long time and had a protracted illness. The date of this injury is uncertain.

His appearance during the latter years of his life is described as being *hideous;* the soft parts of his nose being destroyed, his right eye protruded from the orbit, his jaw was extremely distorted, and the vertical diameter of his head appeared enormous before the soft parts were removed from the upper growth. He used to beg in the summer time, and take up his winter quarters in the workhouse. There is no satisfactory evidence of his having had syphilis. All the growths appear to me to be, or at least to *have* been, confined to the right side; that portion of the tumour connected with the ethmoid, and encroaching into the nose, can be clearly made out to have the remains of the septum on its left; without sections it is not possible to ascertain the exact relations of the superior part.

The other growths appear to be *entirely* limited to the right side and are seen in the following situations: two small outgrowths on the anterior surface of the lower jaw to right of the median line. The right genial tubercles all fused into one piece. The whole body of the jaw on the same side is enlarged, and nine of its alveoli are closed, and there are two outgrowths upon them, a small one in front and a larger behind.

The coronoid process is so large as to reach to the junction of the malar and superior maxillary bones, and the inner boundary of the inferior dental foramen is also much increased in size.

The condyle is about three times as large as its fellow and roughly tuberculated.

Digitized by Google

The following are the remaining points where these growths can be seen; *all* on the right side:—Anterior portion of palate, hamular process, external pterygoid process, malar bone at its frontal maxillary, and temporal portions all around the glenoid cavity and external auditory meatus; over the squamo-parietal and masto-parietal sutures.

The right posterior clinoid process is much larger than the left; and just in front of the foramen magnum, on the under surface of the basilar process, there is another small growth, to the right of the middle line; this, I believe, is the insertion of the right rectus anticus minor. *December 20th*, 1870.

---

9. *Fracture of head of radius.*

By James E. Adams.

This specimen was taken from the body of a man who died about forty-eight hours after a fall from a great height, in which he received the following injuries:—A simple fracture of right femur, compound comminuted fracture of left femur, lacerated scalp, and fracture of right radius.

On examining the elbow, which was but slightly depressed during life, distinct crepitus could be felt over the upper end of the radius, leading to the conclusion that the bone was fractured; but when it was observed that the upper piece of the bone rotated freely in conjunction with the shaft some doubt as to the nature of the injury arose.

The capsular ligament was torn slightly posteriorly, and a portion of bone lay in the opening; it was necessary to cut away the capsule to show the entire extent of the fracture, which is as follows:—The outer third of the head is split away from the inner portion in a vertical direction, and this outer piece is again split in a vertical direction into two pieces, of which the anterior is much the smaller. The lines of fracture appear to be abruptly terminated by the orbicular ligament. The cartilage on the radial surface of humerus

Digitized by Google

is abraded, and leads one to suppose that the head of the radius had been driven against it and so split. *February 7th*, 1871.

---

10. *Osteo-colloid cancer of the skeleton.*

By W. Moxon, M.D.

The subject from which the specimens were removed had died in Guy's Hospital, apparently from hæmorrhage caused by the removal of warts from the prepuce.

He was found to have severe cystitis, and slight suppuration of the kidneys.

The widely diffused cancerous disease created surprise as there were no symptoms observed during life such as to suggest anything of the kind.

To the house surgeon's questioning, he had denied headache; but it was stated that subsequently in the last two days of his life he complained of splitting headache, and also said that one leg was numb. He was in the hospital from January 7th to January 19th, under the care of Mr. Howse.

The body was of a small well-built man, æt. 23, with straight regular features, full head of light hair, gray iris, and small beard.

The *calvaria* was excessively diseased, numerous patches of growth occuping both its surfaces, some reaching the size of half chestnuts, and others varying down to the size of hemp-seed, the smaller ones mostly on the outer surface. The larger projected both without and within the skull; yet though the bulk of the cancer in the larger patches was soft and gummy or glutinous it could not be pierced with a knife, dense bone occupying the centre of the doubly projecting growths. These largest patches had opaque centres, but the smaller patches were almost pellucid, soft, and of pale grayish colour. Around the larger patches the bone grew in specules of osteophyte for a distance extending three quarters of an inch around them. On removing the calvaria some of the patches were attached to the dura mater, but there were no signs of disease in the substance of

Digitized by Google

or on the inner surface of this, or on the proper membranes, except that the pressure of the growths had flattened the convolutions.

The brain was very anæmic, but healthy. There were many patches of cancer down the spine, in the bones, as low as the sacrum. The glands in front of the spine were more or less enlarged, especially the retro-peritoneal glands. These compressed and entered the vena cava, or at least implicated the wall of the vein, so as to change it to cancer.

Seven of the right and four of the left ribs were cancerous. The cancer swelled the bone at the affected point of the eighth left rib to the size of a large plum, the surrounding tissue being invaded so that the periosteum was visible as a circular line in the section, while much colloid matter grew outside it in the muscles, &c. The cancer here was of gummy and semi-glutinous character, clear, and

WOODCUT 8.

Fine section of one of the growths in the cranium seen with ⅜-inch power.

pellucid; no part of it resembled cartilage. The lungs were healthy; one bronchial gland swollen and cancerous, and its neighbours affected to less extent. The cancer here also was strikingly colloid.

In the bones of the limbs there was no cancer discoverable, at least by fragility, which was tested.

When sections of the growths in the cranium ribs bronchial gland

Digitized by Google

were examined microscopically they were found to present characters of colloid cancer (see figs. 8 and 9).

To the naked eye these characters were already distinct enough, as the glutinous substance showed an alveolar structure, the outlines of the alveoli formed by whitish fibres and lamellæ. Sections in water swelled up and became opalescent. This swelling was of the glutinous contents of the alveoli. The boundaries not partaking, so that the swollen contents rose as little masses from the several alveoli; in glycerine they returned to their former bulk. Weak acetic acid had little effect on the structure.

WOODCUT 9.



Part of fig. 8 seen with ⅛-inch power.

Ink which I use for staining coloured the alveolar walls deeply but left the gelatinous matter untinted.

Digitized by Google

In this country colloid cancer is regarded as a distinct and well characterised type of disease. The alveolar framework with glutinous contents, in short, all the features which make up the descriptive definition of colloid cancer are present in the case I show, but I cannot find that in England colloid of the skeleton has hitherto been observed. In the present case it occurs in the shape of extensively diffused patches, implicating largely bones of the head and trunk; such general diffusion of cancer through the bones is generally secondary, though certainly not invariably so. No other cancer was discoverable in this man's body, save in the lymphatic glands, whose implication was obviously secondary.

In Germany the views of colloid cancer are now difficult to understand, the question being confused by the as yet uncompleted descriptions of Virchow's great book on 'Tumours,' but whatever may be the real comparative nature of colloid growth the tumours before us are strictly colloid according to the recognised descriptions of that disease.

Virchow describes myxoma of bone; but the typical structure of Virchow's mucous tissue is a good deal remote from that of alveolar cancer, with its keenly defined walls and almost structureless contents, which differ much from the nexus of stellate cells composing mucous tissue.

Virchow, however, describes enchondromas as varying in their characters towards those of myxomas; and if with this thought we were to suppose cartilage tissue to take on the consistence of mucous tissue as to its intercellular matter while its cells degenerated into fatty relics, such a mucoid change of cartilage would give us almost exactly the material of colloid, while the well-known multilocular appearance of enchondroma corresponds closely with the minuter subdivision of alveolar cancer, and the ossification of some of the growths further would sustain such a view. Thus, we might reach easily on this supposition a view of muco-cartilage as composing colloid, but on the other hand as against such a view there arises the reflection that in passing to myxoma Virchow's soft and tremulous enchondromates acquire stellate-formed cells. The cells, indeed, become more instead of less developed and connected, whereas in our colloid the cells are entirely separate, or rather mere isolated patches of granules for the most part represent them. Again, the absence of true cartilage from colloid cancers is a point in contrariety to a view which would closely connect these substances, while in the third

Digitized by Google

place the usual seats of colloid cancer, viz. the ovaries peritoneum, intestinal canal, and mammary gland, are not subject to enchondroma, nor are they likely to generate cartilage.

On the whole it appears to me that colloid cancer is a sufficiently distinct kind; it not infrequently occurs in large extent, infecting a variety of tissues, and its gradations into other forms of growth are not more important than gradations between fibrous and sarcomatous, or mucous and lypomatous, or enchondromatous tumours. As to the malignancy of colloid, the word malignancy signifying infectiousness, numerous examples before the present remarkable case sufficiently establish this character. *February* 21*st*, 1871.

Report by the Committee on Morbid Growths upon Dr. Moxon's case of osteo-colloid tumours.—Sections of the growths situated in the bones and in the bronchial glands were examined under the microscope, and the histological characters were alike in all. The growth presented the ordinary features of colloid disease consisting of large alveoli filled with gelatinous matter. Some of the alveoli contained numerous rounded nuclei. In the lymphatic gland tissue the diseased portions were not separated by any well-defined line of demarcation, the new growth appearing to invade and gradually merge with the gland tissue. In none of the sections examined were any traces of cartilage cells observed. We agree, therefore, with Dr. Moxon in regarding the structure of the growths invading the bones and lymphatic glands as indistinguishable under the microscope from that of tumours which have in this country been described as colloid cancer, and regard the present case as one of colloid rather than of enchondromatous or myxomatous disease.

J. S. Bristowe.

August 5*th*, 1871. W. S. Church.

---

11. *Myeloid tumour of the head of the tibia.*

By Marcus Beck.

David Simpson, æt. 31, a sailor. Eighteen months ago the patient received an injury to the head of the left tibia from a fall. He

Digitized by Google

felt no inconvenience from this at the time, but three months after a lump formed below the knee. It was painful, especially at night. It was painted with iodine for some time without benefit. He then left his ship in Bombay, but after this shipped again for another voyage, and returned to England about seven months ago. For the last month of the voyage he was helpless, being unable to stand on the leg. After landing he spent seven weeks in the Ipswich Hospital where a grooved needle was passed into the swelling, with what result he could not say. From the time he left Ipswich Hospital, till he was admitted under Mr. Marshall into the University College Hospital, he had led an irregular life, in great poverty, and often in want of food. He seemed to have reformed shortly before admission, for he was married on March 4th, and admitted on the 6th. For the last month or two before admission he had suffered considerable pain in the tumour, especially at night, and had lost flesh slightly, but this he attributed to his bad living.

On admission the patient was thin, but by no means cachetic in appearance. On examination of the left leg, a large roundish tumour was seen immediately below the knee. It was slightly lobulated, especially on the anterior surface. There were a few enlarged veins running over the tumour, but they were not tortuous or markedly distended. The muscles of the leg and calf were extremely wasted. The tumour measured seventeen inches in circumference at its most prominent part. On manipulation, the tumour was found to be soft and elastic at its anterior part, where there was indistinct fluctuation. At each side it was covered by a thin layer of bone, which gave the characteristic crackling on pressure. The head of the fibula could be felt at the outer side of the growth, evidently not implicated by the tumour. The tumour was not tender when handled, but the pain afterwards was rather increased. There was marked unnatural mobility of the upper part of the leg, showing that the whole of the upper end of the bone was destroyed by the tumour. There were no enlarged glands in the groin.

On March 14th Mr. Marshall amputated in the lower third of the thigh, and the patient made a remarkably rapid recovery. On making a section through the mass, the head of the tibia was found to be entirely destroyed, the tumour reaching from immediately beneath the articular cartilages of the tibia, to about three inches down the bone. Between these two points there was no bony tissue, except a small quantity deposited beneath the periosteum, which was

Digitized by Google

expanded over the tumour, and somewhat thickened. The articular cartilages were to all appearance healthy, and the joint was perfectly free from any disease. At the lower part the growth extended an inch into the medullary cavity of the remaining part of the tibia. The bone here was being absorbed from the pressure of the tumour giving the upper opening of the medullary canal a funnel-shaped appearance. The tumour contained numerous cysts, varying in size from a filbert to a large walnut, and filled with a blood-coloured serous fluid. The walls of the cysts were thin and pellucid. The superficial parts of the tumour were of a delicate pink colour, soft and brittle, and on scraping yielded no juice, but only fragments of the growth. The central part was soft and almost pulpy, and of a dirty yellowish-brown colour.

On examining a scraping under the microscope, the most marked elements were large myeloid cells, which from the pressure of the covering glass assumed all sorts of irregular shapes. They contained from eight to twenty nuclei each. The nuclei each contained a single bright nucleolus. Besides these there were many spindle cells scattered about the field, and also a large number of oval cells, with clear bright nuclei, with a single, or occasionally a double nucleolus. There were also a few free nuclei.

On making sections of specimens hardened in absolute alcohol, the tumour was found to be a most perfect specimen of myeloid sarcoma. In many parts the myeloid cells formed the greater part of the structure of the growth. The intervening substance was made up of spindle cells well defined in some parts, but in others the cells were round or oval. The nuclei were very faintly granular, or clear with one, and sometimes two, bright nucleoli. But few vessels were seen in the sections, and such as were found had distinct lining membranes. *March 21st*, 1871.

---

12. *Medullary sarcoma of fibula.*

By H. Morris, M.B.

G. W—, æt. 14, was admitted under Mr. de Morgan into the Middlesex Hospital, on January 12th, 1871. It was then stated that three months ago he began to suffer pain in the sole of

Digitized by Google

his left foot, especially beneath the arch of the foot, which soon extended along the calf of his leg. Two weeks later a swelling was noticed in the calf of the left leg, which has since been regularly and rapidly increasing. On admission he was pale and delicate-looking, and complained of pain in the leg and foot. A large elongated oval-shaped tumour occupied the posterior and outer aspects of the leg; it was most prominent in the centre of the calf, where it measured fifteen and a half inches, and it tapered off above and below, so as gradually to fade into the limb one inch below the knee, and about two inches above the ankle-joint. In front the outline of the tibia was throughout distinct, but the fibula in greater part of its length was surrounded by the growth, and could be traced into it from the extremities, the bone expanding as it neared the tumour.

To the touch the tumour was elastic and yielding, except above on the outer side at the spot where the fibula was lost in it. The measurements over the head of the fibula and the malleoli were ten inches, and seven and three quarter inches respectively, as compared with nine inches and six inches on the right limb. The skin of the leg was of a salmon-pink colour, and numerous distended veins traversed it. The glands in the groin were hard and slightly enlarged.

Amputation above the knee was performed, and the boy left the hospital on March 14th, 1871, quite well, but with the glands in the left groin still in the same state as on admission.

He has since been heard of, when he was in good health. There was no alteration in the glands.

On section the tumour presented a white, soft, and brain-like appearance, and yielded an abundant creamy fluid. It closely surrounded the shaft of the fibula, and was growing from the periosteum, but not between the periosteum and bone; the latter was firm and compact in structure, and not of the soft spleen-like appearance so often observed in the bones of cancer cases; the periosteum, though thickened, was to a great extent distinct and separable from the bone, and when separated its attached surface presented a coarse, villous, or bristle-like character. The greater portion of the soft tissues of the leg were invaded and destroyed by the growth, but the disease did not reach either above or below, beyond the cartilage between the apophysis and epiphysis of the fibula.

On microscopic examination the tumour was seen to be very vascular, and to be made up of uniform rounded cells of the size of lymph- or pus-corpuscles with granular contents. A few of the cells

Digitized by Google

only gave the appearance of possessing each a distinct nucleus, with a fine cell wall closely enclosing and almost touching it.

In a thin section some very fine fibrillæ were seen to spread out amongst the cells, and to form a fine gauze-like stroma, in the interstices of which the cells lay.

The marked resemblance in the naked-eye appearances of this tumour to medullary cancer is the chief feature of interest in the case. *April* 18*th*, 1871.

Report of the Committee on morbid growths on Mr. Morris's case of sarcoma of the fibula.—The tumour is a round-celled sarcoma of the fibula. It presents the usual characters of such growths, consisting of spheroidal corpuscles, not much larger than blood discs, which are held together by a very scanty stroma. The whole of the periosteum covering the shaft of the fibula is involved in the growth, which, without doubt, originated from this structure. The bone is softened at the surface, but elsewhere retains its natural firmness.

J. B. Sanderson.

May 9*th*, 1871. T. Henry Green.

---

13. *Malignant osteoid tumour of fibula.*

By Henry Arnott.

This tumour was brought before the notice of the Society as an instance of the rare disease commonly spoken of as "osteoid cancer," and with the object of provoking some discussion upon the minute structure of this form of growth. Now that we are beginning to limit the term "cancer" to a specific anatomical structure, distinct from sarcoma, it seems proper that such a name as "osteoid cancer" should be limited to growths having the minute structure of cancer, anatomically defined, but having also sufficient resemblance to true bone to justify the qualifying adjective "osteoid." Hitherto the growths so described have been nearly always examples of what we should now call "ossifying sarcoma," or some form of

Digitized by Google

sarcoma in which, without any true ossification, an abundant deposition of bone salts has given a bone-like character to the tumour. The present specimen belongs to the latter class and it has, therefore, been called malignant osteoid tumour.

George W. Hyde, a carver and gilder, single, æt. 22, was admitted into the Middlesex Hospital, under the late Mr. Moore's care, on August 10th, 1869.

In the previous October, ten months before, he first noticed, after walking, a dull pain "like rheumatism," in the right leg. Towards Christmas this gave place to pains of a sharper and more shooting character, and he now perceived some swelling of the same leg below the knee on the outer side. These symptoms increased rapidly, and for seven weeks before admission he could not walk at all.

On admission the man was pale, but not emaciated. Occupying the outer side of the right leg was a large tumour, apparently springing from the upper end of the fibula, and projecting considerably from the leg close below the knee, thence fading gradually into the level of the leg at the ankle. It had thus the shape of an inverted pear. The tumour felt notably warmer to the touch than the rest of the limb; surface smooth, but raised into split-bean-like nodules here and there; skin generally adherent. At the most prominent point the skin was tense, red, and thin, and here the tumour was very elastic, almost fluctuating; for the rest it was firm, rather tender, and brawny; some enlarged veins ramified over it. The tibia and femur appeared to be free, but the knee could not be quite straightened, and it was generally kept bent to a right angle. There was no glandular enlargement anywhere, nor any sign of tumours elsewhere.

On August 13th Mr. Moore amputated the thigh, and the man made a good recovery from the operation.

Before he left the hospital, however (six weeks later), a small swelling was detected in the calf of the opposite leg. Four or five months afterwards the man died in the country, a large number of tumours having appeared in various parts of the body—chiefly in the subcutaneous tissue. None of these secondary growths were bony; all were soft, vascular, and some very painful. None of the lymphatic glands were reported to be affected, nor any of the viscera.

On dissection the tumour was found to spring from the upper half

Digitized by Google

of the fibula, without invading the other bone. The wasted pale muscular tissue stretched over and adherent to it, was also infiltrated by the growth, whose broadly tuberous surface reached the skin. A section carried vertically through the mass, showed that it was chiefly composed of what had all the naked-eye characters of dense ivory-like bone. This, however, gave place to rarer, more spongy, bony

WOODCUT 10.

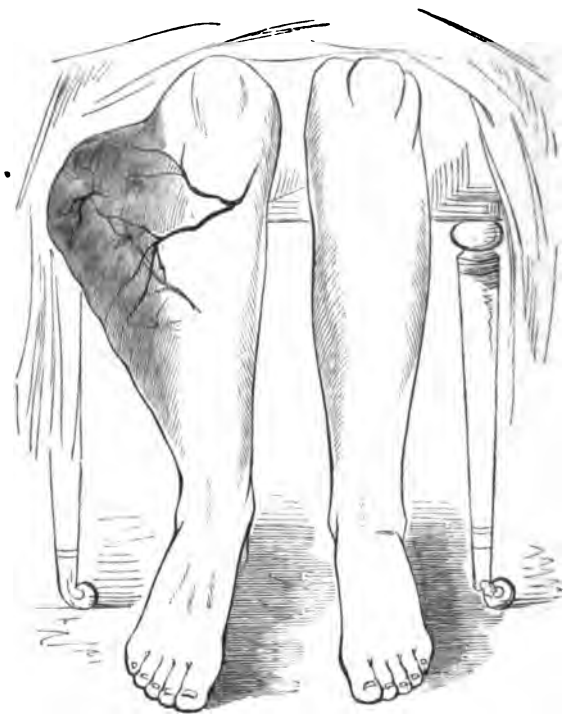

Swelling of leg produced by tumour of fibula.

tissue towards the circumference of the tumour, and here the surface yielded to the pressure of the scalpel handle, and allowed an abundant bloody fluid to well up. At other parts the cancellous structure was so loose as to form largish spaces filled with blood, and feeling like cysts to the finger applied over the surface of the swelling. The periosteum was continued over part of the tumour, as it sprang

Digitized by Google

rather abruptly from the shaft of the fibula, but was soon lost in its substance. About the margin of the growth, and extending into the neighbouring soft parts, the bony structure gave place to a soft, semitranslucent, ruddy, and yellow material, which yielded an abundant creamy juice. The same kind of matter seemed to pervade certain portions of the bone-like mass also. This juice, hastily examined in its fresh state, showed abundant proliferating cell-forms of extremely various sizes and shapes, and many containing four or even more nuclei. The nuclei more constant in form were large, oval, and nucleolated.

Sections from hardened morsels showed that the tumour generally was infiltrated with amorphous lime salts, so that its structure in many places was with difficulty made out until an acid had been applied. Then there was apparent a growth in most parts of developing fibrous tissue in various rudimentary stages; but in some places there was a richly cellular structure, with all shapes and sizes of cells, many multi-nucleated, and with a dim stiff looking fibrous network ramifying through them. There was no true bone, but such as resulted from breaking up of the fibula. The new growth blended with the muscle overlying it. *March*, 1871.

Digitized by Google

VII.—DISEASES, ETC., OF THE ORGANS OF SPECIAL SENSE.

1.—*A case of gliomatous disease of the eyeball, with secondary deposits in the periosteum of the facial and cranial bones. With specimens and drawings.*

By Spencer Watson.

Annie P—, æt. 8½ years, came under notice at the Central London Ophthalmic Hospital in the early part of the year 1869, when an intra-ocular growth was recognised as being probably a glioma, and extirpation was advised. Nothing more, however, was seen of the patient till February 21st, 1870, when the growth had very much increased and the characteristic yellow metallic brilliancy of the pupil was visible in ordinary daylight, and the globe was considerably enlarged, though still freely movable.

About March 4th hæmorrhage into the anterior chamber of the affected eye occurred, and about the same time a sudden swelling of the right malar bone was observed with an ecchymotic discoloration of the cheek and lower eyelid.

On March 14th great increase in the malar swelling had taken place, and two superficial tumours of the scalp were noticed; one in the right occipital region, of the size of a walnut, and the other of the size of a horsebean, in the left posterior parietal region. At the same time the superficial veins of the right temple became enlarged. The left eye remained to all appearance healthy, and sight good. The general health and nutrition were very slightly impaired, the only noticeable symptoms being an unusually transparent complexion, some failure of appetite, and restlessness at night. There was little or no pain either in the eye or cheek.

The first drawing represents the appearance of the child at this stage.

All hope of being able to remove the disease by operation was now

Digitized by Google

abandoned, and only palliative remedies were employed. From this time there was a rapid increase in the swelling of the cheek, and the protrusion of the eyeball. The tumours on the scalp also grew rapidly, and several others appeared at various points over the cranial bones. Pain and sleeplessness were now rather prominent symptoms, and seemed to be alleviated by potassii bromidum, in

WOODCUT 11.

Side view of face a few days before the death of the patient.

ten-grain doses. Twitching of the orbicularis oris and of the arms and legs during sleep, were also occasionally noticed and occasionally the child woke up suddenly with a start and a scream, but there was no delirium, and no convulsions, nor was consciousness at all impaired either at this time or subsequently. The rapid growth of the tumour is seen in the two drawings made respectively on April 26th and on May 10th. The last was made two days after the death of the patient, which happened rather suddenly (see Fig. 12).

Digitized by Google

Towards the last the left eyeball became enormously protruded from a growth within the left orbit, but the eye itself, though atrophied, did not appear to have taken on the specific disease.

WOODCUT 12.

To show the extension of the disease to the left orbit.

No *post-mortem* examination could be obtained, with the exception of the inspection of the right eye and of a portion of one of the tumours of the scalp.

Family history.—The father and mother are delicate looking but not strikingly so, and have several other children, all healthy. There is no history of cancer in the family on either side.

Microscopic examination of the growths in the right eyeball and of the portion of tumour of the scalp in the occipital region.—The eyeball, when cut across vertically through the optic nerve, exhibited a mass of cream-coloured, putty-like substance occupying the whole of the vitreous space and thrusting the crystalline lens, which was still transparent, forwards against the posterior surface of the still

Digitized by Google

transparent cornea. The choroid was almost entirely atrophied, but a trace of it remained at several places, and smaller masses of the same putty-like material lay between it and the sclerotic at these points. The optic nerve was much enlarged at the sclerotic ring, and had a pale, pink, fleshy, but somewhat translucent texture. This part of the growth gave evidence of gliomatous disease, being made up of closely aggregated nuclei, lying in the interstices of delicate fibres, with a few very delicate fibrillæ supporting the masses of nuclei. Here and there a few granular corpuscles were seen.

The putty-like mass in the vitreous space consisted mainly of fatty granules with a few granular corpuscles. It was entirely non-vascular and easily broke up into separate granular masses on the slightest touch, being of about the consistence of rotten cheese.

The tumour removed from the scalp lay between the pericranium and the bone, and was firmly adherent to the latter, from which it could only be separated by the edge of the knife. It was divided by numerous fibrous septa running in a direction vertical to the surface of the bone. The microscopic characters were exactly similar to those of the optic nerve, but with considerably more fibrous material intervening between the masses of nuclei.

October, 1870.

---

2. *Demonstrations of diseases of the eye.*

By R. Liebreich (introduced by Dr. Dickinson).

In accepting the kind invitation of Dr. Dickinson to give a demonstration with the ophthalmoscope, I foresaw two difficulties. The first was the want of patients who could serve as subjects. The second, my exceedingly imperfect knowledge of the English language.

Messrs. Carter, Soelberg Wells, Cooper, Jackson, and Bader, have most kindly offered to remove the first of these difficulties by sending here some interesting cases from their own practice, which I will submit to your observation. The second difficulty will be, I hope, obviated in part, at least, by the indulgence you will kindly accord to a foreigner.

Digitized by Google

As it is necessary in every pathological observation to take, as a starting point, the comparison with the normal condition, I will begin by showing you the fundus of the healthy eye. There you will see the papilla of the optic nerve as a light disc surrounded by a red fundus, which is formed by the choroid. From the centre of this disc arise the vessels of the retina, and you distinguish easily the arteries, as finer and lighter, from the veins which are darker and of a greater diameter.

After this subject I am going to present you another, an exceedingly interesting case of a congenital anomaly, which is very rare; it is persistent hyaloid artery and vein.

WOODCUT 13.

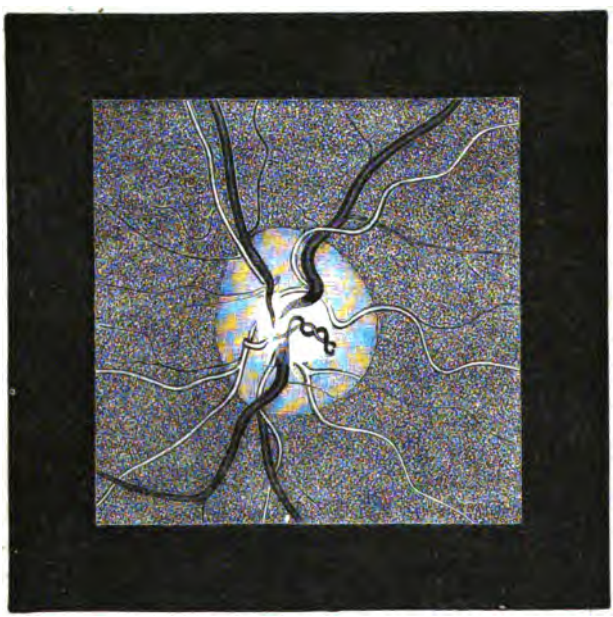

I have never seen so fine a specimen of this anomaly as one which occurred in the practice of Mr. Soelberg Wells, and of which I will show you here the drawing I made of it. Here you will see, arising from the artery of the optic disc, a little branch which runs in nearly a straight line into the vitreous humour. It soon terminates in a loop which

Digitized by Google

seems to make a direct transit from the artery to the vein, and the latter returns to the papilla by intertwining itself obliquely with the artery three times. It terminates at the central veins in a point which it is not easy to observe because it is situated in the fundus of the physiological excavation of the optic disc. In order to enable you to recognise the direction of these little vessels it suffices to make a slight lateral movement of the objective of the instrument, or what will be the same, of the eye under observation. During this experiment you will see the vessels of the vitreous humour making an apparent movement in displacing themselves before the optic disc, and more strongly with the anterior end. This observation of parallax is very easy in this case on account of the relatively great distance between the anterior and posterior end, but I have recommended this same movement as an excellent means of diagnosing the slightest differences of depth. You may, by this means, form conclusions in a manner, at least, as reliable as with the binocular ophthalmoscope.

The change most frequently observed with the ophthalmoscope is the posterior staphyloma. This affection, which occasions short-sightedness by the lengthening of the antero-posterior axis, is characterised ophthalmoscopically by symptoms of choroidal atrophy about the posterior pole of the eyeball, and above all at the circumference of the optic disc. You will observe at the margin of the nerve a white crescent within the limits of which the sclerotic appears quite denuded, which is due to the complete atrophy of the choroid at this point.

A much less frequent affection of which the diagnosis is the more important, as it offers a very favourable chance of cure, is the *choroiditis disseminata*. In the patient that I will bring before you, you will be able to make almost microscopical observations on the state of the cells of the choroid. In some places these cells are atrophied, or at least, deprived of their pigment, and small, more or less light, spots are visible. The darker patches, on the contrary, are formed by the epithelial cells of the choroid which have undergone changes in form, size, and contents. As the latter becomes darker you observe each cell isolated like a little black point. It is important not to confound this disease with *retinitis pigmentosa*, which might happen to an inexperienced observer. You see the two affections represented on plate vi of my 'Atlas,' fig. 1, *Retinitis pigmentosa*, fig. 2, *Choroiditis disseminata*. The black spots in retinitis pigmen-

Digitized by Google

tosa are found, as you know, in the retina itself; you recognise them easily in the second figure, as in the case I will show you, by the manner in which some of these black lines accompany the vessels of the retina where they cross the pigmentary zone, which surrounds the optic nerve. This affection, which I found, almost ten years ago, to be, in nearly half of the cases, the result of marriages of consanguinity, is generally developed in early childhood. I shall be able to show you an instance of this affection fully developed in a child of eleven years of age.

The greater part of the affections of the retina and of the optic nerve are, on account of their relation to the different affections of the heart, kidneys, brain, and spinal cord, of great interest to all physicians who do not confine themselves specially to ophthalmology. I should therefore have particularly wished to show you such cases, but it was difficult to find them. However, Dr. Jackson has sent here a very fine case of *neuritis optici*. You will see there the optic disc completely changed. Its contours have disappeared, the substance of the papilla has become opaque, and so thickened that it forms a prominence, the surface of which is indicated by the course of the veins which, on account of the impediment of the circulation, are become swelled and tortuous, while the arteries are so thin that one has a difficulty in finding them. You will be struck by the great difference in the aspect of the optic disc between this case and cases of atrophy of the nerve and of glaucòmatous excavation of the papilla, of which we shall have a very fine specimen for observation.

If the subject to which you have kindly given up the sitting of this evening seems to depart from the ordinary occupation of this Society, I still hope that you will find that ophthalmoscopy, by the clearness with which it permits us to make anatomical, and even microscopical, observations, merits the attention of all who devote themselves to pathological anatomy. *Dec. 6th*, 1870.

Digitized by Google

3. *A case of bony deposit in the eye associated with a peculiar deposit on the cornea.*

By W. Spencer Watson.

J. L—, æt. 36, a brewer's porter, came with sympathetic ophthalmia of the right eye to the Central London Ophthalmic Hospital on October 6th, 1870. He had been injured on the left brow by a blow from a stick twenty-five years ago, and this eye had been quite blind ever since. Recently sympathetic irritation of the right eye had shown itself, and on October 11th the blind injured eye was removed, with the effect of removing almost all the threatening symptoms in the comparatively sound eye.

Before removal of the eye some very peculiar appearances were noticed. 1st. The cornea had an oval opacity covering its central region and extending laterally quite up to its margin. This opacity had a grayish-white colour, and had cracked in the centre and peeled off so as to leave a comparatively clear space in the middle. 2nd. The pupil in ordinary positions of the eye was only dimly visible; but when the patient looked suddenly downwards, the papillary area was seen above the corneal opacity, and was occupied by a yellowish body, evidently an altered lens, which was movable, and fell back out of the area of the pupil, when the eye was again turned upwards. 3rd. The eye was hard to touch, but its consistence did not lead to a diagnosis of ossific deposit.

A section carried through the sclerotic a little to one side of the optic nerve showed a thick deposit of bone lying immediately within this tunic, but covered by the atrophied remains of the choroid. In order to reach the centre of the eyeball a small watch-spring saw was used to divide this bony deposit, which was then found to be about one eighth of an inch thick, and to form a cup, lining the whole of the sclerotic up to the ora serrata. Inside this remains of the vitreous were found still almost transparent, but with a central cavity containing serum. The hyaloid membrane, much thickened, closed in the front of this cavity, and upon it the lens rested, and was partially adherent, but freely movable with it as the eye moved.

The lens itself was converted into a dense, porcelainous, yellow mass, which under the microscope gave no evidence of bony structure and was nearly as hard and brittle as porcelain. Some of the

Digitized by Google

fragments of this porcelainous material were almost crystalline in appearance, and assumed a rhomboidohedral form, but the majority had a granular semiopaque structure, with an irregularly chipped fracture; and in some places an appearance of closely aggregated cells projecting from the surface presented itself.

The bony cap above described had well-developed lacunæ and a few canaliculi, and a general arrangement resembling that of the cancellated tissue of bone. No trace of the retina was discoverable.

The deposit on the *cornea* consisted of opaque epithelial cells, which resisted the action of strong acetic acid, retaining their cellular structure under the microscope after immersion in this acid. They, therefore, had probably undergone calcification.

The appearance of the deposit on the cornea during life closely resembled that of the cases exhibited by Mr. Fairlie Clarke and recorded in the last volume of the 'Transactions' of this Society, but this case differs from those in the circumstance that the opacity was unilateral and occurred in a completely disorganised eye.

December 20*th*, 1870.

---

4. *A case of bony deposit in the eye, the result of injury and cause of sympathetic ophthalmia.*

By W. Spencer Watson.

J. G—, æt. 40, was injured, eight years ago, in the left eye by a blow of the fist, which burst the eyeball. It had shrunk to about half the size of the normal eye, and had lately become very tender to touch. The sight of the right eye had been getting more and more impaired ever since the accident, and he was now only able to read letters of large type (No. 16 of Jaeger's test-types).

On November 17th the left eyeball was enucleated at the Central London Ophthalmic Hospital, and the result has been very satisfactory, the sight of the right eye having improved very much since.

A section of the eyeball (left) shows a disk-like, nearly circular deposit lying around the entrance of the optic nerve, and lying partly in the remains of the choroid. Inside the wasted choroid a serous fluid occupied the sub-retinal space, and the retina itself formed a

Digitized by Google

funnel-shaped scroll, with the broad end attached to the agglutinated remains of the lens, iris, and ciliary processes.

A microscopic examination of the bony disk gave evidence of well-formed bony tissue, arranged in tubular and funnel-shaped laminæ surrounding areolar spaces, which freely communicated with each other. In some of these funnel-shaped and tubular bony shells traces of vessels were found, which were probably those of the choroid.

December 20th, 1870.

---

5. *An ivory exostosis growing from the sclerotic coat of the eye.*

By W. Spencer Watson.

Victor D—, æt. 13, presented himself at the Royal South London Ophthalmic Hospital in December, 1870, with a small tumour on the upper and outer side of the left eyeball. He had noticed the growth only during the last two months, and it had rarely caused him any inconvenience, though it had been occasionally painful at night; and as it seemed to be increasing in size, his mother expressed a wish that it should be removed.

It had an oval form, of the size of a threepenny piece, and yellow shining surface, and resembled to the eye a small fatty tumour. It was situated about midway between the insertions of the superior and internal recti muscles, and was therefore completely hidden by the upper lid in the usual positions of the latter.

On December 30th Mr. S. Watson transfixed the soft tissues overlying the tumour with a scalpel, the point of which came into contact with a hard substance; the soft fat and areolar tissue was then dissected off the surface of the tumour and a roundish button of bone exposed. This was attached by a broad base to the sclerotic, which was easily divided by scissors and had a cartilaginous appearance and consistence. The wound quickly healed.

On testing the sight it was found that a great degree of hypermetropia existed in both eyes, requiring a convex glass of twelve-inch focal length to neutralise it; but that there was besides in the left eye a great want of acuteness of vision, so that the boy could only read Jaeger's test-types No. 12, with this eye, though with the other eye he could read No. 6 of the same test-types.

Digitized by Google

An ophthalmoscopic examination showed only a congested condition of the retinal veins at the fundus of the eye, but there were no intraocular changes at the point corresponding with the position of the external tumour.

WOODCUT 14.

Bony laminæ and Haversian systems in the exostosis of the sclerotic.

A section of the tumour, which is a flattened disc of about the size of a pea (dry), shows it to consist of true bony laminæ very closely compacted, and with a few Haversian systems and canals. A microscopic examination of the softer tissue through which the bone was united with the sclerotic failed to give evidence of cartilage, probably from its having been somewhat carelessly and roughly used immediately after removal. *February 7th*, 1871.

Digitized by Google

VIII. TUMOURS.

1. *Papillary growth of abdominal wall.*

By Francis Mason.

Mr. Francis Mason exhibited a papillary tumour four inches in length, and one and a half inches in width, which he had removed from the abdominal wall of a girl, æt. 20, at the Westminster Hospital. The growth was *congenital*, and, with a similar one about the size of a pea close to it, had never given the slightest pain or inconvenience locally. She wished to have the tumour

Woodcut 15.

removed solely on account of an offensive but very slight discharge, secreted and oozing from between the papillæ, which prevented her from keeping a situation as a servant. The tumour, including the small one, was removed, and the patient rapidly recovered. The structure is of the ordinary warty character; the length of the papillary growths ranging from a line to half an inch.

November 1st, 1870.

Digitized by Google

2. *Tumour of breast.*

By JOHN FOSTER, for Mr. JOSEPH THOMPSON, of Nottingham.

THE accompanying specimen was removed from Harriet T—, æt. 58 years, a married woman, residing at Balwell, who was admitted into the General Hospital on October 12th, 1870.

She gave the following account:—She first noticed "a lump" in her right breast, soon after her first and only child was born, thirty-six years ago; it was then about the size of an egg; had very little milk in that breast, and states that, as she had not much pain in it, she thought nothing of it.

The tumour remained stationary, without any inconvenience except slight occasional "twinges," until seven years ago, when she ceased to menstruate, having been quite regular up to that time. Never had any injury to the breast; has always had more or less pain springing from the centre of the breast for the last seven years, during which time it has grown gradually larger. Pain increased as it enlarged, and it became very inconvenient from its size. The woman herself attributes some of the pain she suffers to the *weight* of the tumour. No axillary pain or enlarged glands. The tumour can be freely moved, does not appear to be adherent in any part; it is large, lobulated, and fluctuating in parts; is evidently "cystic." Skin is discoloured, and adherent about the nipple, which is retracted. Skin began to change colour, and nipple to retract about a year ago.

No family history of cancer, or other disease of importance. She is a stout healthy-looking woman, but says she has felt weakly, and accounts for this by saying that she has had several attacks of floodings, one of which occurred while she was under observation. A fibroid uterine polypus was found and removed on October 25th, since which she has been quite free from discharge. She was quite unaware of the existence of this growth.

The breast was removed under the influence of chloroform on November 1st, 1870, by elliptical incisions; there was a fair amount of hæmorrhage from enlarged veins, but only four ligatures were required; the wound was washed out with carbolic acid lotion, and the lips brought together.

The tumour, after removal, weighed ten pounds, and measured $27\frac{3}{4} \times 22$ inches in circumference. The specimen has been purposely left intact, for examination by the "Committee on Morbid Growths."

December 6th, 1870.

Digitized by Google

3. *Epithelioma of the heart and lungs, secondary to epithelioma of the clitoris.*

By Henry Arnott.

The patient from whose body these specimens were removed was a woman, æt. 50, who was admitted into the Middlesex Hospital under the care of the late Mr. Moore, November 2nd, 1869. Twelve months before she had complained of pains and swelling in the clitoris, and four months ago the disease had been cut away, but had speedily returned and spread with greater energy than before.

On admission this time there was a fissured, hard, nodulated, and extremely painful tumour in the position of the clitoris, the size of a walnut, bathed in a scanty fœtid discharge, and both groups of inguinal glands were enlarged. On November 10, 1869, Mr. Moore removed the whole of the growth, but the diseased glands in the groin ulcerated and spread rapidly, and the woman sank on February 8th, 1870.

At the autopsy, both lungs were found adherent to the chest walls. The right lung was closely bound at its apex, both anteriorly and posteriorly, but a limited cavity was formed in the pleura below this part, containing nine and a half ounces of thick turbid fluid. There was about one ounce and a half of like fluid in the left pleural cavity, and this lung was also closely adherent to the chest wall in places, especially about the posterior part of the upper lobe. The pleura of the parietes on either side contained nodules of cancer, and the pleura of the greatest portion of the right lung was thickened to about one eighth of an inch, rough on the surface, and could be pulled off only with great difficulty. Both lungs were studded with small masses, chiefly sub-pleural, but also imbedded more deeply, and mainly in the lower lobe.

The heart was somewhat fattily degenerated, and contained three or four pale nodules, resembling those in the lungs imbedded in the substance of the right and left ventricular walls.

These nodules were all of the same appearance, pinkish-white, moderately firm, but granular-looking on section, and those on the

Digitized by Google

surface of the lung were not umbilicated. The nodules faded into the substance of the diseased organs, and could not be enucleated.

The other viscera presented no lesions worth noting.

Examined microscopically, the nodules in the heart and lungs presented precisely similar appearances to those of the masses in the groins, viz. a confused heaping together of large, coarse, squamous, epithelial scales, of which many were collected into nests, and some showed traces of endogenous cell-formation. At the margins of the nodules these cells were seen to mingle with the elements of the adjacent tissue. (See plate III, fig. 3.)

Remarks.—This case has been brought forward as an instance of what has been usually quoted as an extremely rare occurrence namely, genuine epithelioma invading the heart and lungs. I think, however, that it is possible that this free extension of the disease has been frequently overlooked, for during the past year I have myself encountered two instances; one (also a case of the late Mr. Moore's) of epithelioma of the face, in which a gland below the chin and the lungs were frequently involved; and another (under the care of Mr. Nunn), in which, together with epithelioma of the face and cervical glands, there was a large isolated mass of the same structure invading the sternum. In a former volume of this Society's 'Transactions' I have also described a case of epithelioma of one supra-renal body, occurring with the same disease in the tongue. Besides these four cases now referred to, there are in earlier volumes of the 'Transactions' five other instances—(1) by Mr. Spencer Wells of epithelioma (doubtful) of the breast, in which liver and lungs were affected (Vol. IX); (2) by Mr. Sibley, in which the same disease appeared in the tongue, and in one supra-renal capsule (Vol. X); (3) by Mr. J. Hutchinson, in the tongue and lungs (Vol. XIII); (4) by Dr. Dickinson, of the glans penis, inguinal glands, and heart (Vol. XIV); and (5) by Dr. Moxon, in which epithelioma of the trachea spread generally through the lungs (Vol. XX). In the last case the transference of the cells of the epithelioma is readily intelligible, but in some of the others the mode of infection is as difficult to trace as in the case under consideration, where heart and lungs suffered secondarily to a disease of the clitoris. *April*, 1871.

Digitized by Google

4. *Fibro-cystic tumour from the axilla.*

By Christopher Heath.

The tumour exhibited was conical in shape and closely resembled a bullock's heart in appearance. It weighed three pounds and three quarters. A section showed a fibrous structure with irregular cavities interspersed throughout it. The texture of the growth was very firm and the colour white except towards the centre, which was softer and of a faint yellowish colour. The microscopic appearances were those of a fibro-plastic growth.

The following is the history of the case from notes by Mr. Beck, the Surgical Registrar of University College Hospital.

Rebecca Jane H—, æt. 49, housewife. Admitted Oct. 20th, 1869, into University College Hospital, under Mr. Erichsen.

History.—Had good health up to sixteen years ago, when she had two abscesses in the right mamma. While in the Bedford Infirmary for these abscesses she was told by the surgeon that an indolent tumour was forming in the region of the right shoulder. At this time she could notice nothing. When seven years old she had had a blow on the right shoulder, but had suffered no permanent inconvenience from it. Four years after she was in the Bedford Infirmary (*i. e.* twelve years ago) she began to feel some tightness in the right armpit. About five years ago she noticed a small lump between the right axilla and the mamma. This swelling had increased ever since, but more rapidly during the last eight months. It had never been painful or tender, but there was a considerable feeling of tension in it. For the last three years she has had occasionally "pins and needles" and spasms of the muscles of the right arm. These have much increased of late. The hand and fingers now feel moist and dead. The patient has not lost flesh during the growth of the tumour.

State on admission.—The tumour filled up the whole right axilla, pushing the shoulder upwards and reaching downwards as far as the sixth rib. It showed most clearly in front, being covered behind by the scapula. Its surface was covered with blue veins forming a net-

Digitized by Google

work. The skin was of natural colour. The skin was freely movable over the surface of the tumour, which was even and smooth. The whole tumour could be moved freely over the ribs by raising the shoulder, but the scapula moved with it under all circumstances. The head of the humerus rotated freely in the joint, and was evidently in no way connected with the tumour. Crossing over the upper part of the tumour from a point a little internal to the middle of the clavicle to the arm was the axillary artery. It took a long curve with the concavity upwards, being distant about two inches and a half from the clavicle at its lowest part. It could be seen pulsating

WOODCUT 16.

Fibro-cystic tumour of axilla.

quite superficially, and pressure on it stopped the pulse at the wrist. There was no difference between the two radial pulses. The hand was slightly œdematous. The elbow could not be brought within nine inches of the side. The mamma on the right side was atrophied, and from the stretching of the skin had been drawn over the tumour so that the nipple was situated over the lower and inner part of the mass. The woman looked healthy, and was by no means thin.

November 2nd.—Mr. Erichsen, on careful examination, detected deep fluctuation at the lower part and put in a small trocar when about 2¼ oz. of clear, serous fluid escaped.

Operation.—9th.—The axillary artery being held out of the way and compressed, Mr. Erichsen made a transverse incision below it

Digitized by Google

and another vertically to the lowest part of the tumour. There was a free gush of venous blood, which soon ceased. The flaps were dissected up and the tumour exposed. It was found to be beneath the serratus magnus muscle, which was tightly stretched over it. The tumour was surrounded by a loose fibrous capsule, and was "shelled out" of the space in which it lay with comparative ease and almost without the use of the knife. But little blood was lost. Thirteen

WOODCUT 17.

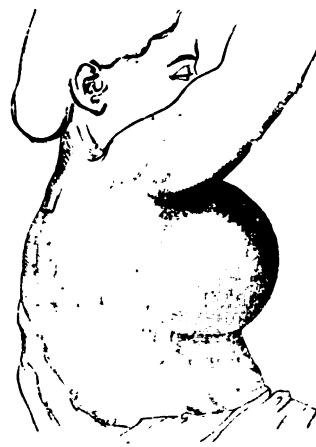

Fibro-cystic tumour of axilla.

small vessels required ligature, and one dilated vein was tied in two places. The wound was washed out with carbolic acid and cleansed with carbolic acid lotion. In the evening there was some slight hæmorrhage, for which the wound was plugged with dry lint.

The patient recovered without a single bad symptom. The wound suppurated freely, but was nearly healed one month after the operation. *December 6th*, 1870.

Digitized by Google

5. *Case of large lymphoma in the pectoral region.*

By C. De Morgan.

I. T—, æt. 45, was admitted into the Middlesex Hospital on the 18th January, 1871. He is a strongly built, fresh complexioned, active man, with every appearance of health, a painter, married, and with seven healthy children. He has always been a very temperate and careful liver. His family history is good. He believes he had a blow on the breast six years ago. He has a large tumour in the breast, running up to axilla.

His history is that up to about four years ago he had never had anything the matter with him. Then he had some skin disease, as he describes it, but which, from the account of Mr. Hodson, of Bishop Stortford, who attended him, was a brawny œdema of trunk and limbs, not extending beyond the wrists and ankles. There was no albumen in the urine, nor any evidence of disease of internal organs. From this he recovered under the use of vapour baths and iodide of potassium. But before this time it seems he had noticed some œdema about the left breast. This was variable, sometimes going away altogether, sometimes becoming very marked. The œdema was unaccompanied by pain.

Somewhere about the same time he noticed a swelling in the neck above the left clavicle, which, he says, was certainly much larger two years ago than at present, as he was obliged for a time to have his collars enlarged on that side. Indeed, by measurement, he found that the neck was an inch and a half larger on that side than on the opposite.

During this period, from three to four years ago, he was out of health generally, but for the last two years his health has been improving, and he now feels as well as he ever did.

There is a tumour extending from inside and below the left nipple outwards towards the axilla and angle of the scapula. It measures 10½ inches across and 7¼ inches from above downwards. Its projection from the side is so great that the arm is kept nearly at right

Digitized by Google

angles to the trunk. It appears movable in all directions, but its boundaries, except in the axilla, are obscure. The pectoralis major clearly passes over it. It is not connected with the scapula, which moves freely without affecting it. In the axilla it forms a nodulated defined tumour, which, in parts, seems to present a line of demarcation between it and the main mass, but is clearly continuous with it.

WOODCUT 18.

External swelling caused by the tumour.

The finger can be passed above this nodulated part into the depth of the axilla, and the axillary artery can be felt above it, neither surrounded nor pressed on by it. There is no marked difference in the radials on the two sides nor œdema in the arm. The skin over the tumour is œdematous. The mass is generally firm and elastic, save at the most prominent part towards the outer side, where distinct fluctuation can be felt, and the skin is getting thin and bluish-red and adherent to the mass. The veins over the surface are large, especially towards the back. There is not the least tenderness or pain of any kind. He is confident that he never was conscious of a darting pain in it, nor is there any pain after prolonged examination.

Digitized by Google

Except at the nodulated portion running up into the axilla the surface of the mass is generally smooth; but there are some projections about the prominent softened part. His own impression is that the tumour began, about eleven months ago, towards the lower and inner part, but before he noticed any defined tumour there was considerable œdema of the side. Within the last two or three months the growth of the tumour has been very rapid. He carried on his business to about a fortnight before his admission, and then his only trouble was the inability to bring his arm down towards his side.

Some two years or more before the tumour in the side made its appearance he noticed the swelling in the neck. It projects from the anterior third of the first rib upwards and somewhat inwards; it is about two inches in length and an inch wide, very hard, indeed almost cartilaginous in feel, slightly movable at its base, and like the larger tumour quite painless; towards the apex is a small, movable, hard lump about the size of a pea. This tumour in the neck, as stated above, was a couple of years ago very much larger than it is now, and, indeed, it has been diminishing up to the present time. He has now no inconvenience from it.

The mobility of the tumour, its recent rapid growth, the certainty that it would soon give way, and the fact that in its present state it entirely incapacitated the man for work, led me to consider the propriety of attempting its removal. The patient is remarkably intelligent and well educated, and was himself anxious that an operation should be performed.

The nature of the tumour was doubtful; it certainly was not scirrhus, it might be encephaloid; but there were characters about it which were somewhat opposed to this view. It had probably been growing for a longer time than he supposes. Though the slow growth during the early period is certainly not incompatible with the existence of encephaloid, it is exceptional rather than otherwise. But it is a very rare thing to find a patient improving markedly in health and muscular vigour while an encephaloid tumour is growing rapidly, as has been the case during the last ten months. The mass itself, though to a certain extent elastic, had not that peculiar soft elastic feel which is constantly present in rapidly growing encephaloid tumours. The diminution in the size of the neck tumour, while that in the breast was rapidly growing, would be more consistent perhaps with encephaloid than with fibroma, and perhaps the existence of this separate tumour would point to a cancerous

Digitized by Google

origin, though it might occur in connection with a fibroma. As it was undoubtedly undergoing degeneration its presence was not allowed to interfere with the attempt at removal of the rapidly advancing main tumour.

Keeping the patient under observation for a week I found that the dimensions of the tumour had increased by one inch in each direction in that short time. It was resolved that its extirpation should be attempted. The total absence of all other disease in the patient gave a promise of a good recovery from the operation.

While under chloroform the fluctuating part was tapped and the fluid examined microscopically. It was clear and straw-coloured, and contained only granules and exudation corpuscles. The operation was then proceeded with and proved difficult and tedious. The tumour lay beneath the pectoralis major and minor in front, and adherent to the latissimus dorsi behind; it was in close proximity to the great vessels, which were exposed in the axilla to the extent of about two inches. Its principal feeding vessel was the subscapular artery, and this could only be ligatured very near to the axillary; numerous large venous and arterial branches passed into the tumour from the side of the axilla. The difficulty lay in the adherence of the boundaries of the tumour to the surrounding parts, so that it had to be cut out instead of shelling out, as had been hoped.

Up to this time the patient has not had a bad symptom. The great chasm formed by the removal of the mass had nearly closed in, and he was up on the sixteenth day after the operation.

The tumour weighed 4½ lbs. after removal. Its bulk was greatly lessened by the opening of the cysts which it contained. On section it appeared lobulated, pinky, save in a large central cyst which contained a quantity of yellow, curdy matter, and appeared to have a decided cyst wall. Between this and the surface was another cyst which had been punctured before the operation, and had soft pulpy contents. In other parts degeneration was going on. No juice exuded from any part of the section, it presented to the naked eye the characters of a fibroma.

Mr. Arnott was good enough to make a careful examination of the tumour, and his report is as follows:

"Examined microscopically, sections from different parts of the greyish, firm material forming the bulk of the tumour, showed a structure which has somewhat frequently been described of late in

Digitized by Google

this Society, and with special care and minuteness, by Dr. Sanderson in the last volume of the 'Transactions,' under the name of lymphadenoma. That is to say, that numerous small spherical corpuscles resembling those of a lymphatic gland or white blood-corpuscles were contained in an alveolar stroma of clear homogeneous substance. This stroma was in some places of extreme delicacy, the fine network only coming into view after carefully pencilling out the corpuscles, or repeated washings of a thin section. Under this

WOODCUT 19.

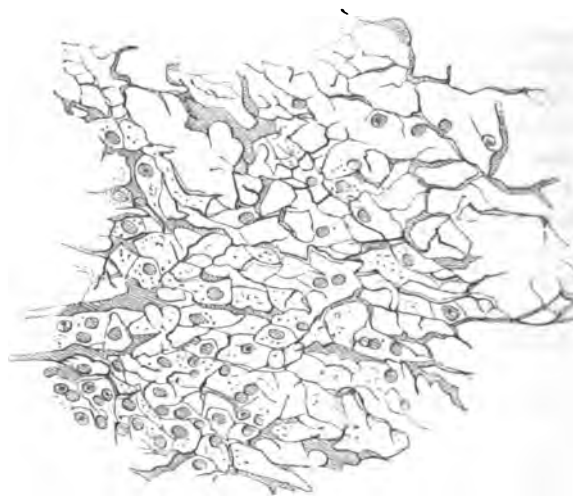

Microscopic structure of tumour.

treatment a lacework, of great irregularity both in the size of the meshes and in the breadth of the alveolar walls, was discovered (see sketch) in parts which had before seemed almost wholly corpuscular. In other parts the fibroid material was greatly in excess of the corpuscles, forming broad clear tracts, and a dense intricate network with only a few small slit-like meshes.

"Other portions showed dense clusters of similar nuclei only more granular, and much resembling in their degenerated appearance and close packing, the flaky material in chronic abscesses, these clusters breaking up into a fatty débris here and there. One point

Digitized by Google

worthy of special notice is that in some few places the spherical corpuscles—which were generally small and merely slightly granular, although sometimes larger and distinctly nucleated—gave place to cells of considerable size and much diversity of form, suggesting a transition into one of the Sarcomata. These cells resembled the larger ones met with in a granulating sore, and in forming fibrous tissue, and have not been usually described in connection with these lymphoma tumours."

There are some points of considerable interest about this case, if it be one of lymphadenoma, and similar in nature to those recorded by the authorities cited by Dr. Murchison in his paper in the last volume of the 'Transactions.' In all the cases referred to progressive emaciation was a marked symptom. This was due apparently to a widely-spread affection of the lymphatic system. In the present case the reverse has been the case. The patient has undoubtedly gained strength while the large tumour has been growing rapidly. This is the man's own conviction, and it is confirmed by Mr. Hodson. It may be that a solitary tumour of this nature may not have any influence on nutrition, or may exist independent of any general affection of the lymphatic system. In Dr. Powell's case, in the last volume of the 'Transactions,' the tumour was in the anterior mediastinum and solitary, and the general symptoms were only such as would be accounted for by a large growth in that region. In the present instance, however, the tumour can hardly be regarded as a solitary one; and we must, I think, regard the growths in the neck as having been of the same nature as that in the chest, and as having been associated with some more general disease of the lymphatic system. We find that, about the time of the appearance of the neck tumours, he got out of health, and then appeared a peculiar condition of general œdema, brawny, but in no way involving the hands or feet, nor, I believe, the face. This could not depend on the tumours in the neck, which were on the left side only, and it would be difficult to believe that there were any deeper-seated tumours pressing on the vessels without other and more marked symptoms, especially when attended with such complete recovery. Altogether I should be inclined to think that the œdema was more connected with the lymphatic than with the venous system. It is clear, however, that while retrogression has been taking place in the tumours in the neck, accompanied with entire disappearance of the œdema, the tumour in the chest has been developed, and that it made rapid

Digitized by Google

growth, the patient's general health meanwhile improving instead of being impaired, as one would suppose it would be.

Although one cannot but fear that there may be recurrence of the disease, the rapid recovery after so extensive an operation leads me to hope that, as yet, there is no infection of internal organs. The tumours in the neck have remained perfectly quiet and unaltered since the operation. *February* 21*st*, 1871.

Report by the Committee on Morbid Growths upon Mr. De Morgan's specimen of lymph adenoma of the axilla.—We have examined thin sections from various parts of this tumour, and we find that the microscopic appearances resemble in all points those of a lymphatic gland in a state of irritation or chronic inflammation. These appearances have been so fully and lucidly described by Dr. Sanderson in a report upon a somewhat similar case to the present, exhibited by Dr. Murchison during the last session ('Path. Trans.,' vol. xxi, pp. 384—386), that we think it unnecessary to enter into any further description of them here. W. Cayley,

March 21*st*, 1871. Henry Arnott.

---

6. *Lipoma of nose.*

By Christopher Heath.

The photographs exhibited were taken from a patient, æt. 62, who had suffered from enlargement of the nose for twelve years. The whole face was more or less covered with acne rosacea, and the hypertrophy of the skin extended to the bridge of the nose. There was a history of inebriation in early life, but not for some years past. Mr. Heath removed the growths in University College Hospital in June, 1870, and the patient made a perfect recovery. The second photographs were necessarily taken before the skin had quite cicatrised, so that the appearance shown was not quite so good as it would otherwise have been. There has been no return of the growths.

Digitized by Google

The growth was necessarily destroyed in the operation. It presented both to the eye and microscopically all the appearances of simple hypertrophy of all the tissues of the skin, and the over distension of the sebaceous follicles by large quantities of sebaceous matter which escaped during the operation was well marked in this as in other instances of the kind. *December 6th*, 1870.

---

7. *A case of recurrent tumour of the front of the leg.*

By W. Spencer Watson, for Dr. J. Swift Walker, of Hanley.

"A. W—, a single woman, æt. 31, has always enjoyed good health. Her family history shows no tendency to cancer.

In April, 1870, she perceived a small tumour, about the size of a filbert, on upper third of leg, midway betwixt tibia and fibula, apparently just below the skin.

In July, 1870, she applied to a surgeon, who gave her some iodine ointment to use; from this time it rapidly enlarged, until it had attained the size of a bantam's egg. It was quite soft to the touch. In about a week from her first application for advice the surgeon opened it, when a black fungoid mass protruded, which bled freely on being touched.

In August, 1870, as the leg seemed to be getting worse, and the pain on standing or walking being very severe, she applied to Dr. Walker.

She then presented the following appearance:—A thin phlegmatic young woman, considerably emaciated, walked with difficulty, owing to pain and weakness of the leg. A large black fungoid mass protruded from a small incision about half an inch in length. The entire tumour was quite movable, and seemed to be superficial and about the size of a hen's egg. The part which protruded from the incision was apparently half strangulated and bled on being touched. The surrounding tissues were much inflamed.

There was no enlargement of the glands in the groin, nor any sympathetic inflammation whatever.

Digitized by Google

August 4th, 1870.—The patient having an objection to chloroform, the entire tumour was congealed by Richardson's æther spray apparatus, and removed. The margins of the former incision were also freely pared. The wound was dressed with carbolic acid lotion.

On September 5th, 1870, the wound had nearly healed, but at its lower part another tumour was growing, which had already attained to the size of a walnut. This was excised, and with it a thin slice of cellular tissue to ensure its complete extirpation.

All went on favorably until

September 9th, when the tumour was found to be again growing. It was thoroughly broken up by potassa fusa, which caused profuse bleeding.

12th.—Potassa fusa was again applied.

16th.—As the tumour was again growing very rapidly it was again excised. The wound healed rapidly and was entirely cicatrised, with the exception of an area of one inch by a quarter of an inch, when the tumour again showed itself. In a week from this time it had grown to the size exhibited by the specimen; accordingly, on November 9th, having congealed it by the æther spray, an elliptical incision, four and a half inches in length, was made, enclosing all the previous eschars, and cutting down to the muscles, a portion of which were removed with the tumour. There was little bleeding, and the wound has now filled with healthy granulations.

This case presents four points of interest—1st. The persistency of its return. 2nd. The increased size on each return. 3rd. The great improvement of the health of the patient on removal of tumour. 4th. The intense hæmorrhage on abrasion of its surface.

What is its real character?"

The specimens exhibited are the tumours removed on September 16th and November 9th respectively. The former was of the size of a filbert, and, when examined microscopically, was found to consist principally of spindle-shaped cells and a few round cells closely packed in a fibrillated manner. Here and there a patch of effused blood was seen lying among the cellular elements. These patches of hæmorrhage seen by the naked eye had a close resemblance to deposits of melanotic cancer, but this appearance was partly due to the alteration they had undergone from immersion in spirits of wine.

The larger specimen consists almost, if not entirely, of spindle-

Digitized by Google

shaped cells. The tumour is distinctly circumscribed, and lies in the areolar tissue, between the skin and the adjacent fascia. Dr. Walker evidently cut quite clear of the tumour on every side, and has even removed a portion of the muscle beneath it, which does not appear to be involved in the disease. Nevertheless, he reports that, on visiting his patient on December 16th, a tumour of the size of a hazel-nut had made its appearance at the upper margin of the wound.

Dr. Walker very truly remarks that any one who looks at the tumour and the surrounding skin can see that it was thoroughly extirpated. The return of the growth must therefore be due either to a separate tumour having formed in the neighbourhood, or to a kind of grafting process having accidentally taken place at the time of the last operation. *December 20th*, 1870.

Dr. Jno. Swift Walker's report of the subsequent history of his case of spindle-celled sarcoma of the leg.—"The former history of the case of sarcomatous tumour of the leg brought us up to December 14th, 1870, when the tumour had returned again for the fifth time. At this period the condition of the patient was as follows:—Health very much deteriorated, pulse very small, 100 per minute, losing flesh fast. The tumour resembles a large black organised clot of blood, about the size of a large egg, bleeding on the slightest abrasion very profusely, and situated externally to the former wounds, on the upper third of the tibia.

14th.—Without administering chloroform I tied the femoral artery in Scarpa's triangle, with a carbolised hemp ligature, and cut the ends short close to the knee (Lister's method), sponging out the wound with carbolic acid lotion (one part to eight), and closing it by four interrupted sutures.

The tumour being congealed with the æther spray, was removed for the fifth time. The wound was sponged with solution of chloride of zinc (30 grs. to ℥j).

16th.—The wound over the site of the tumour appeared healthy. I scraped off some cuticle, and applied it to the granulations in five places.

29th.—Patient progressing favorably; only one piece of transplanted skin growing; a small distinct island, with radiating branches. I therefore applied more cuticle, scraped off the thigh, in three places.

Digitized by Google

January 1st, 1871.—Patient progressing satisfactorily.

4th, 12 p.m.—I was sent for suddenly, as the patient, during a fit of coughing, had caused serious hæmorrhage from the wound in the thigh. A neighbouring medical man had supplied her with some Tr. Ferri Sesq., which was poured into the wound, and a pocket-handkerchief was twisted round the thigh. On my arrival all hæmorrhage had ceased, but I applied a tourniquet as a precautionary measure.

7th.—The wound very much inflamed from the Tr. Ferri, Carbolic acid, &c. Applied water dressing; and zinc lotion (gr. j to ʒij) to wound in the leg.

13th.—All trace of the island of transported cuticle lost, but both wounds looking healthy and granulating fast.

The wounds were now touched daily with Argent. Nit. and Ungt. Zinci applied.

February 20th.—The patient was sent home, with both wounds quite healed.

Now, this case has many points of interest:—

1st. As regards the ligature of the femoral artery—which is the best mode of leaving the ends of the ligature; to cut it off short, or to leave it long as in the old-fashioned way? My opinion is to cut it off, but it has this disadvantage, no ligature was ever seen. It may possibly have separated on January 4th—twenty-one days after it was applied. The advantage is great in being able to thoroughly close the wound.

2nd. The transplantation of cuticle. Why was not a piece of skin used? Solely because I wanted to test whether scraped pieces of cuticle were sufficient, and only one out of eight trials succeeded, and that disintegrated after becoming organised.

3rd. Did the ligature of the femoral artery facilitate the cure of the tumour? I think not. I think the cure was due to the repeated excision.

The case presents great pathological interest, and has been a source of anxiety to surgeon and patient, but happily has terminated in success.

Very few people would have submitted to so many operations."

March 7th, 1871.

Report by the Committee on Morbid Growths upon Mr. Spencer Watson's specimen of recurrent sarcoma of the leg.—A section

Digitized by Google

of the tumour, which had been preserved in spirit, presented two somewhat dissimilar portions, the basal and central portion having a fleshy appearance, and being of a pale buff colour, passing into red, the upper and circumferential parts were deeply blood stained, and cut with a much firmer grain than the lighter portions; the surface of the section had a waxy look. This difference in the two portions of the tumour was due to the much greater amount of coagulated blood present in the upper and more superficial portions.

Sections of the tumour examined under a low power of the microscope had the appearance of being made up of fibrous bands, which had a granular appearance. When examined with a higher power, the bands were found to be made up of spindle-shaped cells, arranged in regular bands or fasciculi, which varied considerably in size, but were very uniform in shape; the larger measured from $\frac{1}{350}$ to $\frac{1}{400}$ of an inch in length, without their filamentous prolongations, and contained a single large nucleus, the rest of their contents being dimly granular. No definite stroma was observed in any of the sections examined, though fine reticulated fibres were visible in many places. In addition to the above-described spindle cells, numerous small, rounded, and irregularly oval nuclei were present, the larger measuring about $\frac{1}{2000}$ of an inch; these nuclei also contained granules.

In the upper, harder, and darker portions of the tumour the same structures were present, but their microscopic characters were not so well defined, owing to the large quantity of blood which had infiltrated the tissues; blood in considerable quantity being extravasated, both between and into the fasciculi of spindle-shaped cells.

Through the kindness of Mr. Watson I was enabled to examine a portion of a tumour which had been removed at a former operation from the same patient and from the same site. The tumour presented essentially the same structure as the above, but contained a larger quantity of fibrous tissue; this difference may have been due to the sections examined having been made through the base of the tumour where it was in closest connection with the subcutaneous tissues.

W. S. CHURCH.

May 16*th*, 1871.

Digitized by Google

8. *Scirrhus beginning in lower lip and extending to jaw.*

By J. W. Hulke.

A brewer, æt. 42, a bronzed hale-looking countryman, was admitted into the Middlesex Hospital, July 18, 1870, with a hard tuberous tumour attached to the outer surface of the right half of the body of the lower jaw, from near the symphysis to the angle. The line of teeth and the inner surface of the jaw were not distorted. Below the angle of the jaw was a hard movable knot of the size of a bullet. The cheek, which was greatly distended, ultimately adhered to the summit of the swelling. The mucous membrane was mobile.

He said that he had had, in the preceding November, a small tumour removed from the lower lip, in the Kent and Canterbury Hospital, by Mr. Hutchins, who has kindly supplied the following particulars:—"Has a growth from the mucous surface of part of the right half of the lower lip, not involving the skin, as large as a hazel-nut; hard and well-defined; not ulcerated. No enlarged glands in the neighbourhood. Removed by a V incision. Wound healed well. Had had the affection twelve months. The commencement was a small ulcer of the lip. Had a habit of holding a copper nail in the right corner of his mouth.

"On section the growth appeared hard, rather glistening, and smooth, not unlike scirrhus. Microscopically, many ovoid and irregular nucleated cells, with fibres, and a *few* epithelial-like cells; the microscopical characters certainly not like those of ordinary epithelioma."

The absence of ulceration, and the limited attachment of the skin, and the manner in which the morbid growth had spread itself from the primary cicatrix along the outer surface of the jaw, rather inclined me towards the diagnosis of a recurrent fibrous tumour, although the fixation of the cheek in itself pointed to an infiltrating growth, and the enlargement of the lymphatic gland raised the suspicion of carcinoma. The commencement of the primary tumour on the mucous membrane and not on the cuticular edge of the lip made epithelioma improbable. The portion of the jaw on

Digitized by Google

which the tumour was seated, together with the adherent skin and the gland, were removed, and the man made a very quick recovery; but three months later he returned to the hospital with a very large, nodulated, hard tumour, apparently springing from the neighbourhood of the first scar, and also from the ascending ramus of the jaw, reaching backwards to the fauces, and downwards into the neck, and accompanied with enlarged lymphatic glands. No further surgical interference was warranted, and he returned home.

The secondary tumour on section was found inseparable from the periosteum, and at one point had invaded the bone reaching the nerve-canal. It consisted of two tissues, one fibrillated, resembling common connective tissue, but containing very numerous fusiform corpuscles, forming a frame the meshes of which enclosed cylindroid and bud-like masses of large, clear, oval, and roundly oval cells, mono- and poly-nucleated, without any, or with an exceedingly small quantity of a homogeneous intercellular substance. In this growth were observable numerous striped muscular fibres but little altered, and others from which the contractile substance had disappeared, leaving empty sheaths. *January 3rd*, 1871.

---

9. *Case of cystic sarcoma of lower jaw.*

By W. W. Wagstaffe.

The specimen was removed by operation, together with the greater part of the lower jaw, by Mr. Le Gros Clark, from a woman, E. V—, æt. 48.

The history of the case, taken from the notes of Mr. Churchill, the surgical registrar, is, that about twenty years ago a growth commenced upon the gum, accompanied by persistent neuralgia; for this neuralgia the teeth were removed one by one, and strong local irritants applied, but without any relief. Between five and six years ago she first noticed a swelling of the bone at the angle of the

Digitized by Google

jaw, and this was accompanied by severe throbbing pain, especially marked at night.

In consequence of the increase in size of the growth she came into St. Thomas's Hospital, under the care of Mr. Le Gros Clark, June 7th, 1869; and the notes taken at that time state that "apparently the epulis and the subjacent bone growth are separated by an area of healthy bone." The epulis was then about the size of a walnut, and the tumour of bone projected from the angle of the jaw about the size of a marble.

On June 9th the bone tumour was incised, a single cyst found about the size of the top of one's finger, the bone being consolidated around. This was plugged, and allowed to suppurate. The epulis was removed separately, June 17th, without interfering with the bone.

After these operations she appears to have had relief from pain for twelve months, and a cessation in the growth of the tumour for the same time. During the last six months, however, it has increased more rapidly, especially on the inner side of the angle of the jaw, where it presses against the root of the tongue. She was readmitted December 7th, under the care of Mr. Le Gros Clark; and the condition of the growth at that time was as follows:—"The tumour expands both inner and outer tables of the lower jaw, and is about the size of a small orange. It is situated just in front of the left angle, and projects more below and inwards towards the tongue. At the point where the small cyst was opened up, in June, 1868, the tumour is depressed and elastic, elsewhere it is hard and unyielding. The molars and præmolars are absent from both lower and upper jaw on this side.

On the 14th Mr. Clark removed the tumour by a longitudinal incision through the skin, from the angle to the symphysis. The extent of the disease was not discernible until the outer shell of the growth had been removed by a longitudinal section. It was then found necessary to remove the greater part of the ascending and horizontal rami of the jaw on this side. About one inch of the horizontal ramus from the symphysis was left and the coronoid process and condyle, together with the ascending ramus, about half an inch below the sigmoid notch, was also left. The diagram shows the lines of sections. Woodcut 20. The mucous membrane of the mouth was not interfered with until the close of the operation, when the external wound was closed with sutures.

Digitized by Google

From the time of the operation she has gradually recovered, without any evidence of return of the growth in the remaining portion of bone. The maximum temperature of reaction has been 101·5° in twenty hours after the operation.

There was not any glandular enlargement detected, and there was no history of the occurrence of tumours, or of cancer or struma in the family.

The naked-eye appearance of the tumour was that of a fibro-cystic growth in the bone. Externally was a thin bony shell, immediately

WOODCUT 20.

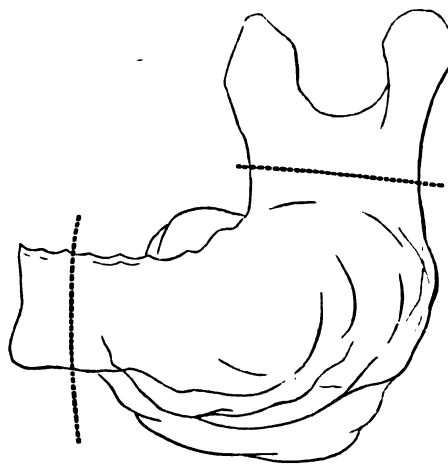

The dotted lines mark the lines of section of the bone in removal of the tumours.

covering in a large number of cysts, of which some were as large as a good-sized marble, some only small as a pea, or smaller. More deeply placed was a firm solid growth of opaque white colour, and it could be seen, on examining it with care, that it was full of minute transparent cysts of unequal sizes. This solid growth was connected chiefly with the bone towards the lower margin of the original jaw. The greater part of the horizontal and ascending rami had been removed, and were distended by the growth, so as to constitute a tumour about equal in size to a hen's egg.

Digitized by Google

When examined microscopically it was found that the growth was composed of innumerable cysts and a solid matrix, through which a certain amount of bone was scattered; that the cysts were lined by a layer of large globular epithelium (Plate V, Fig. 3); that into the interior of the larger cysts other smaller cysts projected, and that these endogenous cysts took their origin in the epithelial lining and not in the matrix of the growth. Other cysts were also freely scattered throughout the structure, but the endogenous formations were so marked that they could be discovered as little balls by the naked eye, and removed for examination by the point of a needle. Some of these endogenous growths *in situ* can be seen in the stained specimen, and one is represented in the accompanying sketch (Plate V, Fig. 1).

The solid structure consisted of a very peculiar arrangement of what appeared to be acini or cylinders of closely packed cells, supported by a fibro-nucleated matrix (Fig. 2). These acini or rods in many places gave the appearance of tubes from the arrangement of their component cells, which resembled very curiously that of columnar epithelium, or of the epithelium of gland follicles. The cut ends, however, showed no central canal. The constituents of these rods were nuclei imbedded in plastic matter, and these separated by manipulation into small tailed or so-called spindle cells of similar size and character to the corpuscles of an ordinary sarcoma. The relative size of these corpuscles, the globular epithelium, and blood corpuscles is shown in the accompanying sketch (Plate V, Fig. 3).

There were seen in the juice, when fresh, very evident columnar epithelial cells, and from the peculiar arrangement of the surface cells of the majority of the rods, it may be surmised that they came from those points.

A peculiarity in some parts of the growth was the very equal size of these cylinders and their tortuous character. This, with the epithelium-like cells, made the resemblance to glandular structure very marked in some of the sections, and one of these I have represented (Plate V, Fig. 2).

The bony element of the solid part was apparently the remains of the original cancellous structure expanded as plates, and occasional processes between the cysts. *January 17th*, 1871.

Report by the Committee on Morbid Growths upon Mr. Wagstaffe's tumour of jaw.—We have carefully examined the preparations

Digitized by Google

Digitized by Google

DESCRIPTION OF PLATE V.

(*From drawings by* W. W. WAGSTAFFE.)

Figs. 1, 2, and 3 illustrate Mr. Wagstaffe's case of Tumour of the Lower Jaw (page 249).

Fig. 1 represents an endogenous cyst growth. ($\frac{4}{10}$ object-glass.)

Fig. 2 represents arrangement of rods or acini of closely packed cells in a fibro-nucleated stroma. ($\frac{4}{10}$ object-glass.)

Fig. 3 represents cystic, firm growth, opaque white, the solid part giving a very scanty, rather milky juice on scraping, distending bone. ($\frac{1}{6}$ object-glass.)

A. Blood.
B. Epithelium lining cysts.
C. Columnar epithelium (from acini).
D. E. Nucleated cells, &c. (from acini).

Figs. 4 and 5 illustrate Mr. Wagstaffe's case of Fibrous Tumour of Heart (page 121).

Fig. 4 represents the actual size of the tumour (reduced to about two thirds).

Fig. 5 represents microscopic structure. ($\frac{1}{6}$ object-glass.)

(The figures are all reduced to about two thirds.)

Digitized by Google

1

3

2

4

5

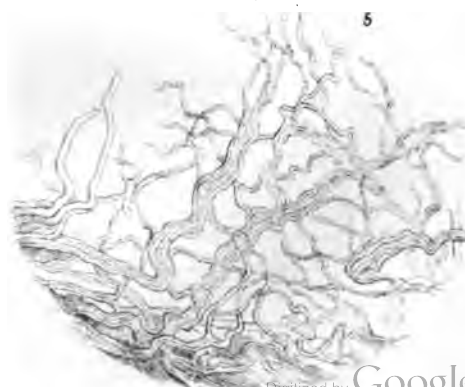

Digitized by Google

Digitized by Google

of the tumour submitted to us by Mr. Wagstaffe, and find that the appearances presented by them fully bear out his description of the minute structure of the tumour. SEPTIMUS W. SIBLEY.

April 2nd, 1871. J. W. HULKE.

---

10. *Exostosis.*

By T. HOLMES, for Dr. MARTYN.

DR. MARTYN exhibited a photograph showing the appearance of one of the hands in an extraordinary case of exostosis notable for engrossing both hands and feet, as well as for the great size of the morbid growths with the following history.

The patient is 28 years old, and in general good health; he is little more than four feet in stature, the dwarfing being caused by the shortness of his legs, the trunk being well formed; the forearms are shortened also, but the wrists are large and strong.

In three years that he has been under my observation there has scarcely been any increase in the tumours.

His mother has a diffused fatty tumour under the skin of the back of the neck, which gives her very little inconvenience. With this exception she knows of no predisposition in his or her parents to such tumours.

He was born perfect in shape and sound in constitution, and continued so until he was eighteen months old; then first was observed to enlarge the first phalanx of the left middle finger, then the second; after an interval the phalanges first and second of the other fingers assumed the same morbid growth. Then the first and second phalanges of the fingers of the other or right hand began to enlarge, then after awhile those of the feet. The growth was steady and progressive until the present time, giving him great inconvenience and little pain, the centres of the bones early becoming globular.

The left hand that is shown is the largest; the right one is very

Digitized by Google

little less, but it is partly excoriated, and is covered. The feet are much less enlarged, which enables the poor fellow to walk a few steps, and get out in the sunshine. The hands are so bulky and heavy that he is obliged to support them on his lap or on a belt slung round his shoulders. Besides the incumbrance and pain they disable him totally from doing any one act to help himself. He is fortunately blessed with a patient and even cheerful disposition which greatly alleviates his deplorable state.

The girth of the bunch of tumours gently pressed together is 31 inches.

The circumference of the	1st	phalanx	of fore finger	is	18	inches.
"	2nd	"	middle	"	13	"
"	1st	"	ring	"	9	"
"	1st	"	little	"	14½	"

The third phalanges are little enlarged, and seem sunken in the mass.

The thumbs are little enlarged and deformed, but preserve their cylindrical shape.

The fissures between the phalanges which make the tumours are 1½ inch deep. I doubt that they are ankylosed.

The hand lifted from the elbow resting on a table weighs 10 lbs.

The greatest length of one finger is 8 inches.

The surface is studded with a few varicose nodules projecting.

The tumours feel hard, smooth, and inelastic, and from the tact, percussion, and weight I conclude them to be cellular exostosis; that is, bone expanded to a shell containing interlacement of bone and cartilage, and filled with oily albuminous deposit, such as occupied the heads of the large bones.

He was told the only remedy for him was amputation of the hands, leaving the thumbs, which might be of use. But this he would not submit to.

In 'John Bell's Surgery,' 1814, are figured such cases as these; one of a boy of six years, the phalanges of whose left hand appear as tapering bulbs, such as this case may be supposed to have been at that age.

The man is since dead during my absence, and unfortunately no *post-mortem* examination was made, nor were the parts procured.

Digitized by Google

The cause of death as far as I could ascertain was gangrene of the right hand.

The photograph was taken in July, 1870. I am told—for I had left the place— that the patient died on the 1st November following, after seven weeks' suffering and exhaustion of gangrene from the right hand, of which the excoriation named must have been the beginning. No *post-mortem* examination was made, but the nature of the tumours when exposed by ulceration is described to me as confirming the diagnosis made, for it showed cells and holes which discharged much putrid flesh and extremely fœtid matter, and blood that kept continually oozing. When dressed these cavities in the hand would hold a great deal of water. *January*, 1871.

---

11. *Tumour of the upper jaw.*

By J. F. West (introduced by the President).

The rapidly growing cancerous tumour of the upper jaw and cheek, which I brought before the Pathological Society of London, was removed by me from Mr. R—, a young man, by trade a saddler, æt. 23, on January 16th, 1871.

The tumour appeared to spring from the front of the right superior maxilla, which it expanded in every direction, the orbital plate being pushed upwards so as to protrude the eyeball, the palate process downwards, the outer wall and alveolar process forwards, so that the cheek bulged out to a great extent. The submaxillary glands on that side were slightly enlarged.

He stated that he had always enjoyed good health, that he came of a healthy stock, that both his parents were alive and hearty, and that the only thing from which he had suffered was some enlarged glands in the neck, which, however, had always diminished or disappeared under the use of iodine ointment. The present tumour

Digitized by Google

had been forming for about three months, and he could assign no cause for it.

The patient bore the operation very well and lost very little blood; no febrile excitement followed the operation. The wound looked well for several days, and on the 18th some of the sutures were removed. On the 21st he began to sink from prostration, and he died on the evening of that day. No *post-mortem* examination was allowed. *February* 21*st*, 1871.

Report by the Committee on Morbid Growths upon Mr. West's case of tumour of the upper jaw.—The greater portion of the tumour is composed of cells closely packed together. The cells are large and very irregular in form; they mostly contain a single large nucleus, and the nuclei contain several granules.

Microscopic sections show that the cell-growth has been infiltrated among the various surrounding tissues. Bands of fibrous structure are seen running in various directions, and in some places the cell-formation separates bundles of muscular fibre. The muscular fibre is in a more or less advanced stage of degeneration.

The minute characters of the tumour, therefore, correspond to those of malignant disease. J. W. Hulke.

May 10*th*, 1871. Septimus W. Sibley.

---

12. *Epulis tumours of the jaw.*

By Henry Arnott.

The specimen was removed from a married lady, æt. 40. Her general health was good, but she suffered slightly from indigestion. She was the mother of one healthy child. There was no history of any morbid growths in the family. She came under Mr. De Morgan's care in the summer of last year, having a large epulis tumour occupying a space in the left side of the lower jaw from the

Digitized by Google

second bicuspid to the second molar inclusive. This was a simple, hard, gum-like growth, involving the edges of the gum, and extending but a short way on the alveolar edge. The stumps of two of the teeth were seen at the bottom of it. There was no pain, but it was growing rapidly. She came to town in November, 1870, and had it removed; but before the operation she pointed out a small swelling nearly at the reflexion of the labial mucous membrane on to the gum and below the line of the first bicuspid. It was not larger than half a very small pea, was soft, and lay under the membrane. She had only noticed it a few days before she came up for operation.

The epulis was removed, and was found to be connected with disease at the roots of the first and second molar, which were inflamed, large, and rough, from deposit of new cementum. The parts soon healed, and she returned to the country. Early in January, 1871, she again came to town in consequence of the rapid growth of the last-formed tumour. It was now the size of half a large nut, elastic, and painless; and another small nodule, very similar to what it had been when first seen, had developed above it. The inner side of the ramus also presented towards its base three nodules of hard, dense outgrowth, like epulis in feel, not elastic. The alveolar border remained as it was after the operation.

Mr. De Morgan now removed the lower jaw, from the level of the canine to the angle. She made a rapid recovery.[1]

In points of microscopic structure both tumours were alike, both consisting chiefly of rapidly growing fibrous tissue, rich in plump oval nuclei, imbedded in which were scattered spicules of bone, some apparently fragments of old bone separated by the new growth, but others clearly of new formation, the lacunæ being rudimentary, almost destitute of canaliculi, and containing oval nuclei deeply staining with carmine. Tracts of more mature fibrous tissue studded with slender oat-shaped nuclei passed through the softer tissue, dividing it into lobules. A few myeloid cells were present in both tumours, but (in the sections examined) these were much more plentiful in the smaller softer growths, in some parts of which they gave quite a characteristic appearance to the section.

In the larger more diffused growth the surface seemed to be covered in some places with a new mucous membrane, with large

[1] Four months after the operation there was no appearance of return.

Digitized by Google

crowded papillæ, and a thick layer of epithelium; and sections carried through this thick layer in various directions presented very peculiar and striking appearances. *February* 21*st*, 1871.

---

13. *Fatty masses contained in a ranula.*

By Waren Tay.

The specimen consists of four out of five masses removed from a ranula under the tongue.

The patient was a man, æt. 55, who came under my care as an out-patient at the London Hospital, January 23rd, 1871. The swelling was somewhat oval in shape, about the size of a goose's egg, and pushed the tongue upwards and backwards, so that it could not be seen at all without the man opened his mouth very wide; the tumour also projected beneath the jaw. Distinct fluctuation could be felt in the tumour; but also in the centre there was a firm, rounded mass, which I considered to be a salivary concretion. The patient said that he had had some swelling under his tongue for a number of years. I had seen him three years before when the swelling was still small, and had recommended treatment; but he would not then consent. It had increased much since then and had become so inconvenient to him that he was anxious to get rid of it. I cut out a large piece from the front wall and let out some glairy fluid. On proceeding to remove the hard body which I had previously felt, I turned out, to my astonishment, five lumps much resembling small pats of firm butter. They were packed closely together and moulded to one another, but were quite distinct from each other. They varied in size from that of a hazel-nut to that of a walnut; were of a pale yellow colour, of firm consistency but easily impressed by the finger, and apparently uniform in structure on section. The outer surface was pitted in various parts, giving them an appearance not unlike that of a potato. Under the microscope no definite structure could be detected in them, either in the centre or at the

Digitized by Google

periphery. I failed to obtain cholestearine plates or evidences of ordinary fatty degeneration. Entangled in the substance composing the masses were some cells and portions of cells looking like débris of epithelium, but there were no epithelial cells studded with oil globules as one would expect to find in fatty degeneration.

Dr. C. Meymott Tidy kindly examined one of them chemically, and reports:

"Weighed thirty-four grains; under the microscope has the appearance very much of soap; scales of epithelium also to be seen. When exposed to air for some time the mass assumes a yellow colour. I examined it for sulphocyanides but with negative results.

"The chemical composition is as follows:

"*In* 100 *parts*—

Moisture	26·00
Fatty matter soluble in ether	66·5
Inorganic matter, principally lime salts	2·1
Residue—epithelium, &c., and loss	5·4
	100·0

"From its microscopic appearance and chemical analysis, I am very much disposed to regard the bulk of the deposit as adipocere."

That these bodies are chiefly composed of fat there can be no doubt, and it is a very unusual occurrence to meet with such changes in tumours under the tongue, but whether the substance is really adipocere or not is open to question. I cannot find that adipocere has been hitherto met with in the living body. I should mention that numerous groups of acicular crystals, in all probability of margarine, became manifest in a microscopic specimen kept a little while in glycerine.

The patient has continued under observation and the cyst has contracted. The opening has not yet closed.

February 21*st*, 1871.

Digitized by Google

14. *Facts as to the general diffusion of cancer.*

By Weeden Cooke.

Case 1.—*Medullary sarcoma of the cranial bones associated with scirrhus of the breast; no operation; in an old person.*

Phœbe Pemberton, æt. 63, admitted into the Cancer Hospital, January 7th, 1869, having scirrhus of the left breast, with an open wound on the outer side. The disease began five years before as a small tumour. There is no history of cancer in the family, but both parents and some aunts had died of phthisis. Is married, but had no children; cannot attribute it to any local injury. Had previously the advantage of being an out-patient at Guy's Hospital. During her stay she had a severe attack of bronchitis, and some sloughing of the wound ensued.

After a time her health improved, and the wound under antiseptic treatment filled up to some extent. On the 30th of March of the same year she went home much relieved.

She was not seen again until September 29th, 1870, eighteen months after, when she was readmitted. A recent inflammatory attack had resulted in sloughing of the breast, and there was some œdema of the arm. The point of pathological consequence, however, was that now was observed for the first time a hard, nodulated swelling on the right side of the head, occupying a portion of the frontal and temporal space. The eye on the same side was slightly prominent and the sight deficient. There was some pain in the head, but no deficiency of speech or symptom of paralysis. Opium applied externally relieved the pain. She improved in general health for a time and the breast remained in a quiescent condition; but as the weather got colder she got weaker, and she died quietly without any convulsive action, on the 12th November, 1870.

The results of the autopsy are as follows:

The cancer in the breast had made no progress; it was slightly adherent to the pectoral muscle, but there were no infiltrations of

Digitized by Google

the neighbouring glands. The calvarium which is exhibited shows a deposit of soft lobulated medullary substance on its external table lying between it and the tendinous aponeurosis of the occipito-frontalis muscle, covering the junction of the right parietal and frontal bones and a portion of the temporal to the extent of some three inches by two inches. On the inner side of the calvarium there is likewise a soft medullary growth which has penetrated the dura mater, and is somewhat larger than that on the external table. Its mechanical pressure had caused absorption of the membranes and a portion of the gray substance of the brain, the white matter appearing as though a clean slice had been made to the extent of a square inch. In a case somewhat similar examined by the late Dr. Knox, which is preserved in the museum of the Cancer Hospital, there was an opening through the bone affording a communication between the internal and external disease, and this opening was so small that it would scarcely admit the passage of a pin. I have abstained from making a minute dissection of this specimen in order that the Society may see it intact; but it will be interesting now carefully to see if there be any visible communication between the external and internal tables of the skull.

CASE 2.—*Case of scirrhus of the brain with aphasia associated with scirrhus of the breast; breast removed by operation; in a young woman.*

REBECCA IBBETSON, æt. 32, unmarried, admitted to the Cancer Hospital, May 18th, 1870, having a moveable tumour in the left breast as large as an orange. There was also an enlarged gland in the axilla. The tumour was first observed six months before, and had increased rapidly recently owing to a bad cold. Had no injury to complain of. I removed the breast on the 23rd May, and she was discharged quite well on the 9th of July, the healing having been accomplished partly by granulation. The axillary enlargement entirely disappeared. The tumour exhibited the usual irregular-shaped nucleate cells. There were no head symptoms whilst in hospital. On the 3rd of December of the same year, I received a letter from Dr. Alex. Reid, of Wokingham, in Berkshire, telling me that this patient had died under his care on the previous day, and giving the following particulars of the symptoms and post-mortem appearances:

Digitized by Google

"Slight paralysis appeared on the right side, in the month of August, but passed off, leaving her with violent headache and some defect of speech. This latter symptom increased and the hemiplegia of the right side returned as the case went on." Dr. Reid thus describes the post-mortem: "The head only was examined, when two deposits were found embedded in the substance of the left hemisphere of the cerebrum. The deposits were hard, quite characteristic of scirrhus, and each about the size of a pigeon's egg. Over the surface of each tumour the membranes of the brain were adherent, but there was no special adhesion of the dura mater to the bone. It was interesting to note the site of the anterior deposit, viz. in the third left frontal convolution, in connection with the aphasia observed in the later stage of the case which was complete." He also says that there was no hardness in the cicatrix of the breast or glands of the axilla, nor any symptom to indicate return of the disease in that region. These cerebral tumours are in the Museum of the Pathological Society of Reading. *March* 7th, 1871.

---

15. *Cystic epithelioma of the cheek.*

By Spencer Watson.

A woman, æt. 60, applied to the Central London Ophthalmic Hospital in May, 1870, for advice in respect of a growth over the upper part of the cheek immediately below the outer canthus of the left eye. It was of a flattened oval form, of the size of a sixpence, with a semitransparent, lobulated, smooth, shining surface, and a minute ulcer near the centre, which was covered by a dry scab. It was raised about one eighth of an inch above the surrounding skin, which was free from vascularity or discoloration.

The deep surface of this growth was quite free and moveable over the subjacent tissues. The lymphatic glands in the neighbourhood were free from any disease, and the general health good.

Digitized by Google

On May 19th the tumour was removed with a small margin of the surrounding skin, and the wound made by the operation healed rapidly, leaving scarcely any noticeable scar. In July last there was no sign of any return of the growth.

On making a vertical section through the growth a number of cells containing fluid were found, and lying loose in one or two of the larger cells, oval, yellowish bodies of the size of rice grains, which, when closely examined, were seen to have a disc shape, with their edges rolled inwards, somewhat in the manner of dried leaves. The bulk of the growth consisted of lobulated epithelioma, with numerous cells or cysts filled with a clear fluid. The loose bodies were probably formed by the detachment of involuted lobules of masses of epithelium, the neck of the lobule being gradually attenuated and ultimately completely separated by the pressure of surrounding masses of growing cells. *March* 21*st*, 1871.

Report by the Committee on Morbid Growths upon Mr. Spencer Watson's specimen of epithelioma from the face.—I agree with Mr. Spencer Watson in regarding the growth as epithelioma, although it presents some rather unusual characters, having in some portions a number of cyst-like spaces, which in the recent state are reported to have contained fluid, but which had altogether lost their fluid contents after immersion in chromic acid.

In sections taken from all parts of the growth cell-proliferation had taken place to a very great extent; and in most of the sections examined laminated corpuscles were found, but they were not very numerous in any part of the specimen. The greatest amount of cell-growth had taken place in and around the hair-follicles, and in only a few cases could I recognise any remains of either sebaceous or sudoriparous glands. The papillæ of some of the hairs were much hypertrophied, and out of all proportion to the hair attached to them.

With regard to the cysts or alveoli, which were very numerous in some parts, I am a little in doubt whether they were alveoli occurring in the middle of masses of epithelial cells, and had their origin in the softening and breaking down of a portion of the cell-elements, or whether they originated in connection with the follicles of sebaceous glands. The walls of some of them contained and appeared to be mainly made up of fibrous tissue, while in other cases the walls were formed by densely packed and flattened epithelial

Digitized by Google

scales. The contents of the cysts were solid and could be shelled out of them with the greatest ease, so that it was difficult to make a section of both the cyst and its contents. The contents consisted of a structureless, waxy looking mass, very granular, and thickly studded with nuclear-like bodies.

On maceration in liquor potassæ it was evident that much of this material was formed by shrivelled and densely packed epithelial cells. One of the small oval bodies exhibited by Mr. Watson, which had been removed from the cysts whilst fresh, was examined. It consisted of a thin layer of granular matter, which had assumed the oval, grain of rice like, shape from the escape of its contents and the rolling inwards of its edges. It corresponded to the solid contents of the cysts in the hardened specimens, which in not a few instances had hollow spaces still remaining in their centres.

A somewhat similar variety of epithelioma has been described and figured by Thiersch,[1] tab. iv, p. 112, and was met with by him on the forehead; in his case the growth was of much larger size and had penetrated the deeper tissues.

May 16*th*, 1871. W. S. Church.

---

16. *Soft cancer of the female breast.*

By Henry Arnott.

A married woman, æt. 30, plump and healthy looking, with fair complexion, came under my care as an out-patient at the Middlesex Hospital early in the present year, with a large tumour of the left breast. She ascribed the complaint to a blow received two years and a half previously, but she had first noticed it ten months ago as a small lump, the size of a walnut, lying to the inner side of

[1] 'Der Epithelial Krebs, namentlich der Haut.' Von Dr. Karl Thiersch Leipzig, 1865.

Digitized by Google

the nipple. This rapidly increased in size, with little pain or inconvenience, and by Christmas, 1870, the nipple was being notably retracted, and she also observed a "kernel in the armpit." The general health, however, continued unimpaired, and the only pain complained of was an occasional "stab" in the breast. She was subsequently admitted under Mr. Nunn's care, on March 21st, 1871, and at the time of her admission, the whole of the left breast was greatly enlarged and very heavy, as though wholly converted into a tumour. The swelling was tense, firm, and somewhat elastic; almost fluctuating indeed at its most prominent part, where the skin, everywhere tightly stretched and œdematous, was purple over an area of two square inches. The brawny skin could nowhere be pinched up from the mass. The nipple was sunken somewhat irregularly, and not to a great extent, and no enlarged veins ramified over the swelling. The breast seemed fairly movable over the subjacent parts. A gland enlarged to the size of a walnut and slightly tender was felt in the anterior part of the axilla.

On March 22nd Mr. Nunn removed the whole of the breast by an oblique incision, which included the nipple and a good deal of skin on either side. The axillary gland was left; but a little suspicious adhesion of the breast to the pectoral muscle being discovered, a portion of that muscle was removed, as well as some thickened fascia underlying the breast.

On a section being made through the lobulated tumour, it was found that, excepting where a large blood extravasation had formed an irregular cyst in the centre, filled with creamy and dirty chocolate coloured dèbris and limited by indurated tissue, which formed a cyst-wall, the structure of the tumour was everywhere nearly the same. Of a yellow-white colour, save where blotched with blood extravasations of various dates and appearances, and of fleshy consistence, the cut surface seemed to be mapped out into irregular loculi by a fibrous meshwork pervading it; these loculi varying from less than a pin-head in size to nearly that of a split pea, and all being evenly filled with thick, semi-fluid, opaque matter. Here and there an appearance as of a spherical cyst filled with solid contents, suggested the idea of a cystic tumour, with intra-cystic growths filling and expanding the cysts; but this appearance was nowhere very distinct, nor were there any definite cysts filled with clear fluid.

A thick, creamy fluid could be scraped from the surface of the section, and this, examined under the microscope, was found to be

Digitized by Google

loaded with irregular (but generally round or oval) cells of very various size, and containing one or two large oval nuclei and bright nucleoli, and many cells and free nuclei in an advanced stage of fatty degeneration. None of the healthy breast tissue could be recognised. The skin was thickened, but chiefly with œdema. There was, however, a considerable overgrowth of epithelium in the neighbourhood of the nipple, which was slightly drawn in, but not obviously implicated in the diseased growth.

Microscopically, the following structure (Plate III, Fig. 4) was observed in sections made from bits of various parts of the growth hardened in chromic acid solution. The greater part of each section was made up of cells, round or roundly oval, and very generally spoiled by fatty change. These cells were mostly large—four or five times the size of a white blood-corpuscle—and contained one large, oval nucleus —rarely two—with one or two bright nucleoli. There was here and there some scanty granular intercellular material, but this seemed to result from the disintegration of decayed cells. Branching amongst the cells and forming loculi of varying shapes and sizes, was a well defined stroma of fibroid material, staining deeply and uniformly with carmine, and sometimes forming broad belts, as if by blending together of many fine bands which enclosed narrow slit-like apertures (see drawing). In some parts of the edge of the growth a different structure of much smaller cells, but arranged in a similar manner, was seen, but nowhere were distinct remains of breast tissue discernible. The tumour is therefore clearly of carcinomatous nature, and only differs from ordinary scirrhus of the breast in that the cell element predominates over the fibroid stroma; and it is interesting as an example of what is usually styled "firm medullary cancer."

April 18*th*, 1871.

Digitized by Google

17. *A large cystic tumour of the breast in connection with a scirrhous carcinoma, which has undergone calcareous degeneration.*

By THOMAS SMITH.

THIS specimen was removed by myself about five weeks since from a person, æt. 65, unmarried, and of cancerous inheritance. Her mother died of cancer at the age of 84. Her only sister has had two operations performed for cancer of the breast; and she has two cousins on her mother's side, one of whom, a male, died at the age of forty from cancer, the other, a female, is now suffering from the same disease.

Seven years ago this patient noticed a swelling in the upper part of the right breast, which slowly increased in size; three years since she consulted Mr. Paget on account of this tumour. He considered it to be cancer, and, from what he heard of her general health, advised against an operation. In the early part of this year this lady consulted me with a cystic tumour of the breast, as large as a full-sized adult head. Towards the upper part of the swelling was a hard lump obscured by the cyst, and said to be in the situation of the original tumour.

The present enlargement has been rapid, and had commenced nearly three years ago. There was no affection of the axillary glands, and the growth moved freely on the chest-wall; it was painless, but very inconvenient from its great weight. On March the 18th I removed the breast, washing out the wound with chloride of zinc, and closing it with a continuous wire suture.

The growth consists mainly of a large unilocular cyst, containing a brownish fluid, and having the gland structure spread over it. In the upper part of the cyst-wall is a scirrhous cancer, measuring about two inches in its transverse diameter; its deep surface was separated from the pectoral muscle by a layer of healthy fat; from the opposite side of the cancer there projects a small soft vascular growth into the cavity of the cyst.

The cancer is throughout extremely hard and bloodless looking; it exhibits under the microscope the ordinary characteristics of

Digitized by Google

scirrhus of the breast, and yields a plentiful juice on scraping or squeezing. The central part of the cancer, and that nearest to the cyst cavity, has undergone calcareous degeneration, and cannot be divided with an ordinary scalpel.

The specimen possesses interest as showing a very rare transformation in the tissue of scirrhous carcinoma, namely, calcification. Whilst tubercle, atheroma, blood-fibrine, false membrane, fibrous and cartilaginous tumours are not indisposed to undergo this change, scirrhous cancer seems, unhappily, almost exempt from this form of degeneration.

From the history of the case we may conclude that the calcification, as was natural, led to an arrest in the development of the cancerous tumour, since it had not visibly increased for some years before the operation.

It may be interesting to speculate whether the rapid and prolific development of the cyst and its contents from the surface of the cancer exercised any influence in checking the development of its solid structure by affording (as it were) an outlet for its malignant energy of reproduction. *April* 18*th*, 1871.

Report by the Committee on Morbid Growths upon Mr. Thomas Smith's case of "Large cystic tumour of the breast in connection with a scirrhous carcinoma, which has undergone calcareous degeneration." — We have examined thin sections taken from the portion of tumour stated by the exhibitor to have been "extremely hard and bloodless," and to have "yielded a plentiful juice on scraping or squeezing." The spirit in which the specimen has been preserved has somewhat obscured its minute structure by rendering the precise form of the cells indistinct, but the general arrangement is sufficiently obvious. Viewed with a low power, the sections are seen to consist for the most part of fibroid tissue, staining uniformly pink with carmine, and studded with slender, waving, elongated nuclei. This substance is broken at certain places by meshes filled with cells, and in many parts this structure bears a strong resemblance to ordinary mammary gland-tissue with such an increased development of the inter-alveolar connective tissues as is common in the so-called "chronic mammary tumour," the meshes being small, of nearly irregular size and shape, and clustered in groups. The cells filling these meshes are, however, of larger size and more irregular contour than the normal glandular epithelium;

Digitized by Google

and in some parts a much more distinctly cancerous structure is evident. In such places the meshes in the fibroid stroma are large and of extremely irregular shape, but generally exhibiting that tendency to slit-like form so usual in mammary cancer; and in some parts dense masses of cells occupying considerable areas interrupt the fibrous tissue. These cells where their characters can be more distinctly made out with higher powers are two or three times the size of ordinary breast epithelium, contain large oval nuclei with bright nucleoli, and in their extremely varied shape and general confused arrangement correspond in all respects to the cell elements met with in a scirrhous cancer.

Without, therefore, venturing to say whether the tumour has been originally of a simple glandular type which has since become cancerous, or whether from its origin it has been an example of extremely chronic non-infecting cancer, we are of opinion that at the time of the removal of the tumour some portions of it at least were microscopically indistinguishable from genuine scirrhous cancer.

HENRY ARNOTT,
WM. CAYLEY.

May 16*th*, 1871.

---

18. *Myxoma.*

By JOHN GAY.

THE specimens exhibited are portions of a recurrent tumour, the third in order of recurrence, taken from the buttock of a remarkably florid, muscular, healthy looking woman, æt. 48, a patient in the Great Northern Hospital.

She was admitted in July, 1869, for a very large and deeply-situated subcutaneous tumour of the right buttock. It had grown rapidly and was giving great inconvenience, and appeared to move with considerable freedom amongst the tissues by which it was enclosed. There were no large veins running over the surface, nor glandular implication.

On removing it, which I did in the same month, I found it imbedded amongst the fibres of the glutæus maximus muscle some-

Digitized by Google

what firmly attached to the tendinous fasciculæ by which that muscle is attached to the femur, but otherwise loose, and surrounded by a delicate capsule. The tumour presented the appearance of a jelly-like, semitranslucent, lobulated mass, with parts which were more opaque and of a somewhat tougher and more fibrous consistence. No fluid could be squeezed from it; and it had all the microscopical appearances of a pure myxoma. The woman made a good recovery.

She returned to the hospital in June, 1870, with a recurrence of the tumour. At this time it was not so large, but it was in the same situation and was in process of rapid growth. The cicatrix of the former operation was nine inches in length, perfectly sound, and, although it crossed the tumour, was not adherent to it. On removal this time it was found to be lying amongst the fibres of the glutæus medius muscle, there being hardly any traces of the glutæus maximus left, but portions of like tissue were found along the tract from the main growth to the sacro ischeatic notch, with the fibrous structures of which, as well as with those of the sacrum, they had apparently become incorporated. Small nodules, lying almost loose amongst these structures, were easily removed by the finger. Some considerable vessels had to be tied. The woman made a good recovery. The tumour was made up of spindle-shaped cells in some parts, whilst in others it had the appearance of a fine network of tubular fibres enclosing in its meshes round and oval nuclei, but without any viscid fluid resembling mucus.

The patient returned to the hospital again in April, 1870. The growth had recurred, but in external appearances it differed materially from those which the previous tumours displayed. It was now a large lobulated mass growing chiefly from the cicatrix tissue which resulted from the former operations, and from the adjoining portions of sound skin as well. One portion projected very considerably above the general level of the parts whilst the remainder dipped down into the iliac cavity, upon the glutæus minimus muscle and crossed towards the sacrum. Its removal involved that also of a large portion of the integument, and a portion of the sacro-ischiatic ligament to which it was adherent. There were nodules of gelatinous-looking matter dipping down through the notch into the pelvis, and others beneath the integuments along the back of the thigh. So far as it was possible to do so these were removed, but it was plain that they could not be entirely eradicated.

Digitized by Google

The large gap made by the operation had almost entirely closed when the woman left the hospital, but a few nodules had by this time made their appearance in the skin-tissue close to the edge of the wound. These were easily enucleated.

This growth differed materially in external appearance from those which preceded it, inasmuch as it had a large quantity of coarse fibroid tissue in its composition—analogous in every respect to ordinary fibro-recurrent or adenoid tissue. In one portion of the tumour there was a cavity to the sides of which a large nodule of the former gelatinous looking tissue was loosely attached; and throughout the structures, in the neighbourhood of the growth, nodules of a similar kind were found. These were, indeed, so infiltrated by the disease as to forbid the slightest hope that this or any future operation would be of the least avail.

The specimen shows very clearly its structure, and also the relation borne by the tumour to the neighbouring tissues in which it lay. The structure seems to be everywhere the same, viz. a very delicate cell-growth, of which the cells are small, oat-shaped, containing a minute oval (or more rarely round) nucleus with bright nucleolus, and showing, especially at the margins of their sections, long fine tails. There seems to be no other cell-form present, and these spindle-cells are regularly banded in broad tracts which move about the growth in various directions, intersecting each other at different angles. So far the structure is seen to correspond in most particulars with that of the growths formerly removed from the same place, and already exhibited to the Society. But this last specimen is especially instructive and valuable since it shows in a very beautiful manner the reason of the recurrence of the tumour after repeated and careful removal. Some of the microscopic sections have been purposely carried for some distance into the fat and muscle enveloping the growth, and these sections prove conclusively its infiltrating properties. Thus, in some places, fibres of healthy looking striped muscle are partly obscured by an invading host of small spindle-cells which separate the fibres from one another and penetrate far from the mass of the growth amongst the muscular tissue, the number of cells diminishing as the infiltration stretches away from the tumour. Precisely the same appearances are presented in the adipose tissue, the cells of which are more or less separated by those of the new growth; at first in thick bands reaching out in all directions, but gradually fewer and fewer spindle-

Digitized by Google

cells are met with until at length the fat seems to be perfectly normal.

I am indebted to Mr. H. Arnott for valuable help in the microscopic examination of these growths, and for the more valuable portion of the foregoing report of their intimate structure.

May 16*th*, 1871.

---

19. *Hard fibrous tumour of the palate.*

By W. Adams.

Miss A—, æt. 40, consulted me on the 18th March, 1870, in consequence of a tumour growing from the hard palate and projecting into the mouth. The tumour was of an irregular form and flattened, measuring from an inch to an inch and a quarter in diameter, and three quarters of an inch in thickness. It was closely applied to the surface of the palate, and at first thought to be immovable, and from its density probably of the nature of exostosis; but after repeated examinations it was found to be slightly movable.

The tumour had existed for six years, increasing slowly, and without pain at any time. The inconveniences arising from it were purely mechanical, but these were sufficient to induce the lady to submit to an operation, which I performed on the 30th May, 1870, with the assistance of Mr. Peter Burchell of Kingsland Road.

By the introduction of a wedge between the palate and the tumour, it was found that the connection was much smaller than could have been anticipated, and by the application of a gouge the tumour was easily detached from the central and posterior parts of the hard palate. The connection was found to be only by means of a short fibrous peduncle, attached to the periosteum of the palate. The wound healed favorably, and up to the present time (August, 1871) there has been no disposition to reproduction.

The tumour was microscopically examined by Mr. Henry Arnott, who has furnished the following report. 16*th May*, 1871.

Digitized by Google

Report by the Committee on Morbid Growths upon the tumour removed from the palate by Mr. W. Adams, 30*th May*, 1870.—Thin sections stained with carmine and mounted in glycerine, after treatment with acetic acid, showed the tumour to be made up of fibrous tissue in various stages of development. The prevailing structure was a tolerably homogeneous or fibrillated basis-substance in which were imbedded elongated, oval, spindle, or rod-shaped nuclei all arranged in tolerably regular bands or tracts which traversed the tumour in different directions. In some parts there was well marked, wavy, fibrous tissue; but as a rule this was not fully developed, and in other places the nuclei were large and numerous, suggesting the earliest stage of rapid growth. In no part were there any "myeloid" cells seen. The papillæ of the mucous surface of the tumour were somewhat hypertrophied, with considerable increase in the epithelium covering them.

December 7th, 1870. HENRY ARNOTT.

Digitized by Google

IX. DISEASES, ETC., OF THE DUCTLESS GLANDS.

(A) SPLEEN.

1. *Case of acute splenitis (?) in a syphilitic.*

By WALTER MOXON, M.D.

IN the following case the spleen was enlarged, and its tissue in a peculiar state. The case is otherwise, I think, worthy of attention, especially from the peculiar features attending the inflammation of the lung and bronchial glands. The specimen was from the body of a woman, æt. 29, who died in Guy's Hospital, having been under the care of Dr. Habershon. She was a married woman, with four children. There was no history of spirit drinking or of syphilis. Her general health had failed nine months before her death, but swelling of the abdomen appeared only a few weeks before admission into the Hospital, when she presented the conditions of ordinary hepatic ascites. After remaining a month in the hospital she gave signs of acute pneumonia, of which she died.

On inspecting the body, which was spare though not much wasted, acute inflammation of the left lung was found. There was lymph upon its pleura, and the subserous tissue showed signs of purulent change evidently within some vessels. On comparison with museum specimens of injected subpleural lymphatics these lines corresponded with the lymphatic network, and like it, followed pretty closely the outlines of the pulmonary lobules. Section of the lung showed uniform red hepatization of the posterior half of the lower lobe, but a curious appearance was produced by the septa between the lobules showing up as yellow lines, being plainly traceable by the pus-injected lymphatics in them, while the septal tissue was itself gray and swollen. The appearance of the inflamed lung was consequently very peculiar, and the circumstance is interesting from two reflections: 1st, that a chronic pneumonia with much thickening of the

Digitized by Google

septa is the result of syphilis; and, 2nd, that on the other hand acute pneumonia generally avoids and is stopped by the septa, so that one cannot help thinking that this may be a very acute syphilitic pneumonia.

Another curious feature of the case consorting with the described state of the lymphatics was this, that the glands about the root of the lung, though not much swollen, yet in many instances showed foci of suppuration about the incurrent lymphatics, these suppurations reaching one third of the distance into the gland. I need not say that this is a very rare condition; it has a certain resemblance to the behaviour of syphilitic infection of the glands. There was acute general peritonitis with much effusion; the lymph in greatest quantity about the liver, which was very irregular, indeed botryoidal in form. The tissue was coarsely lobulated, but soft; there were large tracts of potato-like, syphilomatous growth, having all the qualities of these growths in perfection. The lobulated tissue around them showed excessive minuteness of the lobules, with hardness. Closer to the potato-like substance there was gray fibrous tissue enclosing it, but the remaining intermediate and remoter portions of the liver were free from disease.

The spleen was in a remarkable state; it was large, weighing seventeen ounces, its capsule irregularly thickened, and its tissue peculiar. A considerable part of it lying irregularly at the surface under the capsule was blackish, as if from effusion of blood, and this part was bounded toward the centre by a marked line. The most central part so marked off was of natural colour, and soft and pulpy, yet in both these conditions the tissue had a fatty shiny appearance; neither it nor the liver gave lardaceous reaction. I could not make out anything satisfactory by the microscopic examination of the spleen. I found it impossible to say whether the quantity of pyoid- and lymphoid-corpuscles was or was not greater than natural. I was induced to bring it before the Society, being struck by the general resemblance its state bore to that present in the lung, which latter was certainly inflammatory. The condition that impressed one as requiring explanation was the existence of two such very different characters in different parts of the spleen. The dark, sharply-defined exterior part made up nearly half the organ; it was very irregular in shape and distribution, and not at all like the so-called embolic patches.

The spleen is liable to chronic local syphilomatous inflammation,

Digitized by Google

such as we find in the membranes of the brain, and it appears that in these membranes besides the chronic syphilitic disease an acute diffused granular syphilitic inflammation occurs. May the change in the instance before us be a corresponding acute diffused splenitis? *October* 18*th*, 1870.

---

2. *Specimen of enlarged spleen.*

By W. Squire.

The patient from whom this specimen was removed, November 23rd, 1870, *post-mortem*, was a gentleman, 40 years of age, who had been suffering for two and a half years from symptoms referable to this abnormal growth. He had always lived in a healthy and elevated situation in Yorkshire. His first illness was in March, 1868, when he had pain in the left hypochondrium. His medical attendant informed me that he then had a cardiac *bruit*, which afterwards disappeared. In February, 1869, he walked with difficulty, on account of a sense of weight and fulness in the abdomen. By October he was weakened by night perspirations; he had loss of appetite, pallor, and muscular weakness; sometimes epistaxis. He came under my notice at the end of November, 1869, on account of a doubt as to whether his illness was in any way attributable to a shock in a slight railway collision some two or three months previously, or to an enlargement of the liver, to which the medical referee of the railway company attributed his present symptoms. The abdominal enlargement was found occasioned by a tumour occupying all the left side of the abdomen, pushing up the diaphragm, and diminishing the region of to be pulmonary resonance posteriorly, filling the whole of the left lumbar region, ending in well-defined, rounded, firm edge, traceable from the front of the left ilium to the right of the umbilicus, a little above which was a well-defined notch, and above coming in contact with the left lobe of the liver, more prominent than it, and from which it was readily distinguishable. On December 1st after too much fatigue, he had a recurrence of

Digitized by Google

epistaxis; there were aphthæ on the tongue and lips; the urine was turbid, high in colour, and free from albumen; the pulse quick and weak; the temperature of the body was 10·25°. With rest during the next two days the temperature became 101·5° and 101°. On December 5th it was 101° in the morning, pulse 100; resp. 30. In the evening the temperature was 102°; pulse 110. For four days this state of things continued; it was then determined to give full doses (half a drachm) of quinine. During the last two days the temperature had been 102·5° in the evening; at noon the temperature was generally found at 101° or 101·5°; at noon, the day after giving the quinine, the temperature was 98·9°; the pulse 88; resp. 30; the urine became clear; there was no rise of temperature after this for some days, and the patient was able to take a journey into Yorkshire. At the end of February, 1870, the patient again came under my care for a return of the febrile condition; this was again cut short by quinine. Similar attacks occurred at the end of March, in May, and July; there was a recurrence of epistaxis. The blood was relatively if not absolutely fuller of white corpuscles. There was progressive emaciation, anasarca or œdema, varying in amount, finally ascites, with some pain over the most prominent part of the tumour. Death by exhaustion on November 21st, 1870. The spleen weighed 13 lbs., its length was 16 inches, breadth 10 inches, depth 5 inches, surface smooth, except for recent soft lympth. A spleniculus was developed on the under surface. On section some yellowish-white masses were seen near the exterior; the interior presented the appearance of general hypertrophy. No other deposit was found in the liver, kidneys, or other parts of the body. The heart had undergone dilatation of the right cavities with some hypertrophy, especially of the left side. There was some fluid in the pericardium. *December 6th*, 1870.

Digitized by Google

3. *Morbid growths in the spleen, lymphatic glands and other organs (Hodgkin's disease), complicated with acute tuberculosis.*

By J. F. Payne, M.B.

Charles S—, æt. 10, admitted into St. Mary's Hospital under Dr. Sieveking, July 5th, 1870. The patient was reported to have been ill ever since an attack of scarlet fever eighteen months before. He was greatly emaciated and anæmic. The spleen was found to be very large, reaching from the seventh rib to the crest of the ilium vertically, behind into the lumbar region, and in front almost to the middle line. The blood corpuscles were well formed, and though it was thought the number of white corpuscles was larger than normal, the blood was by no means like that of leukæmia. There was some jaundice, but there is no record of epistaxis or other hæmorrhage. The superficial abdominal veins were much distended. There were no enlargements of the external lymphatic glands. He became gradually weaker and died of exhaustion. The temperature on one occasion recorded as 101° F.

At the *post-mortem* examination the body was found much emaciated. The organs presented, for the most part, the features met with in cases of so-called Hodgkin's disease, metastatic lymphosarcoma, or lymphadenoma. The spleen was very large and hard; it showed on the surface some projecting yellow masses and other patches not raised above the surface, some of which were nearly an inch in diameter. On section it was found to be mottled and marbled with yellow and pink masses. The yellow masses were hard, tough, glistening, and not soft or crumbling. They were clearly tumours of the kind called lymphadenoma, and were very various in size and shape. Of the pink masses some were wedge-shaped, superficial, and resembled infarctus or fibrinous blocks; a view confirmed on finding the arterial branches leading to them obstructed. The capsule was not inflamed or adherent to neighbouring parts. The liver contained a few minute yellow tumours from the size of a pea to that of a shot. The right kidney also contained a few minute growths of the same kind. All these tumours

Digitized by Google

had the minute structure of lymphadenoma or lympho-sarcoma, and need not now be further described. The lymphatic glands were also very notably affected, though not so much enlarged as they often are in this disease. A large group of adherent and enlarged glands surrounded the left common carotid artery and became continuous with the bronchial and mediastinal groups which were similarly affected. A chain of glands was noticeable round the descending aorta, and there were less considerable groups in the hilus of the spleen and round the hepatic vessels. These glands were generally not larger than a hazel nut, and a very few were as large as a walnut. For the most part they showed the characteristic yellow glistening appearance and firm consistency of lympho-sarcoma; but it was especially noticeable that in some of them were masses of a soft caseous consistency, which would, had they occupied the whole of the gland, have caused it to be called scrofulous. There was, in fact, a distinct transition to the type of disease called by that name. In connection with this fact, the condition of the lungs and the meninges of the brain was specially interesting. The former were found to be closely studded all through with hard gray miliary tubercles, though the left was compressed by a copious pleuritic exudation, the result of recent inflammation. In the brain there was found recent meningitis of the base, and numerous miliary tubercles in the pia mater. These appearances evidently resulted from acute tuberculosis, and the most careful microscopical examination detected no difference between these productions and genuine tubercle. There was no similar affection of the peritoneum or any other part, and, with the exceptions stated, the organs were healthy. The blood, when examined after death, showed no excess of white cells or other abnormality.

Remarks.—This case is interesting for two reasons. (1) It establishes a transition between the enlargements of glands called lympho-sarcoma, or lymphadenoma, and those called scrofulous. A slight indication of such a connection had been previously observed by the writer in a case communicated to the Society in 1868.[1] (2) It is another instance of the sort of condition or disease which may be the antecedent of acute tuberculosis. *May* 16*th*, 1871.

[1] 'Trans. Path. Soc.,' vol. xix, p. 401.

Digitized by Google

(B) SUPRA-RENAL CAPSULES.

4. *Addison's disease.*

By Richard Quain, M.D., for Dr. Silver.

James Seabrook, a solicitor's clerk, æt. 24, residing in the Westminster Bridge Road, came under my care at Charing Cross Hospital towards the end of June, 1869. He was a native of Leicestershire, and though he had never been strong he had never suffered from any specific complaint till about two years prior to that date, when he caught ague in Cambridgeshire, and suffered from it for three months. He stated that up to that time his complexion had been rather fair and fresh coloured, but that ever since he had been growing darker and thinner. Lately he had been unable to do any work on account of his great debility, further indicated by a peculiarly slouching, stooping attitude.

On further examination it was remarked that his skin was dusky; deeper in tint in some parts than in others, especially over the nape of the neck and the lower part of the abdomen. His eyes were gray. His respiration was laboured, and he could not take a deep breath, apparently from weakness. He complained also of palpitation, and could not walk fast. At times he suffered from giddiness.

On the 29th of June he was admitted an in-patient under Dr. Headland, and remained in much the same state, except that his complexion became somewhat clearer; and there were some doubts as to the accuracy of the diagnosis until the 14th of July, when it is noted that he had become very incoherent in his replies; after which he gradually became weaker, and on the 30th it is noted that he presented decided cerebral symptoms, and had a vacant aspect. On the morning of the 2nd of August he was found dead in bed.

On examining the body after death the skin was found to be almost black over the genital organs, but lighter elsewhere. There was a moderate layer of fat beneath the skin all over the body. The vessels on the surface of the brain were rather fuller than usual,

Digitized by Google

and the lateral ventricles contained an unusual quantity of fluid. The optic thalami were softened, and their surfaces were somewhat eroded. On opening the chest the right side of the heart contained rather more blood than the left. The left lung was adherent at the apex and contained a few calcareous nodules, which were, however, more abundant in the right. The spleen weighed four ounces. The kidneys were healthy, and to them adhered firmly the supra-renal capsules, which were cemented into a hard calcareous mass on both sides. The condition of the calcified masses in the lungs and in the supra-renal capsules was as nearly as possible identical.

Were it necessary to add to the evidence already accumulated as to the association of Addison's disease with cretified or tuberculous supra-renal capsules, I might refer to two additional instances encountered this autumn, one at the Royal South Hants Infirmary, at Southampton, where the supra-renal capsules were described as cheesy, and another in the Devon and Exeter Hospital, where they were cretaceous. Both occurred in undoubted examples of the disease. *November 15th*, 1870.

---

5. *Addison's disease of supra-renal capsules; pigmentation of pia mater of spinal chord and of skin of genitals.*

By J. F. Payne, M.B.

Charles K—, æt. 32, admitted into St. Mary's Hospital, February 17th, 1871, under Dr. Sieveking. He complained, on admission, of pains chiefly in the legs and in the right shoulder, which he called rheumatic and which he attributed to his having caught a severe cold. There was no enlargement of the joints; the thoracic viscera were normal to auscultation; the urinary and digestive organs showed no abnormal symptoms. Once it is recorded that he vomited several times, but this was not a prominent symptom. There was gradual failing of strength, till he died rather suddenly ten days after admission. The complexion of

Digitized by Google

the face and the body generally was quite natural, except in the parts especially noted below.

Post-mortem examination twenty-seven hours after death.—Body thin, but scarcely emaciated; no external marks except that the skin of the genitals was very dark, the penis being of a clear mulatto brown, and the scrotum almost sooty black. On close inspection a very faint brown tint was seen on anterior fold of each axilla, over pectoral muscles; but this was not more than is often seen as the result of friction of clothes. An almost imperceptible brown tint existed over part of the chest; but the face and all other parts of the body showed absolutely nothing abnormal.

The thoracic viscera all seemed small, but were quite natural; the same was true of the liver (which weighed forty-six ounces), the spleen, and kidneys. The supra-renal bodies were both found very greatly enlarged, weighing each (as nearly as could be determined) about seven drachms; they were quite alike, except that the right was a little the larger; both were converted into a firm, greenish, somewhat translucent mass, the exterior of which was white and crumbling, and part softened into white puriform matter, which in the left had almost broken through. There was a layer of white fibrous tissue surrounding the greenish mass, and forming a firm investment. The right was very firmly adherent to the liver, to the vena cava, to the renal vessels, and also closely connected with the solar plexus, which was large and hard. There were near it two or three bodies looking like small hard lymphatic glands.

The solitary glands in upper part of large and whole of small intestine were prominent and hard. Peyer's patches not enlarged, but rather opaque. The colon contained, beside fæces, a large quantity of ropy mucus. The rest of the digestive and genito-urinary organs were carefully examined without finding anything abnormal.

In the brain there was nothing morbid; but the pia mater covering the medulla oblongata and upper part for two or three inches of medulla spinalis, was pigmented very deeply, being about as dark as the penis. No excess of pigment in any other part of the encephalon or membranes.

Remarks.—This case differed in no respect from the already recorded cases of Addison's disease; but the peculiar distribution of the abnormal pigment is worthy of note. The unusual dark colour of the genitals has previously been noticed in this disease, but it is

Digitized by Google

also not uncommon (as remarked by the President in the discussion on this case) for these parts to become darker in advanced life without any special disease. The same remark is true of an excess of pigment in the pia mater of the medulla oblongata, a dark coloration in this situation has been observed under very various circumstances. Microscopical examination of the dark portions of pia mater showed the pigment to be contained (as has been described by several observers) in the connective-tissue cells, which thus came precisely to resemble the cells of the choroid coat of the eye, the nucleus being usually light and the dark body of the cells connected by equally dark prolongations. Such a figure as that of Henle[1] would need no alteration to represent some of the pigmented cells, though it is drawn from the eye. These facts do not show that the pigmentation of the pia mater was unconnected with the supra-renal disease, but rather confirm the general result arrived at from other observations: that an abnormal deposit of pigment is likely to take place in those parts where pigment is, under normal circumstances, usually deposited. *March* 21*st*, 1871.

(c) THYROID.

6. *Cancer of the thyroid body, subsequent to ordinary bronchocele.*

By J. F. Payne, M.B.

This specimen was taken from the body of an elderly lady, a patient of Dr. Sieveking's, who died with symptoms of dyspnœa, evidently caused by some obstruction in the larynx or trachea.[2]

At the *post-mortem* examination the body was found fairly well nourished, with a good deal of subcutaneous, and also of omental, fat. Externally a swelling was observed in the front of the throat, in the position of the thyroid body; it was not very prominent,

[1] 'Handbuch der Anatomie,' ii, p. 617, fig. 470.

[2] See history of the case by Dr. Sieveking in Appendix.

Digitized by Google

quite unconnected with the skin, and very soft. On opening the neck there was found to be, in fact, a tumour occupying the position of the left wing and isthmus of the thyroid body, with which parts it was plainly continuous, but it was easily and completely separated from the neighbouring organs, and with these it had formed no adhesions. The right wing of the thyroid was quite unaffected, and preserved its natural size and position. The tumour had reached the middle line in front and curled backwards round the trachea, ending in a nearly spherical lobe about three quarters of an inch in diameter, which was inserted between the trachea and œsophagus, occupying precisely the middle line on the posterior aspect. The terminal lobe was extremely soft, and broke down on removal, giving exit to a whitish creamy substance. The general shape of the tumour was an irregular oval, bent into a curve. It measured about four inches along the convex surface, and weighed eight ounces. It had not pressed upon or affected the neighbouring parts except the œsophagus and trachea. The œsophagus, where it passed over the posterior lobe of the tumour, was thinned and compressed, and on opening it the mucous surface was seen to be eroded at this point, while below there was considerable superficial venous injection. The trachea did not seem to be altered in shape, but its inner surface was finely injected, as were also the larger bronchi. The larynx was quite natural. From the anatomical relations of the posterior lobe of the tumour it must, in all probability, have pressed upon the recurrent laryngeal nerve, where this passes between the œsophagus and trachea; but I regret that this point was not specially examined before the tumour was removed. There were some very large veins round, and especially below the tumour. The examination of the remaining viscera revealed nothing worthy of note. The only morbid condition met with was inflammation and dilatation of the bronchial tubes in parts of both lungs. There was no other morbid growth or glandular enlargement in any part.

On cutting into the tumour it was found to consist of an irregular central cavity, apparently the result of softening, with walls which were very thick and firm in the anterior portion, soft and almost destroyed behind. The cavity contained bright yellow creamy material, with some irregular solid masses which were highly vascular. The hard parts of the tumour were of a gray colour, and generally fibrous in texture, though with some semitransparent or colloid masses. The soft portions consisted of a cream-coloured

Digitized by Google

mass precisely like medullary cancer, and giving a thick whitish "juice." The medullary structure formed large distinct masses, and smaller nodules of the same material were seen isolated in the firmer portions of the tumour.

Microscopical examination.—The creamy juice obtained from the soft parts showed an enormous number of cells presenting a very great variety of shape, but generally flat and "epithelioid" in character. They were caudate, fusiform, or polygonal, and possessed one or more large nuclei. The multiformity and general character of the cells could hardly indicate anything else than true cancer. The cells were generally in a state of fatty degeneration, and there were, besides, many glomeruli and free fatty granules. In the the liquefied central portion many similar cells were seen; but there was a larger proportion of glomeruli, and many cells containing yellow pigment, as well as distinct pigment masses. The subsequent examination of sections made after hardening in chromic acid, confirmed the opinion first formed. The smaller nodules showed an anatomical structure quite typical of medullary cancer in the strictest sense; understanding by this a highly vascular nucleated stroma forming alveoli, in which were contained cells of epithelial character, very irregular in form, and quite unsymmetrically arranged without any intercellular substance. These alveoli were distinct from the natural follicles of the gland, though there existed in some parts certain transitional forms which seemed to indicate that the follicular epithelium might have been the starting point of the growth. On this point, however, it is impossible to speak with certainty.

Remarks.—The anatomical structure of this tumour showed that it represented two morbid processes, viz. colloid degeneration with hypertrophy, or bronchocele; and medullary cancer; while the clinical history shows plainly that the cancerous growth arose in an organ previously affected with bronchocele. Virchow[1] has collected several cases (four of which fell under his own observation) of the same sequence of these two diseases; and the coincidence is the more striking, if the rarity of cancer in the thyroid under any circumstances be taken into account. It appears to illustrate the general law that cancer is likely to arise, by preference, in some part of the body previously damaged by injury or disease. It is worthy of notice that the formation of cancer in the goitrous

[1] 'Die krankhaften Geschwülste,' bd. iii, s. 50.

Digitized by Google

tumour was accompanied by an apparent diminution in its size, and as there was an entire absence of pain, nothing occurred to direct attention to this part as the source of the violent dyspnœa to which the patient succumbed. The general belief of those who saw the case during life seems to have been that the obstruction to respiration was situated within the thorax. The solitary and painless character of the growth, and the absence of infection, either of contiguous or distant parts as well as of any notable emaciation or cachexia, are all points which show that there may be a stage in which all the characters commonly called malignant are entirely wanting even to the most pronounced forms of cancer.[1] *November 15th*, 1870.

Report by the Committee on Morbid Growths upon Dr. Payne's specimen of tumour of thyroid.—We have carefully examined Dr. Payne's tumour of the thyroid body, and agree entirely with him in his description and conclusions in regard to it. The diseased structure is made up mainly of aggregations of large cells presenting great varieties of shape, and, for the most part, an epithelial character, containing each one or more large nuclei, and having a marked tendency to undergo fatty degeneration. These aggregations of cells are imperfectly separated from one another by trabeculæ formed of fibres, all of large size, and containing large nuclei. In some parts of the tumour the smaller blood-vessels are remarkably abundant and distinct.

The appearances are altogether different from those of the normal thyroid body, although, in some situations, we recognise the apparently transitional character to which Dr. Payne refers, viz. a loculated condition of tissue in which the loculi are occupied by cells of large size and irregular form, and here and there small colloid masses, but in which the loculi appear to be separated from one another by a kind of transparent fibroid tissue without any evidence of the presence of a basement membrane.

J. S. Bristowe,
Thos. P. Pick.

February 7th, 1871.

[1] See Appendix, p. 354.

Digitized by Google

(D) ABSORBENT GLANDS.

7. *Tumour of the lumbar glands.*

By W. Howship Dickinson, M.D.

Some clinical interest attaches to this case from the fact that notwithstanding that tumours originating in the lumbar glands are rare, and are usually identical in position with renal growths, which are comparatively common, the seat of the disease was, in this instance, correctly determined during life. The circumstances which guided the diagnosis will appear in the following narration.

A boy named James Sutton, 3½ years of age, came under my care in the Hospital for Sick Children on the 6th of October, 1870. His parents, and brothers and sisters, were all alive and in good health. At birth he had a scrotal swelling which was regarded as a rupture, and had also two soft lumps in the right flank, which will be presently described. It was said that the belly was always large, but no definite abdominal tumour appeared to have been observed until a fortnight before his admission. At this date the belly became much larger as also did the scrotal swelling, and he began to have pain in the left side of the abdomen and in the hernia. There had been no trouble in passing water, and his general health had hitherto been good.

When he came under my care the belly was much enlarged owing to a swelling which occupied the right side, and bulged laterally so as to change the outline of the trunk. The shape of the tumour, as evident to sight and touch, is represented in the diagram (Woodcut 21). It was generally dull on percussion excepting that resonance, such as belongs to intestine, existed over the tumour to the inner side of the dotted line; it could be felt here that the mass lay a considerable distance behind the front wall of the belly. Where the tumour was in contact with the parietes some parts could be felt to fluctuate clearly, others obscurely or not at all.

In the right lumbar region, nearly corresponding to the position of the kidney, were two rounded bosses, each about an inch in diameter and of half an inch projection, which gave an impression of fluid like superficial cysts. In the right side of the scrotum was a consider-

Digitized by Google

able swelling like a hernia, which consisted of much solid matter, in contact of which the testicle could be felt, and some fluid which could be squeezed back into the belly and communicated fluctuation to the abdominal mass.

WOODCUT 21.

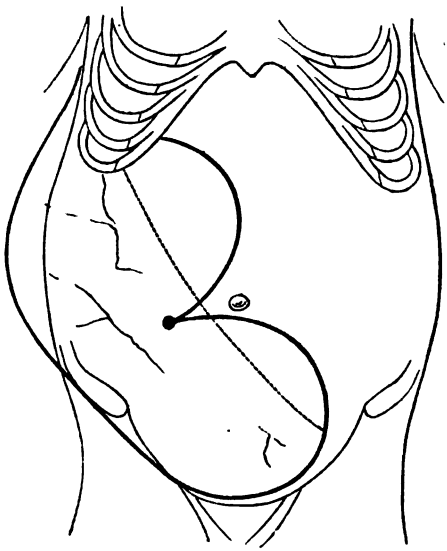

Outline of tumour of lumbar glands as sketched during life. The dotted line shows the extent of dulness.

Before the patient was placed under my care my colleague, Mr. T. Smith, punctured the scrotal swelling and withdrew twenty ounces of deep straw-coloured fluid which had the characters of serum. It was alkaline, highly albuminous, and became gelatinous on standing. It had a specific gravity of 1016. Before the operation the girth of the belly was 24¾ inches; after it, 24¼ inches.

The urine was natural. His general health at this time was good, and it so remained until November 4th, when he was observed to be feverish and complained of pain in the belly, which on measurement was found to have lost three quarters of an inch, now measuring 23½ inches. On the 11th the pulse was rapid, 144, the breathing was also quick, and both lungs were found to be pervaded

Digitized by Google

with coarse crepitation. There was a little cough, but no expectoration. On the 12th the abdominal swelling had notably shrunk, the curved prominences above and below the umbilicus appeared to have fallen in, and the line of intestinal resonance had moved considerably towards the right side. He was occasionally sick. On the evening of the 18th the vomiting became urgent and he had much abdominal pain. He now rapidly sank; he lay on his back with the legs partly drawn up, in a half conscious condition, with dilated pupils, twitching hands, and an almost imperceptible pulse. In this condition on the 19th he died.

Post-mortem examination.—The body was somewhat emaciated, weighing 25¾ lbs. The heart and lungs were natural.

WOODCUT 22.

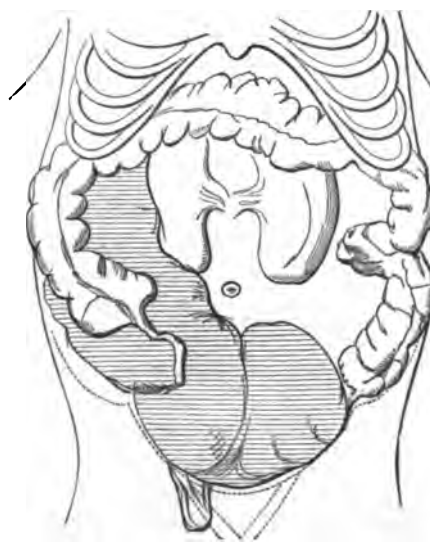

Position of the tumour on post-mortem examination after removal of small bowel.

Upon opening the abdomen the bowels were seen to be partially displaced by a tumour which lay behind the peritoneum on the right side. The small intestine overlapped its inner edge, while the outer part was in

Digitized by Google

contact with the front wall of the abdomen, excepting where it was separated from it by a piece of large bowel. On the removal of the small intestine the tumour was seen to occupy the situation represented in the sketch, with the cæcum and ascending colon in front, the rectum behind. The right kidney was compressed between the tumour and the spinal column so that its external and internal edges were converted into flat surfaces. The mass extended from the liver and diaphragm above to the pelvis below, from whence a prolongation passed, as will be presently described, into the scrotum.

The tumour consisted of a collection of cysts which contained serous fluid. A large cyst which formed the upper half of the tumour had evidently broken and collapsed, the contents having entered the peritoneal cavity. The emptying of this large cyst accounts for the absence in the post-mortem outline of the bold curve, which in the diagram taken during life sweeps inwards above the umbilicus. When removed from the body, under which operation further collapse of the cysts occurred, the mass measured about a foot vertically and five inches in extreme width. It was covered in front by the peritoneum. The right supra-renal capsule, somewhat flattened but unaltered in structure, adhered to the anterior surface of the tumour. Posteriorly it was bounded by the muscles which lie on the hinder and lateral part of the abdomen: these muscles had been encroached upon by the cysts, the walls of which they contributed to form, so that many of the cysts in this neighbourhood had a lining of muscular fibres much like the musculi pectinati of the auricle.

The cysts of which the tumour consisted were not numerous, but generally of considerable size; the largest would have held about half a pint. They generally communicated together by rounded openings. Some were lined with muscular fibres as described, others with fasciculated fibrous tissue which resembled in appearance and arrangement the inner surface of the bladder.

The cysts contained highly albuminous fluid.

Much solid fibroid matter lay about and between the cysts, especially at the upper part of the mass where was a collection of rounded masses which had a close external resemblance to absorbent glands, though microscopically they mainly consisted of fibrillating cells such as are represented in the woodcut (23).

At the lower end of the growth was a large, elongated, thin-walled cyst, which was scarcely inferior in size to the large cavity at the upper part of the tumour. This passed downwards behind the

Digitized by Google

inguinal canal and entered the scrotum after the manner of a hernia, though it lay not in but behind the tunica vaginalis. The testicle was closely adherent to the solid matter which formed the front wall of the cyst. The testicle itself was perfectly natural in size and structure. The portion of the cyst within the scrotum communicated freely with that which remained within the abdominal cavity. The finger could easily be passed from the abdominal to the scrotal part of the cyst.

The tumour was reserved for minute examination by the Committee on Morbid Growths, but it may be stated in general terms that the solid portion of the growth mainly consisted of nuclei such as belong to the lymphatic glands, with an extensive formation of fibro-nucleated structure such as is represented in the sketch. Much fatty tissue was intermixed.

WOODCUT 23.

Cells, fibres, and nuclei, from the solid part of the growth.

Digitized by Google

The peritoneum lining the abdomen and covering the under surface of the diaphragm, the anterior parts of the liver and spleen, and the surfaces of mesentery and intestine was plentifully besprinkled with little gray hard nodules, which had a superficial resemblance to miliary tubercles. These appeared to be not outgrowths from the serous membrane, but superficial fixtures which had attached themselves after the manner of parasites. They could be readily detached, many of them by the slightest touch, leaving the membrane beneath polished and unbroken. These minute "epiphyses" presented under the microscope a fibro-nucleated structure resembling that of the solid part of the tumour.

WOODCUT 24.

Structure of the superficial growths attached to the peritoneum.

Commentary.—In the last volume of the 'Transactions' I described the relations of an encephaloid growth which had originated in the lumbar glands. The position of the tumour and the alterations it produced in the shape of the body were nearly the same as in the present case, the chief difference being that in the former example there was no scrotal complication. From the experience then afforded, taken together with the fact that in this instance the growth extended to the scrotum, it was inferred that here also the lumbar glands were the seat of the tumour; either primarily, the growth having existed at a period antecedent to the descent of the testicle and having been carried down with it in its progress to

Digitized by Google

the scrotum; or secondarily, the disease having begun in the testicle and subsequently reached the lumbar glands by the absorbents. The post-mortem examination proved that the first hypothesis was correct. The growth had evidently commenced at an early period of fœtal life, either in the lumbar glands or in their immediate vicinity, and had been conveyed downwards into the scrotum by the testicle to which it was closely adherent. The glandular substance of the testicle, the epididymis, and the vas deferens were perfectly natural, though the tumour was closely adherent to the outside of the organ. The growth had evidently arisen either in the absorbent glands or in the connective tissue about them. The lymphoid elements of the tumour are consistent with a glandular origin. The mass, which would formerly have been roughly described as sero-cystic, is one to which the term 'adenoid' would now be applied, consisting as it does of lymphoid corpuscles, entangled in areolar tissue and intermixed with fat and irregular excavations.

The death of the patient apparently resulted from the bursting of the largest cavity into the peritoneum. Nature thus instituted a fatal but highly instructive pathological experiment, illustrative of the independent vitality, or, in other words, of the malignancy, of formations of this nature. The scattered nuclei or germs let loose by the bursting of the cyst, seemed to have attached themselves parasitically to the peritoneum and to have gradually established, with more or less completeness, a nutritive connection with that membrane. In vol. xii, p. 92, of the 'Transactions' I described a case in which a cancerous growth had become similarly disseminated, and other cases have been since recorded in which cancer cells have been in like manner transplanted. The observation in this instance establishes a close relation in malignancy between adenoid and cancerous growths. *December 20th*, 1870.

Report by the Committee on Morbid Growths upon Dr. Dickinson's case of tumour of lumbar glands.—The specimen referred to us for examination consists of a number of cysts, in various stages of development. For purposes of description they may be divided into three sets: 1st. Cysts proper, *i.e.*, sacs of various sizes, which constitute the greater part of the tumour, and which were stated during life to contain "clear serous fluid;" 2nd. Cysts filled with solid contents; 3rd. Solid matter, in which could be seen, even with the naked eye, minute loculi or spaces.

Digitized by Google

1st. *The simple cysts.* These constitute, as above stated, the greater part of the tumour. They are about a dozen in number, freely communicating with each other and varying considerably in size and in the thickness of their walls. At the lowest part of the tumour is the largest cyst, capable of holding about half a pint of fluid, the walls extremely thin and diaphanous, and traversed by numerous fasciculi of muscular tissue, which give the internal surface a fasciculated appearance, resembling the mucous membrane of the bladder. This cyst communicates with the other and smaller ones, situated at the upper part of the tumour by a rounded opening, sufficiently large to admit the index finger. These smaller cysts vary in size from a hen's egg to a hazel nut; communicate with each other by rounded openings, and have walls of very much greater thickness than the large cyst first described. The lining membrane of some of these cysts is fasciculated, and presents bands of muscular tissue running in various directions. In others it is studded with numerous small, projecting hemispherical bodies lodged in pits or depressions, apparently formed by interstices left between the fasciculi of muscular fibre, which form the wall of the cyst. These little growths are made up of a tissue which is histologically simple fat.

2nd. *Cysts with solid contents.* Interspersed among the cysts are a number of solid rounded bodies, which prove to be closed cavities filled with fat. The fat can be removed from these cavities, and they then present an identical appearance to the cysts already described.

3rd. *Solid matter.* At the upper part of the tumour is a considerable mass of solid matter. On section this presents a somewhat cystic appearance, bands of fibroid material are to be seen running in every direction and forming little loculi or spaces sufficiently large to be seen with the naked eye. Some of these are empty; others filled with fat. This gives it the appearance of being made up of two kinds of material, and upon tinting sections with carmine they can be readily distinguished from each other; one very transparent, uncoloured, and having the aspect of fat, the other denser and more opaque and deeply stained by the colouring matter. Upon cutting thin sections of the solid growth it is found to be composed of fibrillated tissue in which cells are imbedded, and containing spaces and cavities. These little spaces appear to be formed simply by an absence or deficiency of the structure of the growth; they have no distinct boundary or wall and contain no

Digitized by Google

epithelial formation. Some of them are empty, others contain fat and constitute the transparent portions above alluded to, consisting of adipose tissue, having no peculiarity except that the connective tissue enclosing them is very distinct, and that spurs or prolongations of the more solid growth are to be traced extending between the globules. The substance between the spaces is made up of a fine web of delicate fibrils, in which cells are imbedded. The cells vary in size and shape in different parts, some being elongated and attenuated fibro-cells, others rounded nuclear bodies, crowded and held together by a delicate hyaline membrane. The two varieties of cysts vary in amount in different parts of the growth. In places the smaller nuclear bodies are densely aggregated, presenting a mass of cells undefined in outline and without any regular arrangement. In other parts the fibro-cells are the more abundant and appear for the most part to cluster around the vessels, which can be seen passing here and there through the section; and again, in other parts, the smaller cells are to be seen grouped together and having a general tendency to become merged into the larger ones.

The nuclear bodies are rounded or oval in shape, some few angular. They contain a distinct nucleolated nucleus and some granular matter.

From the above characters we are disposed to regard this specimen as resembling an adenoid growth, developed in a fibro-nucleated tissue and complicated by the formation of cysts, probably caused by the breaking down of the tissue itself.

T. S. Bristowe,
February 7th, 1871. Thos. P. Pick.

Digitized by Google

8. *Mesenteric tumour.*

By W. Howship Dickinson, M.D.

Alice Howell, 2 years of age, came under my care in the Hospital for Sick Children on the 9th of November, 1870.

Her family history was unexceptionable. When she was between three and four months old her mother noticed a swelling in the left ileo-lumbar region, which gradually increased in size and became hard. The child's health did not obviously suffer in consequence, though she was always delicate. The bowels were regular. She cut her teeth early, and has walked for the last two months.

On admission the left side of the abdomen, as shown in the accompanying diagram (Woodcut 25), was occupied by a globular tumour, which reached from the ribs to the crest of the ilium. On the lateral part of the belly the mass could be felt hard under the fingers and close to the abdominal wall, giving much the sensation which is imparted by an enlarged spleen. The mass, however, was shaped quite differently from this organ, as towards the right side it could be felt gradually shelving away from the front wall of the belly, and retreating behind the bowels, as if nearly spherical in shape. The part of the mass which was in contact with the wall of the belly (unshaded in the diagram) was quite dull on percussion, the retreating part was resonant, as if covered by the bowels, so that its outline could only be made out by palpation.

The superficial part of the tumour was crossed in two places by intestine, which could be felt under the fingers, though imparting little or no resonance. The position of the bowel, as apparent during life, is shown in the diagram. Following the mass backwards round the left side, the hardness and dulness could be traced back as far as the edge of the deep lumbar muscles, in front of which it lay. The mass caused no lateral protrusion of the trunk. It was not tender on manipulation, and was generally smooth and even, excepting near the epigastrium, where it was somewhat nodulated.

Digitized by Google

The girth of the abdomen was 20½ inches. The child was fairly well nourished, though slightly rickety. The pulmonary and cardiac sounds were natural, the skin cool, the appetite good, and the bowels regular. Pulse 120.

She weighed nineteen pounds. The cervical glands were slightly enlarged, and became more so during her stay in the hospital. She lost weight to a slight extent, a slight pustular eruption appeared on the face; and she had a little bleeding from the nose and from one ear.

WOODCUT 25.

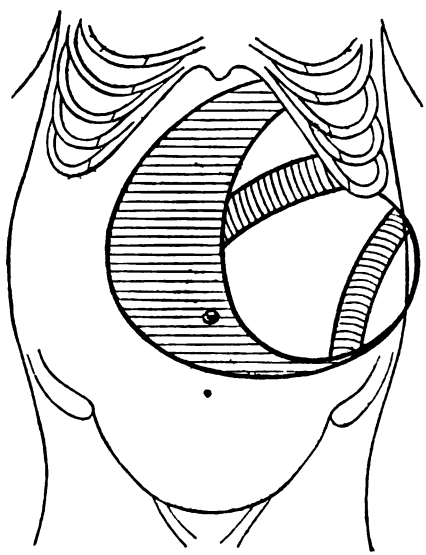

Outline of the tumour as sketched during life; the shading shows the position of the bowels in front.

Towards the end of January her appetite, which had previously been good, failed, her pulse quickened, she became feverish, and her countenance assumed a livid hue. She gradually sank, and died on the 9th of February, exactly three months after her admission.

After death the body weighed 16 lbs.

The thoracic viscera were natural, excepting slight œdema of the lungs.

On laying open the abdomen the tumour was seen to occupy the

Digitized by Google

position represented in the diagram. It nearly filled the left half of the cavity, and encroached somewhat upon the right side, pushing the bulk of the intestines across to the right. In front of the tumour lay the transverse colon and cæcum above, and a coil of small intestine below, the latter being inseparable from the mass. The large bowel above and the coil of small intestine below were the portions of bowel evident to touch during life.

WOODCUT 26.

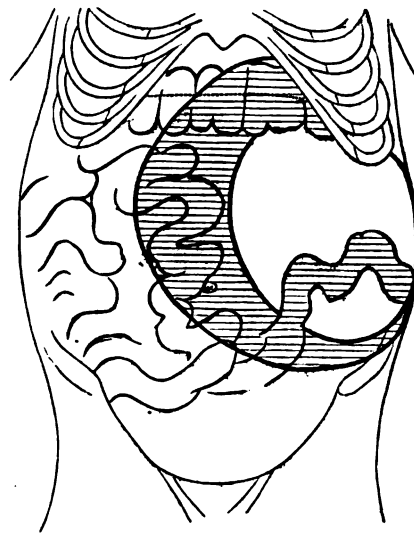

Relations of the tumour as seen upon opening the abdominal cavity; the shading shows the position of the bowels in front.

The spleen was concealed above and behind the upper end of the growth. The left kidney and supra-renal capsule (the latter closely adherent to the tumour) were in contact with it behind.

The weight of the mass, together with the left kidney and a small portion of small intestine, was 2 lbs. 5½ ounces. It was nearly spherical, measuring four inches from above downwards, four inches from behind forwards, and five inches from side to side, so that its long axis was transverse.

It lay immediately behind the peritoneum. The colon was at-

Digitized by Google

tached to its upper margin, the anterior layer of meso-colon overlying the front of the mass. At the lower part towards the left side, as seen in the diagram, a knuckle of small bowel was inseparably fixed. The laminæ of the mesentery proceeding thence were separated by the tumour which lay between them; one of the mesenteric folds passed upwards, the other downwards, enclosing the tumour between them.

The growth was hard and rigid. On section it was of a very irregular hardness, cutting as if bits of bone were interposed among softer tissues. The structure was coarsely cellular or porous, resembling, except in hardness, very light bread, or a section of coarse sponge.

The structure proved to be highly composite. The solid portions consisted of fibroid tissue, fat, cartilage, and calcareous or bony masses. The fibroid tissue occurred abundantly in the common fibrous shape, such as belongs to old tendinous structures, and also in the form of highly nucleated new fibroid tissue, the latter in places forming the bulk of the tumour.

Intermingled with this was much fat, which had the microscopic characters of ordinary fatty tissue.

Plentifully interspersed among these materials were numerous irregular plates, and angular masses of true cartilage; these looked and cut like cartilage, and displayed under the microscope the structure characteristic of this substance.

There were also many nodules or cores of extremely hard substance which could scarcely be cut with a knife. One of these, which I examined minutely proved to be simply calcareous, devoid of any bony structure. It dissolved with effervescence in hydrochloric acid. True bone was afterwards found in the tumour by the Committee on Morbid Growths.

All these elements formed together a hard but spongy framework, thickly beset with round or ovoid cavities, which varied in size from a small marble or large bean to a pin's head.

These were filled with a stringy, translucent fluid, such as is found in myxomatous growths, and which closely resembled thick nasal mucus. It contained only a trace of albumen, giving but slight evidence of coagulation with heat, but coagulating in bulk on the addition of acetic acid, the clot not being soluble in excess of acid. Under the microscope the fluid displayed, as shown in the cut, numerous large granular bodies, large nucleated cells, smaller corpuscles like mucus or pus, but neither nucleated like pus nor

Digitized by Google

coherent like mucus, fragments of fatty tissue, and plates of cholesterine.

The spleen was natural in size, shape and general texture. About the middle of the convex surface was a white, sharply limited patch which looked like the surface of an embolic block; on section the same resemblance was maintained, the alteration passing into the

WOODCUT 27.

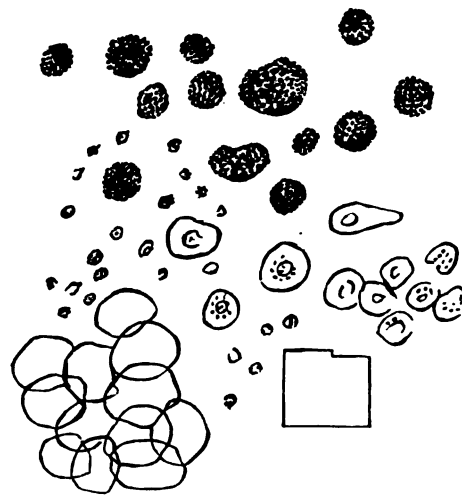

Microscopic elements of the mucíform fluid.

organ for the depth of about half an inch, and being bounded by a definite sinuous line, which was in close apposition to two small blood-vessels.

The white patch was harder than the surrounding tissue; its structure was close and opaque. Under the microscope some plugged blood-vessels were traced into it, though its general composition was not that of an embolic block, consisting of innumerable small round or ovoid corpuscles, such as might have been derived from a lymphatic gland, with many fibrillating cells.

Commentary.—The position of the bowels, with regard to abdominal tumours, often furnishes an important guide as to their seat.

Digitized by Google

It may be generally stated that when, as in the instance under consideration, bowel can, by percussion or touch, be detected in front of an abdominal tumour, that the growth is not hepatic, splenic or gastric. Dr. Bright[1] has, indeed, recorded a case in which a portion of small intestine was found after death in front of the liver; this malposition, however, was unconnected with hepatic disease, and probably congenital; it is certainly of extreme rarity. A tumour in front of which intestine lies may be renal or supra-renal; it may be of glandular origin, connected, as illustrated by the preceding case, with the lumbar, and by the present with the mesenteric glands. It may be, though it rarely is, uterine or ovarian.

I have examined after death ovarian tumours, which have had bowel fettered by adhesions between themselves and the front wall of the belly; but such a contingency is rare. An ovarian or uterine tumour, as it rises out of the pelvis, usually pushes the bowels aside and impinges upon the abdominal wall, having intestine above, behind, and on each side, but not in front.

In the majority of instances, therefore, the presence of bowel in front of an abdominal tumour may be held to indicate that the mass is renal or supra-renal, or, as in the two cases just related, glandular. The distinction between a tumour of the lumbar glands and of the kidney is difficult, perhaps impossible, except under such circumstances as were pointed out in the preceding communication. Mesenteric may often be distinguished from renal growths by their more central position, and by the absence of the marked lumbar tumefaction, which is produced by a tumour of any size connected with the kidney or lumbar glands.

As to the nature of this highly compound tumour it will be seen that, perhaps with the exception of the epithelial cells in connection with the cavities, all its varied components were developmentally allied to connective tissue. Fibroid tissue and fat, commonly associated in connective tissue, were abundantly present. There was mucous fluid resembling that belonging to embryonic connective tissue, except in the particular that when precipitated by acetic acid the precipitate was not resoluble in excess. The fluid in all respects, however, resembled that of a myxomatous tumour, except in its confinement to distinct cellular cavities.

Cartilage and its products, calcareous matter and bone, were

[1] Bright, 'On Abdominal Tumours,' p. 259. Sydenham Society.

Digitized by Google

intermixed. Cartilage, as in fibro-cartilage, and in various tendons and tendinous sheaths, is often associated with connective or fibrous tissue.

The mass found in the spleen, which in all probability was secondary to the mesenteric formation, had the ordinary structure of an adenoid growth.

We may presume that the tumour had originated, probably during fœtal life, in the connective or adenoid tissue belonging to the mesenteric glands. *March 7th*, 1871.

Report by the Committee on Morbid Growths upon Dr. Dickinson's mesenteric tumour.—The tumour exhibited by Dr. Dickinson is highly complex. Its great bulk seems to the naked eye formed of dense white fibrous tissue, interspersed with irregular masses of fat; here and there, however, are lumps of what look and cut like cartilage (the sectional area of the largest measuring about a quarter or one third of an inch in diameter); and here and there large irregular masses of bony or earthy deposit. The tumour, moreover, presents numerous cysts, roughly speaking from the size of a hazel-nut to that of a pin's head, which are full of mucus, the abundance of which makes a fresh sectional surface seem as though mucus were exuding generally from it.

Under the microscope.—The dense white fibrous matrix was found to be formed chiefly of ordinary white fibrous tissue closely arranged, which swelled up and became transparent under the influence of acetic acid, displaying then abundant connective-tissue corpuscles united with one another by a network of fibres; the fatty matter interspersed in this was found to be ordinary adipose tissue; the cartilaginous nodules presented all the usual characters of ordinary cartilage, such as that of the ribs; and the earthy masses (when thin sections were made) were found to exhibit abundant lacunæ and canaliculi, and all the common microscopic features of true bone, excepting that few, if any, Haversian canals were to be seen. Besides the larger masses of bone here described, numerous microscopic, earthy nodules were found imbedded in the fibrous tissue; these were tuberculated or botryoidal masses such as are met with in the earthy deposits arising in old false membranes, and were described and figured some years ago by Mr. Salter as of common occurrence about the fangs of teeth.

The cysts, besides varying in size, varied in the nature of their parietes and in the character of their contents. Most of them

Digitized by Google

presented smooth surfaces, but some had pulpy, flocculent walls, and were then crossed by bands and imperfect septa of the same character. The former cysts appeared as though they were fully formed, the latter as though they were in process of development. The contents had in every case the characters of mucus, but they varied in density, in opacity, and colour. Under the microscope the mucus was found

WOODCUT 28.

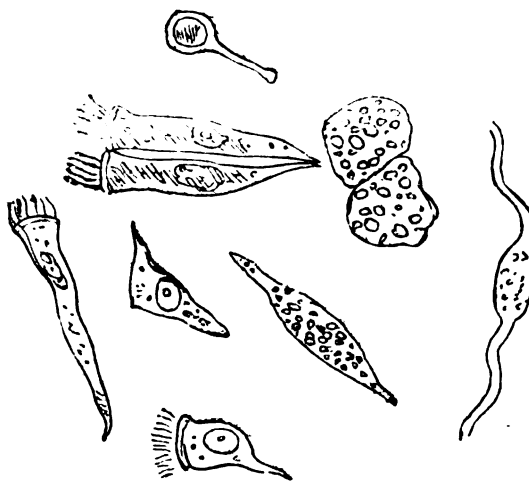

Cells found in the cysts.

to contain in varying proportions (according to its source) fat-globules, stellate groups of fat-crystals, plates of cholesterine, myeline, and cell-forms in great abundance. These latter varied much in character; the most remarkable and the most abundant were epithelial cells, for the most part adherent into flakes. These varied in form, but were generally cylindrical, and in a very large proportion of cases were distinctly ciliated. The ciliated character was not limited to the cells of a single cyst, but was recognised in the epithelial cells of all the cysts that were investigated. The flakes of epithelium were at first sight not unlike those detached from the surface of the intestinal villi. Besides these were numerous cells, round or oval, and of various sizes, which were more or less loaded with fat-globules, and in some cases formed distinct glomeruli. In

Digitized by Google

the parietes of the cysts were, for the most part easily recognised, the white fibrous tissue which formed the bulk of the tumour; but it seemed that the fibres were more loosely arranged here then elsewhere, and that there was a tendency to enlargement of the connective-tissue corpuscles and to their fatty degeneration. These changes were, however, very much more marked in connnection with the cysts presenting flocculent parietes.

The tumour was remarkable in its complexity of character. It consisted, as before stated, in its great bulk of ordinary connective tissue studded with true fat, and in the substance of which cartilage and bone had both become developed, and cysts in large numbers had formed. It appeared to us that the cysts had been produced by the continued proliferation of the connective-tissue corpuscles, their fatty and mucous degeneration, and the softening and disintegration of the intervening fibrous material; that they were probably, therefore, in the first instance, flocculent-walled, and that their smooth-walled condition represented a later stage of their formation. The ciliated epithelium was doubtless developed from the connective-tissue corpuscles of the tissue bounding the cysts.

Although the tumour contained large quantities of mucus, this was limited to the cysts, and was not diffused throughout the substance of the growth. It did not appear to us to be a myxoma in the sense in which Virchow uses this term.

J. S. Bristowe,
Thos. P. Pick.

May 2nd, 1871.

Digitized by Google

X.—DISEASES, ETC., OF THE SKIN.

1. *General alopœcia with microscopic specimens of the hair and nails.*

By Edwards Crisp, M.D.

Although general alopœcia is spoken of by all writers on skin diseases, there are but few records of cases, and it is on this account that I am desirous of bringing the matter before the Society. The subject of the following case is a very intelligent friend of mine, especially distinguished in one department of zoology. I have had many opportunities of seeing him and of making microscopical examinations of the few hairs and hair bulbs that could be found on the scalp. I give the history of the case in the patient's own words.

"Agreeably with your suggestion I hasten to give a sort of sketch of the progress of this disagreeable disease that has attacked me. I may preface it by stating that I have always enjoyed excellent health, and since I had the malarious fever, in 1857, I have never required a doctor's advice. In my habits I have been very regular in every respect, fond of out-door exercises when I could indulge in them, and otherwise fond of books. From 1852 to 1856 I have been a great traveller and sportsman, and have undergone considerable hardships and fatigue in different parts of the globe (chiefly wild countries) and have been blessed with excellent health and considerable bodily strength and activity. Since 1866 I have been living near town, working hard in the city, and leading rather a sedentary life, spending my evenings in the study of science.

I first noticed signs of alopœcia in September, 1869, after returning from the British Association Meeting, and then observed a tiny bare spot in front of the parting of my hair, which was very thick and abundant. I took little notice of it for about a month, when I observed that it had increased, and then went to a hair-dresser, who touched it with acid. I may mention that about this time I had a

Digitized by Google

numbness in the skin of my left side from the armpit to the hip, as if the side were asleep. As the bald place increased in size and another appeared at the back of the head, I consulted Mr. F—, who touched the places with glacial acetic acid, blistering them considerably. This was in December, and finding that still they grew larger I considered that a trip in the country might do me good and accordingly went away for a month or six weeks. During the whole of this time my health was excellent and I could observe no diminution in bodily strength or otherwise, and a ten mile walk did not tire me in the least. My skin looked perfectly healthy and clean. All this time the spots increased in number, and late in January I counted fifteen on different parts of my head, chiefly at the back and above the ears. About the 15th of January I observed a spot on each side of the face over the jawbone, and my beard, which was very thick and long, began to comb out. About the 20th of January the hair about the navel, and in spots on the arms and legs (where I was very hairy), began to come off. All this time I used acetic acid and washed myself every day with Pears' soap. On my return to town Dr. F— stopped the acid and gave me strong doses of arsenic, which, however, effected no change.

Late in February I consulted Mr. W—, whose prescriptions I showed you. Up to the middle of March the spots increased gradually in size, but even then my hair was thick enough to hide them. I had then lost all the hair about and below the navel, and a spot appeared on the chin, forcing me to shave my beard and only wear long whiskers and moustache. Early in April I caught cold and had a severe attack of shingles, which confined me to the house. The hair then began to fall so very rapidly that about the 20th April I had to have my head shaved and wear a wig; my whiskers had then become very small. I went for a week to the sea-side, and during that time lost all the rest of my whiskers, and my moustache began to fall from the lower part upwards, but was then long enough to meet under the chin. Within a week, that also went, and my eyelashes began to thin and spots appear on my eyebrows. Late in May my eyebrows and lashes began falling rapidly, and the hair on the chest and under the armpits began to go, the rest of my body being then quite bare of hair. Early in June I went boating and rowed for ten days, finding that I had no lack of strength or activity, and could easily do a heavy day's work. I had still continued with Mr. W—, but about the end of June I consulted Dr. S—, who has also

Digitized by Google

been unable to give me any relief. About the middle of July the last hairs went and I was, as I now am, totally hairless. I may remark that after shaving, the hairs would grow about one sixteenth of an inch, and then gradually fall out. They never grew longer.

I may add that our family are unusually healthy, and that I cannot possible have inherited any taint of disease, nor has there been scrofula in the family. I have myself never been attacked by any venereal disease in any shape whatever, and have never, to my knowledge, taken mercury. In fact, since 1857, I have never had to take medicine. As I before told you, I cannot think of anything that I can have done which would cause disease of any sort, or weakness, and am now, at this present time, in excellent health; possess, probably, more bodily strength than most men of my size and weight, and can run a mile or two with most men. I can detect no difference in my state of health to what it was previously, except that this summer I have not been at all bilious."

The finger nails of this gentleman are also affected; they split in layers and bend back when cut; they are of a brownish colour, as if stained with walnut juice; they are rough, with numerous indentations and furrows, and the white mark at the base is invisible. The toe-nails are in a normal condition.

I have made a careful microscopical examination of the few roots of hair remaining on the scalp, and of the nails, and I fail to find any trace of fungus in either of them. The root of the hair is generally irregular in form, with lateral projections and often with root-like elongations at the base. The shaft is generally brittle and splits into various sections. The colour is unaltered.

The accompanying drawings that I have made of the hair, magnified 20 diameters, and of the nails, give a correct notion of the appearances observed.

Remarks.—The most extraordinary circumstance connected with this case, is the excellent state of health and strength of the patient, and the entire absence of any cause that would account for the loss of hair. The feeling of numbness of the left side is a symptom that should not pass unnoticed; it may lead some to think that a failure of nerve power was the cause of the alopœcia. Bazin 'Sur les Affections Cutanées Parasitaires,' believes in the fungoid origin of this disease, as did Gruby, Cazenave, and others; but it should be remembered that the presence of fungus sporules is no proof that the affection is of parasitic origin; fungus affects many parts that have

Digitized by Google

a low amount of vitality, and, I believe, it is often the effect, and not the cause, of some cutaneous affections that are supposed to depend upon vegetable growth.

WOODCUT 29.

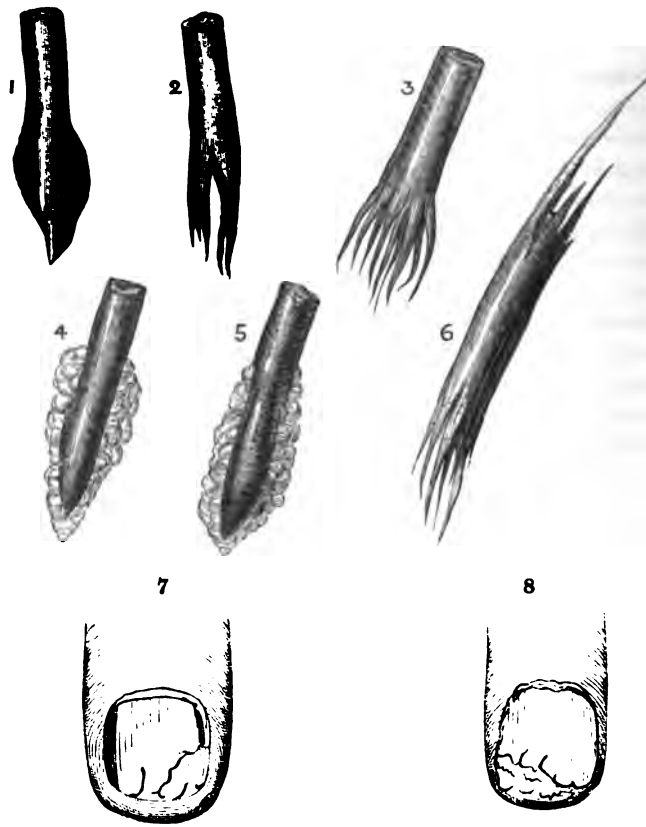

1, 2, 3, 4, 5. The bulbs of a few short hair stumps left on the scalp (one inch power).

6. A portion of hair, showing its brittleness and disposition to split.

7, 8. The appearance of the nails.

I have consulted various authors, and I have made extensive inquiries among medical men, respecting the occurrence of general and total alopœcia, and I find that the disease is extremely rare.

Digitized by Google

There are two forms, or rather two degrees, of this affection—one in which the baldness is for the most part confined to the hair of the head and face, and the other in which there is total loss of hair (as with my patient) in every part of the body. Of the latter examples I have met with seven cases; two of these have come under my own observation. One, in 1829, in a young clergyman, who, without any apparent cause, lost all the hair off his body, and it was not restored some years after 1829. The ultimate result I am unable to state.

There is one fact in relation to this affection, judging from my limited statistics, that is curious, and, as far as I know, unaccountable, viz. that nearly all the subjects of the complaint are strong, young, healthy men, whilst in *Porrigo decalvans* the majority of the patients are among the female sex. Of the seven cases of total alopœcia that I have collected, all were males. Of the eight examples of the disease, confined chiefly to the head and face, six were males and two were females.

I may, in conclusion, remark that the total loss of hair is not confined to the human species. I have met with three examples of hairless mice, and both the horse and the dog have been seen in the same condition. *August* 10*th*, 1870.

---

2. *Specimens of skin and liver from a case of diffused scleriasis.*

By C. Hilton Fagge, M.D.

These specimens were taken from the body of a woman, æt. 64, who had been exhibited to the Society during her life time in the year 1869, and who presented an extreme degree of the affection which was first described by Thirial as 'Sclérème des Adultes,' and which I have been in the habit of terming "diffused scleriasis."

She continued to attend as an out-patient at Guy's Hospital until within a week or two of her death. But she gradually became feeble from the difficulty she experienced in taking nourishment, owing to the fixed condition of the jaws. The skin of the face, in

Digitized by Google

fact, became so tight that she was scarcely able to move the mouth, and she thus died of starvation.

The *post-mortem* examination was made at the patient's home on October 31st, 1870, by Mr. W. Burgess and myself, about twelve hours after death.

The body was much emaciated. The face was not wrinkled. The limbs were rigid; the elbows were flexed; the mouth was partly open. It was impossible to determine how far this was due to rigor mortis, as distinct from the scleriasis.

The skin was of a yellowish colour, and was still very hard, but that of the forearms appeared to be more movable on the subjacent parts than it had been during life. It was tightly stretched over the tissues beneath, so that in sewing up the body there was a difficulty in making the two sides of the incisions meet. On the left elbow, as well as on other parts, there were small crusts, "where (as a relation said) the bones had worked through the skin."

The peculiar cuticular change was especially marked in front of the axillæ and elbows. There was also a good deal of it about the knees, and over the patellæ and above those bones. The surface felt like that of glass- or sand-paper. It was evident to the naked eye that the change consisted in the presence of a number of fine papilliform processes set side by side. The skin of the abdomen, likewise, felt gritty, as if sand were thinly scattered over it.

The true skin was everywhere much thicker than natural, and was dense and white on section. It was, however, separated by the usual kind of areolar meshwork from the fascia and muscles. The subcutaneous tissue was, indeed, tougher than usual, offering greater resistance to being torn down by the finger. But this appeared to be the result of some physical or chemical change in the elementary fibres, and not (as I had anticipated) to a matting of the parts together. The toughness of the subcutaneous tissue was especially marked beneath the chin. The subcutaneous fat was very scanty, but this was attributed to the imperfect state of the nutrition of the body generally.

The contents of the axilla seemed quite natural, and were not abnormally adherent to one another. But, in removing the organs, the connective tissue was found to be decidedly tougher than usual about the liver, and, perhaps, also in other parts.

The liver itself was much enlarged. It was crossed by a transverse, tight lace fissure. The capsule at the edge of the organ

Digitized by Google

presented a thin projecting border, as if the organ had at one time been still larger and had shrunk. *The tissue of the liver was distinctly hardened*, and it was crisp, making a noise when cut, still more so when torn into pieces. It had a granular fracture. Its cut surface had a peculiar semitransparent look, and was of a red colour, finely mottled in some places with a creamy yellow. Iodine gave no reaction with it. The quantity of connective tissue did not appear excessive to the naked eye. The surface of the liver was not "hobnailed."

The gall-bladder was greatly distended, but could be emptied by pressure.

The spleen was rather small, but firm.

The kidneys were rather large and much congested. Their capsules contained some peculiar patches of delicate yellow mottling. The surface of these organs was slightly granular when the capsules had been removed. The pelvis looked gaping from absorption of fat.

One supra-renal capsule only was noticed; it was perfectly healthy.

The uterus was almost child-like in size and form.

The lymphatic glands in the abdomen and axilla were of natural size.

The lungs were healthy, except that one presented slight ecchymoses. There were also slight adhesions of both bases.

The pericardium was very thin. The heart was healthy. There were slight yellow patches in the lining membrane of the aorta and on the mitral valve. The innermost layer of the coats of the aorta peeled off very readily.

The œsophagus was healthy. The stomach and intestines were not minutely examined.

Portions of the skin from different regions were hardened in chromic acid, and their sections were examined independently by myself and my colleague, Mr. H. G. Howse. He has kindly given me a description of his observations, which I have incorporated with my own.

At those parts where the cuticle was roughened and quasi-ichthyotic, the epidermic scales were found to be arranged in the form of dense conical papillæ, which retained their character in thin sections. In many regions, however, the epidermis was scarcely, if at all, thicker than natural.

Digitized by Google

All the elements of which the corium is composed were increased in amount, viz. the bundles of white fibrous tissue, intermixed with curling elastic fibres, and traversed here and there by fasciculi, broader and larger than natural, of involuntary muscular fibre. Numerous perfectly constructed arterioles supplied the new structures with blood. The bundles of white fibrous tissue were as well defined and as sharply isolated from one another as in healthy skin, crossing in all directions, so that their sections presented every variety of form, circular, elliptical, &c.

"The increased production of areolar tissue had not only affected the corium, but also the underlying superficial fascia. The change had, however, taken place in very unequal degrees in different specimens of skin. In that from the front of the elbow, where it was most marked, a vertical section taken from the surface and extending down to the fascia propria of the muscle showed that the whole of the superficial fascia had disappeared, or rather had become converted into a structure exactly resembling corium. The lobules of fat ordinarily characteristic of it had either entirely vanished, or had become most remarkably atrophied, the individual vesicles being shrunken and evidently far on the road towards absorption.

"It is not very clear how this new formation of white fibrous and elastic tissues originated. But one fact was observed which may, perhaps, throw light on this question. At the deepest part of some of the sections groups of small cells were cut through. They refracted light strongly, and in places were grouped together pretty closely, with but little intercellular material between them. In others, however, they were more widely separated and appeared enlarged, the intercellular material, at the same time, presenting a faint fibrillation. It is probable, therefore, that the cell-element was the structure generating the elastic, and the intercellular material, the white fibrous tissue. Of the origin of the cells themselves I can say nothing.

"In sections of the skin taken from other regions of the body, however, only the superficial parts of the fatty layer had become altered; the deeper parts remained in *statu quo*, giving rise to the naked-eye observation that the skin was separated by the usual areolar layer from the deep fascia."

November 1*st*, 1870.

Digitized by Google

3. *Keloid tumours from the ear.*

By TILBURY FOX, M.D.

THESE tumours, four in number and ranging in size from a small fist to a walnut, were sent from Jamaica by Dr. Izett K. Anderson, and were removed from the ears of negroes. Such growths are very common amongst the negroes, who exhibit what has been termed the "keloid diathesis" in a very striking manner and very commonly. They spring up in the site of the perforations made in the ears for earrings. On section they presented a dense, white, glistening, fibrous appearance, and under the microscope the structure was that of condensed fibrous tissue.

December 6th, 1870.

---

4. *Case of Devergie's pityriasis pilaris.*

By TILBURY FOX, M.D.

THE patient brought before the Society for examination, exhibited the condition originally described by Devergie under the term 'pityriasis pilaris,' in a perfect form, which followed an attack or rather was evolved out of pityriasis rubra. The patient was a man, æt. 49, who had been undergoing a great deal of fatigue in his work as a gunsmith for some time prior to his having been laid up ill. Six months previously he was attached with pityriasis rubra, which within a week from its commencement involved the surface of the whole of the body. The skin was markedly hyperæmic, and threw off continuously, for some time, branny scales and flakes made up of ill-formed cuticular cells. He suffered from "burning heat" in the skin. There was no sign of any discharge. The man got thinner and weaker. The mucous surfaces visible to the eye were injected. The disease remained in *statu quo* for two or three months and began to disappear with the use of rest, good food, cod-liver oil, and steel and quinine, and at the end of six months the

Digitized by Google

appearance of pityriasis pilaris was produced by the interfollicular portions of the skin assuming gradually a healthy appearance, whilst every follicle remained plugged and distended by little whitish hard knots the size of pins' heads, and slightly larger, which gave the surface, in certain parts, the feel and aspect of a rasp or nutmeg-grater. This condition was observed at the back of the neck, all over the back, over the chest, on the outer parts of the arms. In tracing the disease from the lower limbs upwards transitional stages between pityriasis rubra and the pityriasis pilaris were observed. The disease began to break up into patches by the appearance of healthy islets of skin here and there; and at other places there were large red papules freely interspersed with scales covering a congested derma; these red papules getting smaller and smaller and more isolated as they were traced up, till presently a region was reached which was mostly studded over with reddish papules which were seen to be seated at the hair follicle, and to be produced not by effusion into the walls of the follicles but by the distension of the follicles by plugs of epidermis—the epidermis which had desquamated from the lining membrane of the follicle. The condition completely confirmed the truth of Devergie's original description of the disease. It wholly differed from lichen ruber in its mode of origin, its progress, its pathological changes, and the structure of the papules, and the differences were briefly pointed out by the exhibitor. *December 20th*, 1870.

---

5. *Compound pedunculated growths of the skin developed from moles;* A. *Melanotic;* B. *Warty.*

By Frederick Churchill, M.B.

In the fourteenth volume of the Society's 'Transactions,' Mr. Bryant described a melanotic tumour developed from a mole associated with secondary growths in the axilla, abdomen, &c. This is the only instance of mole transformation that I have been able to find recorded in the 'Transactions.'

For the sake of comparison I have associated together under the head of pedunculated growths from the skin, two very distinct non-

Digitized by Google

malignant tumours. Both were developed from moles, both were compound, in neither case was there evidence of similar growths occurring elsewhere.

A. *Melanotic.*

E. W—, æt. 45, had noticed a slight button-like elevation of the skin over one of the lumbar spines from childhood. It was of a dark brown colour, flat and smooth. In July of last year she fell down stairs and injured her back. The mole-like growth which had previously remained stationary now increased rapidly. Two months later the tumour was as large as a grape, prominent and pedunculated. A fine silk thread was twisted around the neck of the tumour, but no attempt was made to strangulate it. The thread was worn for two months when it was removed as it did not check the growth. A thin watery discharge oozed out from the base of the tumour. She also had some pain in it. I advised her to have the tumour removed as soon as possible; and three or four weeks later—February 13th, 1871—she returned prepared to submit to the proper treatment. A wide margin of healthy integument was removed with the growth. The wound was quite healed three weeks after the operation. There has been no recurrence of the growth up to the present time (October, 1871); there was no evidence of hereditary or constitutional disease. The surface of the tumour was rough and nodulated, mottled of a dark gray colour. It was attached to the skin by a very narrow peduncle. It was evidently a more aberrant form of growth than the warty transformation presently to be described, although they were apparently developed from the same structures. Beneath a film of desquamating epidermis the papillated character of the tumour was distinctly visible. The intervening fissures did not extend to the base of the growth, so that the margins of a cut section presented a festooned outline with a fasciculated arrangement of light and dark columns of cells. A vertical section through the centre of the growth showed a radiated arrangement of light and dark bands from the centre to the circumference. The main portion of the tumour had a narrow, well-defined peduncle: there were wart-like growths on the surface. At the base of the tumour there were other distinctly pedunculated growths; these were much darker than the other parts of the tumour—more deeply pigmented.

The radiated arrangement of the structure was due to the alternate arrangement of light and dark bands and columns of cells more

Digitized by Google

or less pigmented; the central part was less pigmented (Pl. VI). The minute structure of the tumour could be more accurately defined by sections taken from this part of the growth. Isolated cells under a Ross's quarter-inch objective were found to present no regular shape, being angular with bright refracting nuclei, many of them undergoing fissiparous development (fig. 3). Some of the cells contained two or three nuclei, and there was also a quantity of granular matter in their interior, especially the more deeply pigmented cells. Some of the cells were arranged in groups. In the lighter parts the cells were more distinct, and the outline more defined. There was a trace of fibrillation in some parts where the cells were less densely packed.

Under low powers the darker columns showed a speckled arrangement of masses of pigment, with intervening light spaces. In some parts the pigment was so dense that there were no light spaces intervening (fig. 2).

B. *Warty transformation.*

This tumour was removed by Mr. Sydney Jones from a patient in St. Thomas's Hospital. I am indebted to that gentleman for giving me the opportunity of describing it in the 'Transactions' and comparing it with the tumour above narrated.

A young woman, æt. 17, had noticed a large flat mole in the left lumbar region. It had existed from birth. She had not noticed anything unusual about it until three weeks before admission, when a thick, dark brown crust peeled off from the surface exposing a warty papillated growth below, projecting from the surface of the integument. The area of the growth was six inches by two and a half. There was some oozing of fluid from between the sulci of contiguous warts. The central growths were larger and more prominent than those at the margin. Portions of the growth were covered by flakes of epidermis. There was a scaly eruption on the buttock of the same side, and she complained of sore throat and frontal headache. There was no evidence of hereditary or constitutional disease, although from the eruption on the skin in the neighbourhood of the growth and the other symptoms syphilis was suspected.

Microscopic examination of the growth showed simple increased development of the ordinary elements of the cutis, with an excess of pigment in the Malpighian layer of the derma. *April 4th*, 1871.

Digitized by Google

Digitized by Google

DESCRIPTION OF PLATE VI,

Illustrating Mr. F. Churchill's Pedunculated Growth from Skin (page 314).

Fig. 1 represents the sectional and surface view of tumour, natural size.
Section through the centre of the growth.
A portion of the tumour showing the outline and the character of the secondary growths attached to the skin by separate peduncles.

Fig. 2 represents a vertical section, the deeply pigmented part (Ross's 1 inch objective).

Fig. 3 represents section and isolated cells, showing minute structure (Ross's ¼ inch).

Digitized by Google

3

2

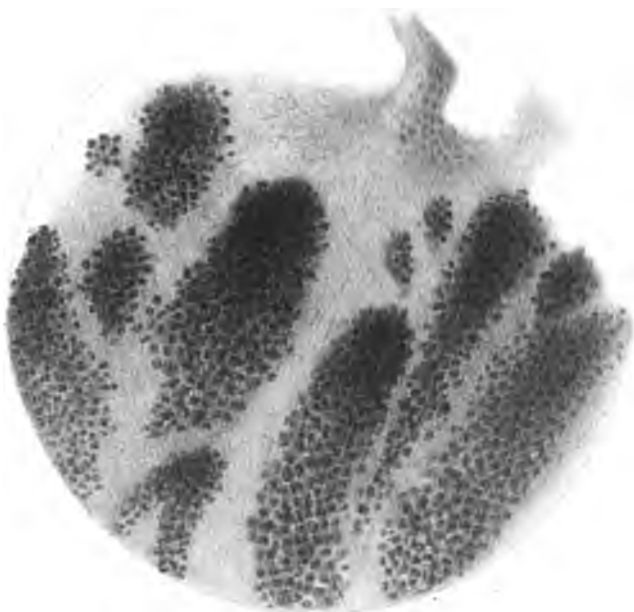

Digitized by Google

Digitized by Google

6. *Effects of ether spray upon the skin in Addison's disease.*

By Frederick Churchill, M.B.

At the previous meeting of the Society, the question was raised as to the nature of the bronzed skin in Addison's disease. Dr. Fagge considered that the increased pigmentation might be fairly attributable to physiological causes. Pathologists consider that the sympathetic system, exercising undoubted control over the functions of the supra-renal bodies, as well as of the circulatory system, have associated the disease of the supra-renal capsules with bronzing of the skin as dependent upon a neurosis of the sympathetic system. No doubt many cases of disease of the supra-renal capsules have been described in which there was no bronzing of the skin, and *vice versâ*. It is generally admitted that the very frequent association of bronzed skin with Addison's disease would make it probable that they must be dependent upon the same cause. Kölliker and others consider the cortical and medullary portions of the supra-renal bodies as functionally distinct. A dense plexus of nerves, derived from the solar and renal plexuses, is found in the medullary portion, so that pathologists now consider it as an apparatus pertaining to the nervous system, while the cortical part is concerned in the elaboration of blood-plasma. Injuries of the spinal cord, in the lower dorsal region, have been found associated with hypertrophy of the supra-renal bodies. The patient on whom this experiment of blanching the skin was tried had injured his back by a fall. If, as supposed, the cortical portion assists in the elaboration of the blood-plasma, under the control of the sympathetic system, it seems reasonable to infer that excessive action of these blood glands would favour increased deposition of pigment when the circulation through the capillaries is embarrassed by imperfect or irregular action of the vaso-motor nerves. Bearing in mind the situation of these bodies outside the peritoneum and close to the floating ribs, it is not unreasonable to infer that injuries to the back might so damage the suprarenal bodies as to cause increased action in these blood-glands, the effect of which might be propagated to the

Digitized by Google

adjacent solar plexus, and thence to the spleen. This well-marked case of Addison's disease was admitted to St. Thomas's Hospital, under the care of Dr. Bristowe, and fully described by him in the nineteenth volume of the Society's 'Transactions.' Those who watched the case from day to day considered that the depth of tint varied very much, and I was anxious to ascertain how far the variation in colour might be due to partial stasis of blood in the venous capillaries. For this purpose I selected a deeply bronzed part in the left flank, and directed a jet of ether spray upon it. A patch of skin the size of a florin was immediately blanched. The partially detached epidermic scales were raised from the surface as white flocculi. The bronzed appearance of the skin returned as soon as the circulation in the part was restored. During the period that the skin was frozen, it appeared as white as the natural skin. Other portions of the skin were also frozen, but this was the only patch that became permanently blanched. The same experiment was tried on a negro, but the skin, though paled, was not blanched. The patient was sent to a convalescent institution, and returned to the hospital in a dying state two months later. The frozen portion of skin had desquamated, including the epidermis with its pigmentary layer, exposing a patch of blanched skin, which appeared to retain all the normal elements except the pigment layer.

In the centre of the blanched patch was a laminated button-like scale of dead epidermis of a dark brown colour, this was probably the crust of epidermis and rete mucosum destroyed by the congealing influence of the ether spray.

The vitality of the skin was not permanently interfered with. There was no appearance of inflammation about the patch, and no cicatrix formed. The rugæ were all well marked, and it resembled in every particular the surrounding integuments except in the almost entire absence of pigmentation. The palest part was in the centre of the patch. Probably the bronzed appearance would have returned in the patch had he lived long enough. Microscopical examination of the skin showed a gradual deposition of fresh pigment at the margins.

Thin vertical sections through the edge of the blanched patch, examined by a quarter-inch objective satisfied me that at the time of death the patch was not entirely deprived of pigment. It is probable that during the few remaining weeks of his lifetime, the disease progressing, the deeper layers of the epidermis were under-

Digitized by Google

going the usual process of pigment deposition. The appearance of the cut section and the naked-eye appearances of the skin immediately after the experiments will favour the conclusion that this deposit had taken place recently.

There was but a trace of pigment in the rete mucosum, which was of a pale buff colour and very diffused. The microscopic examination also satisfied me that there had been no destruction of the cutis. The epidermic layer was of the usual thickness throughout. It would have been more satisfactory to have made a section through the centre of the patch, but this was objected to.

June 20th, 1871.

Further to elucidate the effects of extreme cold upon vascular textures I would refer to Mr. Simon's article on "Inflammation," from which I have taken the accompanying extract:—"The modus operandi of cold in its power of producing inflammation may be best illustrated by some experiments I performed in March, 1860. Having occasion in hospital practice to make some issues, I used, in three cases, an application of solidified carbolic acid . . . . the skin almost instantly became so frozen as to ring like metal. In from fourteen to twenty minutes after the application had ceased, the frozen textures had completed their thaw. Blood re-entered them. . . . . Inflammation presently set itself up in the surrounding parts, but the part on which the cold had acted remained without signs of life, and in due time, having meanwhile *suffered no inflammation*,[1] nor recovered any sensibility, underwent separation as a slough. Beyond a limited range of operation the agencies of textural excitement and the agencies of textural depression become indiscriminately the agencies of textural death."—Holmes' 'Surgery,' vol. i, p. 54.

[1] Italics not in original.

Digitized by Google

XI. MISCELLANEOUS.

1. *Fungus-foot of India.*

By Tilbury Fox, M.D.

Dr. Tilbury Fox stated that he had not made any examination himself as yet of this specimen, which in its external characters presented all the features of mycetoma in a well-marked form, as he thought it would be more satisfactory to the Society if so valuable a specimen were placed at its disposal unmutilated for careful examination by a committee. There was nothing peculiar in the history of the case calling for special remark. The foot had gradually enlarged, presently sinuses opened over its surface at different parts, and discharged black matter. It was removed by Mr. Wright, of Guntoor. Dr. Shortt, of Madras, kindly procured and sent the specimen to England. *November* 1*st*, 1870.

Report on Dr. Fox's Madura foot.—The foot, exhibited by Dr. Tilbury Fox, was much swollen, and presented numerous openings on the surface like those commonly connected with sinuses from diseased bone. On making an antero-posterior vertical section, it was found that the soft tissues generally were thickened and indurated, and traversed by sinuses communicating on the one hand with the openings above mentioned, and, on the other hand, with cavities which had once been occupied by the smaller bones of the tarsus, and which, for the most part, retained the general form of these bones, being bounded and separated from one another by dense fibroid material—in part, doubtless altered periosteum.

The cavities were filled with masses of a nearly black, dense, dry, friable substance, which readily broke into small fragments (those from the surface being, for the most part, rounded or botryoidal, those from the interior being more or less fibrous), and which on section were found to be paler, and at the same time redder in the

Digitized by Google

interior than on the surface. The masses certainly presented some resemblance to truffles, but it seemed also at first not improbable that they were wholly or in part blood-concretions.

They were difficult to investigate microscopically on account of their great brittleness and great opacity. With a low power of the microscope the superficial portions of the masses were seen distinctly to present (fig. *a*) a dendritic character, the nodulated, ginger-root-like branches radiating from the more homogeneous but fibrous

WOODCUT 29.

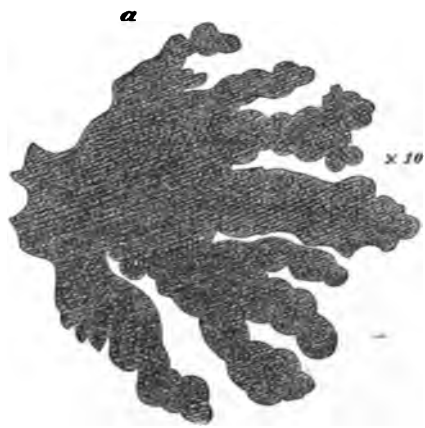

Fragment from circumference of truffle-like body.

material of the interior. This peculiarity of arrangement suggested rather a growth than a concretion.

With higher powers of the microscope crushed or teazed-out fragments of the masses were found to vary in hue and opacity, some presenting a yellow, orange, or mahogany tint, others the colour of sepia or of Indian ink; some had an angular or conchoidal fracture, others displayed a more or less distinct fibrous arrangement. The fibrous portions (which, as before stated, were found chiefly in the interior) were not at all easy to investigate. Here and there thin flat fibres, varying in width, and connected more or less with one another, were found projecting from or running by the side of thicker, longitudinally arranged masses, and these latter not infrequently presented irregular longitudinal markings, due either to fungus-tubes running along them or to irregular longitudinal

Digitized by Google

fractures. Here and there distinct mycelial tubes could be seen projecting from the edge. The lobulated superficial portions presented partly the same characters as have just been described; but, for the most part, they displayed a central opaque core, surrounded by a comparatively thick envelope, presenting a radiating fibrous arrangement (fig. *b*). The core seemed to be formed of deep orange-coloured, transparent, polyhedral bodies; the envelope looked in many cases as if it were formed of fungus-tubules, and in some cases numerous such tubules could be seen projecting from the surface. Further examination showed these tubes to be exceedingly abundant; many fragments of them could be seen floating about the field of the microscope, many could be seen projecting from the edge of the opaque lumps which were under

WOODCUT 30.

b

Minute lobule, more highly magnified.

inspection, and, although in many cases it was impossible to recognise anything of the kind, it was quite obvious that they formed an essential and characteristic feature of the morbid masses.

The tubes here adverted to varied in size and in character. In diameter they ranged, for the most, between $\frac{1}{4000}$ and $\frac{1}{8000}$ inch. In some cases they were more or less cylindrical, with here and there indistinct constrictions and septa; in other cases they were formed of elongated, round or irregular, non-nucleated cells, irregularly strung together. And in all cases there was a remarkable tendency for them to send out branches in various directions. The mycelial tubes

Digitized by Google

were sometimes remarkably transparent and delicate; in other cases they presented a more or less deep orange or sepia tint, which seemed then chiefly to occupy the walls. The colourless tubes were generally of small size; the coloured ones varied in size, but included all the larger ones, and often their parietes were remarkably thick. The large coloured tubes, indeed, seemed, for the most part, if not entirely, to occupy the substance of the coloured masses of fungus, and the idea suggested itself that the fungous masses might be due

WOODCUT 31.

Mycelium, &c., of fungus.

to accumulations of these thick-walled tubes separated from one another, and blended into a mass by a coloured outgrowth or exudation from their walls.

Floating about in the field of the microscope were usually observed considerable numbers of orange-coloured, transparent, rounded bodies of small size. Some of these consisted of the united segment of two spheres, others were made up of several such segments blended so as to form botryoidal or mulberry-like masses. They seemed to be of the same nature as the polyhedral bodies above adverted to as

Digitized by Google

forming in some cases the core of rounded masses, and had probably been set free by the fracture of these masses.

Various methods were adopted to render the examination of the truffle-like bodies more satisfactory, but, for the most part, without advantage. At length fragments were boiled in liquor potassæ, and the result of this process was most remarkable. The liquor potassæ dissolved the colouring matter, and tended finally to remove it entirely, and at the same time it softened the brittle masses and rendered them easy of manipulation. Fragments thus treated showed, on microscopic examination, that the fungus-tubes were infinitely more numerous than had been suspected; that, in fact, the whole growth was essentially formed by their accumulation (figs. *c* and *d*); that the central fibrous parts, as well as the superficial nodulated outgrowths, consisted of densely aggregated ramifying tubes, separated from one another only by homogeneous, intertubular colouring matter, and that the radiated character presented in drawing (*b*) was due to the radiated arrangement of these tubes. From incompleteness of action of the liquor potassæ in the specimens examined, while some portions were wholly deprived of colour, in others the colouring matter in a molecular form seemed to have accumulated in an undue degree within the tubes themselves, so that they were rendered in some cases quite black and opaque.

The peculiarities of the tubes, as above described, were remarkably well shown in specimens thus prepared; but it was further shown that the tubes had a tendency in many cases, especially if not solely at the ends of branches, to become dilated into large round or oval, thick-walled cells (fig. *e*, *e*), varying from $\frac{1}{500}$ or $\frac{1}{600}$ to about $\frac{1}{2000}$ inch in diameter, and that these cells had a tendency to occupy certain regions in which they were grouped in large numbers. I believe that the polyhedral masses indistinctly shown in the drawing (*b*) consist of these cells, enclosing contents which have been dissolved out by the liquor potassæ. I believe, further, that these thick-walled cells are the cells within which the spores are produced; and I suspect that the rounded, mulberry-like masses previously described are the contents of these cells, or the spores.

Dr. Thudichum was kind enough to submit the truffle-like material to spectroscopic examination, and found that it did not present the absorption bands of any form of hæmatine. He furnished me also with the following brief report of its chemical characters:

"A small quantity of a grumous black matter was submitted to

Digitized by Google

examination. From its appearance it might have been mistaken for dried and altered blood or hæmatine; but it proved to be insoluble in all reagents, whether dilute or concentrated, including caustic potash and oil of vitriol. On combustion it left a small quantity of ash, which contained a little iron oxide, but much less than it would have contained if the matter has been altered blood. I am therefore inclined to believe that the matter is not condensed blood, nor proximately derived from it or from hæmatine, but is of a different nature. The small quantity of material did not admit of any further experiments."

WOODCUT 32.

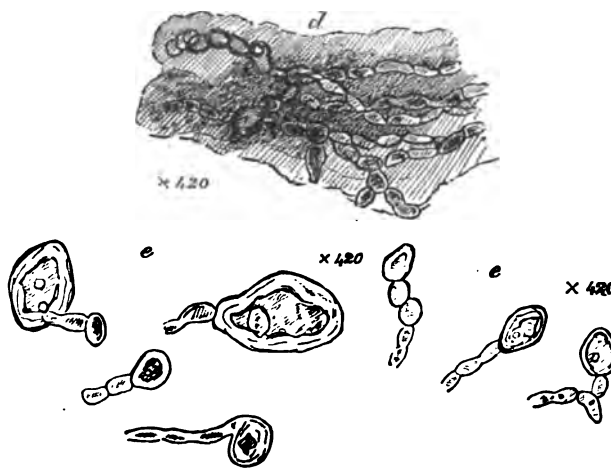

Mycelium, &c., of fungus.

The fungus above described is evidently identical with that figured and described by Dr. Vandyke Carter, and certainly it has some resemblance, both to the naked eye and microscopically, to the ordinary truffle. That is to say, both of them consist of jointed tubules imbedded in a dark-coloured intercellular matrix, and of comparatively large thick-walled rounded cavities budding off from these tubes. But in the truffle these cavities contain two, three, four, or more largish, oval, dark-coloured, prickly bodies, while in the foot-fungus the nature of the contents of these cavities is not very easy to determine; there was reason, however, to believe that

Digitized by Google

they contain the transparent brownish botryoidal bodies before adverted to.

I do not attempt in this report to give any opinion as to the botanical position of the fungus of the Madura foot, or to decide whether the fungus is the cause of the bone disease, or a mere consequence of it. I venture to remark, however, that the black masses seem to be as truly a fungus as do masses of truffle, and not merely inspissated secretions which have become invaded by a growth of fungus; but I must add, on the other hand, that I failed to detect any traces whatever of fungus in the diseased foot previously exhibited by Dr. Tilbury Fox, a foot which, but for the absence of the black masses, appeared to be diseased in precisely the same way as the foot to which this report relates.

May 16*th*, 1871. J. S. Bristowe.

---

2. *Cases of rodent ulcer.*

By J. W. Hulke.

Case 1.—A laundress, æt. 70, was admitted into the Middlesex Hospital, in July, 1865, with a large and deep ulcer in the left side of the face, which had begun as a pimple twelve or fourteen years before. It had destroyed the lateral cartilages of the nose and perforated its septum, and it had also spread outwards towards the cheek, reaching from the lower eyelid to the attached border of the upper lip. The base and the margin of the ulcer, for about the thickness of two lines, were hard. The discharge was thin and scanty. Glandular infection and cachexia were both absent.

She was a hale, wiry woman, and, so far as she knew, none of her relations had had cancer. I excised the ulcer, cauterized the exposed bone, and coated the whole wound with chloride of zinc paste. The eschar separated slowly, and by the time it fell fully one third of the wound had cicatrized. In the following November she returned to Devonshire with a healthy scar.

The minute structure of the morbid tissue forming the hard edge

Digitized by Google

and base of the ulcer, its mode of extension, and its relations to the normal tissues are represented in the annexed sketch.

WOODCUT 33.

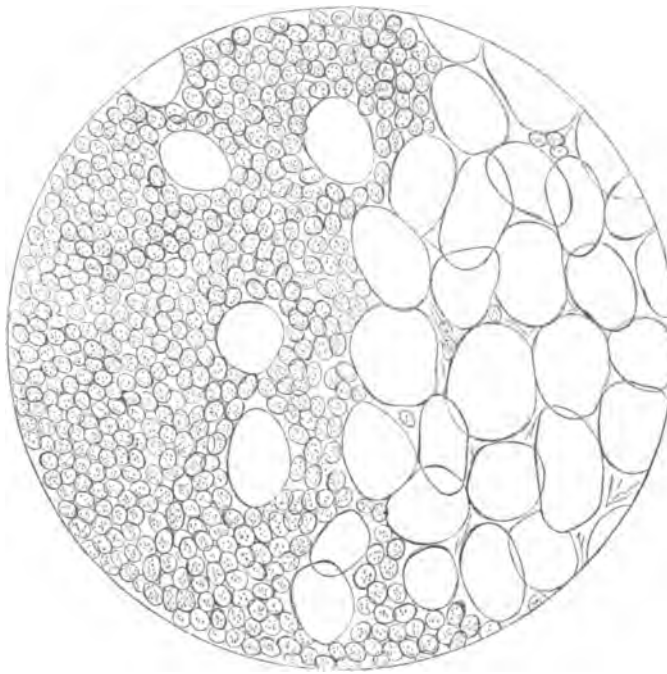

A new growth of cell-tissue roughly comparable with that of the rete mucosum, infiltrating the subcutaneous fatty tissue. × 240.

It consists exclusively of cells without the admixture of an intercellular substance. The cells are small and round; they resemble those of the epidermal rete mucosum. At the periphery of the hard edge and base they form cylinder and bud-like masses which intrude into the normal tissues underlying the ulcer. Near those invading buds the connective-tissue corpuscles are unusually numerous, and in some situations appearances indicating proliferation of these corpuscles and evolution of the morbid tissue out of them were observed.

Digitized by Google

CASE 2.—A farm labourer, æt. 53, was admitted into the Middlesex Hospital, June 5th, 1866, with an ulcer of the cheek of several years' duration. It measured about one inch across, and had an irregularly circular outline. Part of its edge was indurated,

WOODCUT 34.

a. The neoplasm infiltrating muscular tissue.
b. Proliferating connective substance.
c. Outbuds of the neoplasm into the connective tissues at the outskirts of the hard edge of the ulcer. × 240.

uneven, and undermined, and part had the appearance of a thin recent cicatrix. The floor of the ulcer was uneven, smooth, and glossy, and dotted sparingly with small groups of pale granulations. The lower eyelid was dragged slightly down and everted. There was not any indication of enlargement of the lymphatic glands.

The ulcer was excised. The patient left the hospital unknown to

Digitized by Google

me during the autumn vacation, and was readmitted some months later under the care of the late Mr. Moore, with a renewal of the ulcer. The lymphatic glands continued unaffected.

The minute structure of the morbid material forming the indurated front of the progressive border of the ulcer is shown in the accompanying sketch. The principal elements are small spherical cells about the size of those of the deeper layers of the rete mucosum which closely agrees with what had been observed in previous cases. Amongst these, near the surface of the ulcer, were sparingly found epithelial scales. The corpuscles of the common connective tissue were more numerous than they normally are.

CASE 3.—A laundress, æt. 60, a remarkably healthy looking, strong, active woman, was admitted into the Middlesex Hospital in May, 1864, with a large and deep, almost painless, ulcer of the chin, which had laid bare and eroded the body of the lower jaw. It measured 3 by 2½ inches. The edge was hard and uneven. The bottom of the ulcer on the right side was formed by the dry, brown, necrosed surface of the jaw, and on the left it was composed of an indurated tissue coated with patches of rather exuberant granulations, around which the ulceration was advancing rather less tardily than elsewhere. An offensive, yellow, puriform discharge oozed from around the necrosed bone, but that which extended from the rest of the ulcer was thin, scanty, and nearly inodorous. There was no infection of the lymphatic glands and no cachexia.

The necrosed bone was gouged away, and the ulcer was excised and cauterized, with the result that the wound healed soundly except at the right side where the bone had been involved, and where, I suspect, some of the morbid tissue had escaped destruction. At this stage the woman left the hospital against my advice, and did not return till nearly eighteen months afterwards.

She told us that the ulcer had existed for five years before I first saw her, and that it began in a small wart, which remained seven years unbroken before the time she first noticed it.

The tissue forming the hard edge of the ulcer closely resembled that observed in the preceding case. Active proliferation of the connective-tissue corpuscles was also noticed; and for some distance beyond the palpably hard base the fibres of the facial muscles were separated by cell masses, some of which had apparently their origin in these corpuscles. *January 17th*, 1871.

Digitized by Google

CASE 4.—Mary M—, æt. 69, was admitted into the Middlesex Hospital, August 24th, 1870, with an oval deeply excavated ulcer in the cheek, measuring about half an inch in its long diameter, just below the lower edge of the left orbit. Its edges were slightly thickened and hard, and they were undermined. It yielded a thin, serous, not puriform, discharge. Evidence of glandular infection and of cachexia were both absent. She said that she had had from birth in the situation of the ulcer a small red pimple, which had never troubled her, except by occasionally bleeding, until five years ago, when without any apparent cause it began to fester.

I excised the ulcer, and coated the wound with chloride of zinc paste. By the time the eschar fell off, its area had greatly lessened, and in September she left the hospital convalescent.

A section through the ulcer, after it had been hardened in alcohol, showed that the thickened edge and base consisted of a heterologous corpuscular or cell-tissue resting on and invading the subcutaneous fatty layer by intruding itself along the connective stroma between the fat-cells. Between the coarser bundles of the common connective tissue forming the wider meshes of the deepest layer of the cutis, and also amongst the bundles of the facial muscles, large masses of small, round, and roundly-oval cells, having a somewhat glandiform arrangement, were present. From the deeper structure, columns or streams of cells becoming progressively longer and larger, and approaching more the type of a subcolumnar epithelium, ascended to the surface of the ulcer. The papillæ of the cutis and its sweat and sebaceous glands in the neighbourhood of the ulcer were notably enlarged.

CASE 5.—Wm. T—, a smith, æt. 52, was admitted into the Middlesex Hospital, in December, 1867, with an ulcer of the right cheek, of very long duration. Its area measured 4 inches by 2½ inches, and it extended from near the angle of the mouth to below the lobe of the ear, laying bare the body and part of the ascending ramus of the lower jaw. At one spot it perforated the buccal mucous membrane. The ulcer had a sharply-defined, sinuous, hard edge, varying from 2 to 3½ lines broad, abrupt but not tuberous. The base also was thickened; parts of it were smooth and glazed, other parts were dotted with minute hard granulations. It exuded a thin, scanty, inodorous discharge. No enlarged lymphatic glands

Digitized by Google

were discoverable, and there was not any cachexia. My late colleague, Mr. Moore, considered it an example of rodent ulcer.

I excised the ulcer, and cauterized the wound with the hot iron and with chloride of zinc paste. February 17th, 1868, he returned home with an apparently healthy scar, and in the following June, when I next saw him, there was no sign of the return of the disease; but in October of the same year, however, a very small ulcer having similar features to the primary one happened near the front of the cicatrix. At this time he still did not exhibit any indication of glandular infection or cachexia.

WOODCUT 35.

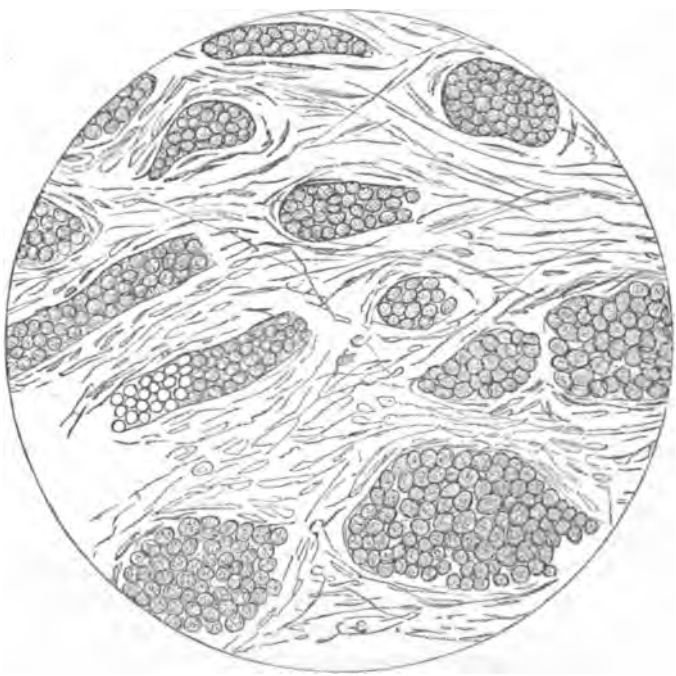

Section through the indurated tissue bounding the ulcer. It shows the outbuds of the neoplasm and proliferation of the nuclei of the connective substance. × 240.

The minute structure very closely resembled that of the preceding case. It is represented in the accompanying drawings.

February 7th.

Digitized by Google

3. *Two cases of pyæmia.*

By J. F. Payne, M.B.

1. *Case of pyæmia with cutaneous affection, resulting from the passage into a vein of softened caseous matter from a scrofulous lymphatic gland.*

A. S—, æt. 31, was admitted into St. Mary's Hospital, November 21st, 1870, under Dr. Sibson's care. On November 22nd, his complexion was dusky, the body covered with a fine rash, and on the face, viz. at external corner of left eye and right ala of nose were superficial ulcers. The left knee red, tense, and swollen. He complained much of pain in the joints, and was very delirious. The tongue rough, slightly brown in the centre, red and pitted at the edges; pulse 122; first sound of the heart loud and vibrating; respirations 29; temperature 103·8°F.

Nov. 23rd.—Delirium worse; ulcerations on face increasing; pupils more dilated; breath offensive; pulse irregular, about 132; respirations 22; temperature 104·8°.

24th.—Ulcerations on the face discharging a greenish very unhealthy-looking pus. Pulse 130; respirations 33; temperature 100·8°; urine acid, albuminous; spec. grav. 1014.

He died on the 26th; the delirium continuing and the ulcerations on the face becoming deeper.

Post-mortem examination forty-five hours after death.—Body rather thin; rigor mortis well marked. On the face were some deep ulcerations, partly covered with crusts, and most marked at external angle of left orbit and left ala of nose. Under these patches was found excavation and purulent infiltration of the skin for a considerable area, and beyond this the skin was soaked with turbid reddish serum. The left knee-joint was found distended with pus; the right knee was natural. No other joints were opened. There was no other wound or external sign of injury.

The *lungs* were found pale in front, and with hypostatic congestion behind. In upper lobe of right were two or three nodules the size of a pea, containing puriform matter, and also a few old hard

Digitized by Google

nodules of the kind called scrofulous. The lower lobe was engorged and almost in condition of hæmorrhagic infarction, but did not sink in water. The left lung was generally like the right.

Heart quite natural and containing ordinary post-mortem coagula, continuous with those in pulmonary artery and large veins. The blood in the pulmonary veins was liquid; that in the pulmonary artery and venæ cavæ coagulated in the ordinary way, with the exception described below.

Just at the junction of superior vena cava and innominate vein was a mottled thrombus adherent to the walls, and partially softened in the centre. On removing it some white matter was found adherent to it behind, and on examination this was found to proceed from a collection of similar matter situated behind the vein and communicating with it by a distinct opening about one eighth of an inch in diameter, out of which, when pressure was applied, the putty-like matter came freely. The white mass was enclosed in a firm fibrous investment and was evidently a bronchial lymphatic gland converted into a caseous mass by so-called scrofulous inflammation, and this had at length produced ulceration of the wall of the vein. No other gland was in a similar condition. The vein in the neighbourhood looked quite natural, and all the principal veins were carefully examined without finding anything but ordinary post-mortem coagula.

The remaining thoracic and abdominal viscera presented nothing worthy of note.

In the head there was noticed some thickening of the dura mater covering the petrous portion of the left temporal bone, and there was enlargement of the bone itself; while from the inner surface of dura mater grew some small calcified tumours, of which the largest was the size of half a pea. The corresponding portion of the cerebrum, namely, the temporo-sphenoidal lobe, was wasted, and its substance much altered, being yellow and sclerotic.[1] Otherwise the brain, its membranes and vessels were quite natural.

Microscopical examination of the softened caseous matter in the scrofulous gland, showed it to consist of fatty molecules, indefinite granular matter, and some rather larger granules, but no cells. A great part of it dissolved in dilute acids and was probably calcareous.

[1] The patient had been subject to epileptic fits.

Digitized by Google

2. *Case of pyæmia with peculiar cutaneous affection; softened thrombus in cerebral vein and sinus.*

STEPHEN S—, æt. 18, an anæmic youth, was admitted into St. Mary's Hospital, January 7th, 1870, under Dr. Sibson. When admitted he stated that some weeks before he had caught a severe cold at work, and was laid up; when recovering from this he caught cold again, and had been ill ever since. He complained of great weakness and there was some œdema of the ankles, but no other marked symptom is recorded and he improved steadily for the first week in hospital. In the second week the left knee became swollen and painful, and there were signs of fever. There was, however, a second period of improvement till the 27th January, when the following symptoms are recorded:—Skin dry and harsh; face pale and anxious; pupils dilated; tongue tremulous and red; abdomen contracted; some dyspnœa; pulse 132; temp. 103°F. On the 29th a puffiness was noticed on the left side of the face, which afterwards went on to suppuration. After this the temperature went from 103° to 104°, and the pulse from 140 to 160 in the minute. There followed delirium which passed into stupor; sordes on the teeth; stertorous breathing; and the patient died unconscious on February 2nd; twenty-six days after admission.

Post-mortem examination eighteen hours after death.—Body thin; ankles and knees slightly swollen. On opening ankle-joints they were found to contain pus; the other joints were not opened. On the left cheek over the malar bone was a suppurating ulcerated patch, some three inches in diameter, covered with yellow crusts, and the skin around was excavated by suppuration. In the chest there were indications of incipient pleurisy, but the lungs were quite normal, with the exception of some obsolete caseous or scrofulous matter in apex of right. The heart contained ordinary clots and some liquid blood. The remainder of thoracic and abdominal viscera natural, except that the kidneys were actively congested and the spleen large. The whole mucous surface of intestines was quite natural.

In the head the longitudinal sinus of dura mater was found to contain beside an ordinary loose post-mortem clot, a pale, mottled, crumbling coagulum, firmly adherent to the right wall of the sinus in its anterior portion. This coagulum was continuous with a similarly mottled mass which extended for about three-quarters of an inch into a small vein

Digitized by Google

opening into the sinus, and proceeding from the arachnoid covering the right cerebral hemisphere. This vein was greatly distended by the clot (which had evidently undergone some transformation) and enlarged to perhaps three times its original size. Two other similar veins contained similar but not decolorized coagula. The inner surface of the dura mater over the right hemisphere was covered with a thin, soft, translucent false membrane, with many hæmorrhagic spots. The arachnoid and pia mater were not inflamed or congested. The corresponding portion of dura mater on the left side was affected in the same way, but not so universally. The inflammation on both sides extended through the membrane, producing some roughness on its external surface. The brain itself was perfectly natural, and the remaining veins and sinuses (as well as those of other parts of the body) contained ordinary post-mortem coagula.

Microscopic examination of the clot in the cerebral vein and sinus showed no true pus, but the ordinary constituents of a softening blood clot, viz., leucocytes and molecular fibrin with fat, &c. The false membrane on the dura mater was ordinary inflammatory lymph without many corpuscles.

Remarks.—These two cases have certain features in common. In both were cases of pyæmia without any external injury, or what has been called idiopathic pyæmia, and in both there was suppuration of the skin, a complication not unknown in this disease, but certainly far from common. In each case the low febrile or typhoid condition, the peculiar persistency of the inflammation of particular joints, and other symptoms, lead the physician in charge to make the diagnosis of pyæmia, notwithstanding the superficial resemblance to rheumatism. As to their origin, there was, however, a marked difference between the two cases.

The first case presents the following special features of interest:

1. It is probably a unique instance of the effects of introducing directly into the blood the material which is the result of the so-called scrofulous inflammations, and is therefore worth comparing with the supposed action of the same or similar matters in inducing acute tuberculosis.

2. It is noticeable that the first effect of this seems to have been to produce local coagulation of the blood; and the breaking down of the coagulum, thus formed, as it coincided with the production of pyæmia was probably a link in the causation of that disease.

Digitized by Google

3. Since the principal manifestations of pyæmia were in the systemic circulation, the lungs being affected in a very slight degree, it would seem that the poison producing suppuration, whether by capillary embolism, or in any other way, must, at all events, have been of sufficient tenuity to pass through the pulmonic capillaries without producing any considerable blocks. It must then have been either liquid, or, more probably, very finely divided solid matter. The caseous or scrofulous matter itself being in the form of the finest possible emulsion, would be precisely of this kind; but material from a softened coagulum might, perhaps, be in the same physical condition. The possibility of solid particles, fine enough to pass through the pulmonary circulation, producing capillary obstructions in distant parts, has been sufficiently shown by O. Weber. It must, however, be admitted that the production of articular inflammations is, perhaps the least understood phenomena of pyæmia, since they have never yet been produced by experiment.

In the second case also there was a complete immunity of the lungs, together with several simultaneous articular inflammations. The origin of blood-poisoning in this case could hardly be anything else than the softening thrombus contained in a sinus of the dura mater; but what led to the formation and breaking down of this thrombus is difficult to say; nor was it obvious whether it was antecedent or subsequent to the inflammation of the internal surface of dura mater, which was also present. There was no history of injury or any indication of such a cause. *January 17th*, 1871.

---

4. *Cysts containing air from the peritoneum.*

By J. F. Payne, M.B.

The patient from whose body these specimens were taken was a man, æt. 26, who was admitted into St. Mary's Hospital, under Dr. Handfield Jones's care, on September 9th, 1870, and died on October 4th. He was suffering from unmistakable symptoms of pyloric obstruction. The stomach was enormously distended, there

Digitized by Google

was constant vomiting of yeasty matter containing sarcinæ, and there was much pain. He had once brought up a large quantity of blood. There was nothing to cause any suspicion of any other affection.

At the *post-mortem* examination the body was found to be thin, but not excessively emaciated; no rigor mortis; no sign of decomposition (twenty-three hours after death). The lungs and heart, liver, spleen, and kidneys, were natural. In the right side of the heart, and in the principal veins, *i. e.*, the venæ cavæ, iliac, jugular, &c., were ordinary soft black coagula without any sign of decomposition. The stomach was very large, touching the abdominal walls on both sides. It contained about 32 ounces of fluid and a great deal of air, but could be made to hold 160 ounces of fluid. Its walls were fairly thick, and the mucous surface generally healthy; but close to the pylorus or the lesser curvature was an ulcer as large as a sixpence. It was of the kind called ordinary round ulcers, but was very deep, having destroyed both the mucous and the muscular coat, and had an indurated base composed of fibrous tissue. There was considerable muscular hypertrophy round, and it had by its contraction narrowed the pyloric orifice, which hardly admitted the tip of the little finger. The walls of the pylorus were thickened, but there was no cancer or other morbid growth. The peritoneum contained no fluid or air, and was in itself normal, but presented at several parts clusters of cysts containing air, looking like large imprisoned bubbles. Their general appearance was something like branches of grapes, or, more precisely, like masses of uterine, so-called "hydatids" or like cysts of the fimbriated extremities of the fallopian tubes. The largest single cysts were the size of a hazel-nut and some were as small as a pin's head. They were mostly attached to a single peduncle from which they hung freely, but some were connected with loops as if two had become united. Some quite similar structures contained coagulated blood instead of air; but even in these, hollow spaces were found on section. These structures were not seen on the duodenum or jejunum, nor on the upper two feet of the ileum, but occurred in groups, or occasionally singly through the greater part of the ileum down to the valve, a few minute structures only being found on the cæcum. They were generally situated on the serous covering of the intestine and on the neighbouring part of the mesentery. A very few minute bubbles were seen on the parietal peritoneum. The part of intestine round these growths was generally congested, and in some parts showed signs of extravasation.

Digitized by Google

On the mucous surface, in the same parts as the cysts, were seen small round elevations about one eighth of an inch in diameter, which on examination proved to be bubbles in the intestinal walls completely covered by the mucous layer and in some cases by the muscular coat. Connected with these were whitish, irregular, ramified ridges, which also contained air and appeared to be lymphatics. These bubbles could not be forced into the cysts outside. There was absolutely no ulceration or perforation of the mucous surface. These bubbles and air-containing vessels became much more numerous towards the lower end of the ileum, but none were seen in the colon. There was no other disease of the intestines to be detected.

Closer examination of the cysts showed them to be definite structures composed of fibrous tissue; they collapsed on being pricked, and when flattened out had a leaf-like shape. Under the microscope they showed a beautiful connective-tissue structure, with no cancerous or heterologous appearance. The air coming from the cysts was kindly examined for me by Dr. Russell for oxygen, nitrogen, and carbonic acid. The two former were found to be in the proportion—

Nitrogen	94·2
Oxygen	5·8
	100·00

The carbonic acid could not be accurately determined, as the preparation had been kept wet, but it was certainly more than 2 per cent., and probably a good deal more.

Remarks.—The occurrence of air in various parts of the body was at one time thought to be a much commoner event than it is now admitted to be, and was spoken of as a well recognised morbid process under the name of pneumatosis. Lately much doubt has been thrown upon the very existence of this process. Many cases, such as the presence of air in the meninges, the pericardium, the mediastinum, are now known to be explicable by the entrance of air during the examination. In the pleura it is generally admitted that air can only come from the lungs; in the peritoneum, for the immense majority of cases, only from the intestines; actual liberation of air being generally admitted only as the result of the decomposition of sanious pus or similar matters. We have a right then to regard with the greatest suspicion all cases of apparently spontaneous production of air, and to exhaust as far as possible other explanations before

Digitized by Google

resorting to that of actual generation of gas. Professor Gross, of Philadelphia, is perhaps the latest writer who recognises "the production of air or gas as the result of vital causes, or in other words, of a process of secretion not unlike that of serosity, lymph, or pus." But the only experimental instances which he quotes are those of the liberation of gas from an isolated portion of blood in the aorta (which is natural enough) and from the contents of a portion of intestine enclosed between two ligatures (which is also not difficult to explain), so that the doctrine of secretion of air is still without solid support.

It must be admitted, however, that it is not always easy to explain the origin of gaseous accumulations, and the obscurity of cases such as these gives them an interest not in proportion to their pathological importance.

In seeking an explanation of the phenomena of the case now brought forward several hypotheses have been considered. In the first place, could the gas have been derived from ordinary putrefaction? This hypothesis was negatived by its composition and by the entire absence of putrescent odour in this or any other part of the body, as well as by its being contained in definite cystic structures. Nor could it have been liberated from the blood by any ordinary post-mortem change, for the blood in other parts of the body, though carefully examined, did not show a trace of gas.

The hypothesis of secretion could not be entertained; and, finally, the composition of the gaseous mixture itself being, as it was, virtually atmospheric air, with a deficiency of oxygen and a considerable excess of carbonic acid, naturally suggested the idea that it was atmospheric air introduced from without, and altered by its sojourn in the tissues. Since there was no possibility of entrance from the external surface of the body, it could only have been derived from some part of the intestinal canal. According to the accurate and classical researches of Planer, the gases of the large and small intestine consist of nitrogen, hydrogen, and carbonic acid, with sometimes a very small proportion (less than one per cent.) of oxygen. The gases of the stomach, on the other hand, consist normally of carbonic acid, nitrogen, and sometimes a considerable proportion (in one case six per cent.) of oxygen, but no hydrogen.[1] The difference is explained

[1] Planer, 'Sitzungsberichte der Wiener Akademie, Mathem. Naturwiss. Classe, 1860, Bd. xlii, p. 307, quoted in Funke, 'Lehrbuch der Physiologie,' 4te Auflage, Bd. i, p. 321.

Digitized by Google

by the fact that the gas contained in the stomach is chiefly atmospheric air conveyed into it with saliva or food, and partly deprived of its oxygen; no normal development of gas taking place there. The composition of the gas in this case agrees with that of the stomach, and differs from that of the intestines, in so far that it contained a notable proportion of oxygen; the presence or absence of hydrogen not having been ascertained. In searching for any opening by which air might have been admitted to the subserous tissue, the mucous surface of both small and large intestine was found, as has been said, absolutely intact; but there remained the pyloric ulcer, and it became necessary to consider whether air contained in the stomach might possibly have insinuated itself by this opening. The ulcer was certainly deep enough, passing, as it did, through the mucous and muscular coats; and further from its position (considering the large amount of air contained in the stomach during life), it must have been frequently above the level of the gastric fluid, and exposed, by the distension of the stomach; to considerable pressure; so that there must have been a tendency to separate the fibrous floor of the ulcer from the muscular coat of the stomach and pylorus. It is also easy to see that had any air thus insinuated itself it must have passed on into the intestinal walls where there was no pressure, rather than have remained involved in the walls of the distended stomach. A difficulty, however, is at once presented by the fact that no air was found in the walls of the duodenum, jejunum, or upper part of the ileum. But the peristaltic movements of the bowel must almost certainly have carried the emphysematous bubbles onwards; and the distance of the collections of air from the stomach may simply have corresponded to the time which had elapsed since the air was introduced. The collection of the cysts into clusters would also be explained in the same way; for, supposing that the air got into the intestinal walls at all, it would have done so not constantly, but at intervals, when the stomach happened to be specially distended. That the air did not pass beyond the termination of the ileum into the cæcum, must have been due to a firmer attachment of the intestinal walls at that point, or possibly to some peculiarity in the arrangement of the lymphatic channels, since it was evident from the appearances described above that the air was in the ileum partly contained in the lymphatics. Another question remains unsolved. Were the cysts which contained the air of independent formation, or were they produced in any way by the emphysematous bubbles?

Digitized by Google

Against the first view it must be urged that cysts of the peritoneum are hardly known; nothing of the kind is mentioned in the standard text-books, and, even were there such structures preexisting, it would be more remarkable still that air should pass into them from the subserous tissue of the peritoneum and displace or remove their other contents.

There was, indeed, one fact which lent a certain degree of plausibility to such a supposition, viz. that while most of the cysts contained simply air, there were others, similar in all other respects, which contained blood: there were also some in which both air and blood were present. Either, then, the air-cysts were subject to hæmorrhage, or in cavities originally containing blood, air had been produced by decomposition. Another case may be quoted in illustration. Dr. Green has described (in 'Path. Trans.,' xx, p. 173) a case of cyst-like cavities containing blood, situated between the peritoneal and mucous coats of the small intestine; and giving the portion of intestine involved the appearance of a bunch of grapes. *Mutatis mutandis*, the description would apply very well to the specimen now under consideration. Even were it assumed, however, that the cystic structures themselves originally contained blood, and that subsequently air was produced there, this hypothesis would not account for the bubbles and ramifying vessels filled with air, which were seen projecting on the mucous surface; and it is difficult to avoid the conclusion that the air was itself in some way the cause of the production of the cystic structures. Unless by the supposition of some unexplained pneumatosis or spontaneous production of air, the air can only be conceived of as having arrived at this situation through the gastric ulcer.

There is one case recorded in the Society's 'Transactions' which lends some support to this view. It is that of emphysema of the peritoneum in a man who died of melanosis of the œsophagus, exhibited by Mr. De Morgan for Mr. G. Fleetwood Bury, and described in vol. xviii, p. 107. The following description is given of the melanosis of the œsophagus:

"The disease of the œsophagus extended nearly through its entire length. It was thickened, and was studded especially on the surface with black deposit. The peritoneum was nearly universally studded with air-vesicles, but more especially the diaphragmatic portion, where the vesicles were larger and more numerous: some of them were nearly as large as a cherry. The contained air was free from

Digitized by Google

odour, and there was no sign of decomposition in any part of the body. No opening could be detected, nor was there any transudation of any of the intestinal contents nor of the food." The autopsy was made on the third day after death, in cold weather, at Christmas. Although in this case there is no mention of ulceration of the œsophagus, I presume it is unlikely that such extensive cancerous disease should have existed on a mucous surface without ulceration, or, at least, such a brittleness of the mucous coat as would have readily produced rupture. Under these circumstances air might have been forced between the coats, perhaps during vomiting, and would have produced emphysema, especially of the adjacent diaphragmatic portion of the peritoneum.

This is the only similar case which I have been able to find where the production of air was distinctly shown to have had nothing to do with decomposition. As is well known, a kind of post-mortem emphysema is not an uncommon phenomenon in putrefaction. Professor Gross, of Philadelphia, speaks, however, in his 'Elements of Pathological Anatomy' (p. 587, 3rd edition), of having noticed "the formation of little vesicles produced by the presence of air in the subserous cellular tissue" in peritonitis, and speaks also elsewhere of pneumatosis as occurring in the subserous cellular tissue of the peritoneum, without specifying the supposed cause. We cannot suppose that so experienced an observer was not alive to the possibility of fallacy from post-mortem phenomena; but it is singular that this condition should have escaped the notice of other observers. The most precise parallel is, however, presented by some classical specimens of gaseous cysts in the Hunterian museum, of which it has been said[1] that they "should be admired or rather venerated, for their histories include the honorable names of Hunter, of Jenner, and Cavendish," a list to which we should now add the name of the author of the 'Surgical Pathology.' The description of these specimens originally given in Hunter's 'Observations on the Animal Economy,' and the accompanying figure in the quarto edition of that work,[2] agree precisely with the specimen now exhibited; and it is most interesting to find that more exact analysis strengthens the resemblance. The result of the analysis by Cavendish of the air from Hunter's specimen,—that "it contained a little fixed air, and the remainder not at all inflammable and almost completely phlogisti-

[1] Paget, 'Surgical Pathology,' 2nd edition, p. 398.

[2] Hunter's Works, collected edition, vol. iv, p. 98, and description of pl. xxxvii.

Digitized by Google

cated,"—is, when translated into the language of modern chemistry, essentially the same as that of Dr. Russell's examination of the present specimen. By "a little fixed air" Cavendish meant certainly more carbonic acid than is contained in the atmosphere; that it was not inflammable, refers to the absence of hydrogen; if "almost completely phlogisticated," it contained only a small proportion of oxygen. Of these points, then, two, at least, are common to both specimens, and are, as has been shown, consistent with the hypothesis that the gas was atmospheric air, in which the oxygen was diminished and the carbonic acid increased. The history of Hunter's specimens is given as follows: "I have a piece of the intestine of a hog which has a number of air bladders in it." . . . . "It was sent to me by my friend Mr. Jenner, surgeon at Berkley, who informed me that this appearance is found very frequently upon the intestines of hogs that are killed in the summer months."

Whether hogs are particularly liable to ulceration of the stomach or bowels which might permit of a subperitoneal emphysema, I am unable to say; but no explanation of the origin of the air is given by Hunter himself, or suggested by his commentators.

January 17*th*, 1871.

---

5. *Supposed case of smallpox at time of birth.*

By Henry G. Sutton, M.B.

A well formed and well nourished body of an eight or nine months' infant. On the face are a number of spots about the size of shot. Some of them are of a dark red colour, and depressed below the surrounding surface, and abruptly circumscribed. This colour is evidently due to blood extravasated. The spots vary in size, and are most numerous in the lower half of the face.

Besides these there are other spots, which are covered with a grayish-yellow elevated crust.

In some of the red spots pale centres are seen depressed below the surrounding skin. Similar spots are seen in the skin over chest, abdomen, and lower extremities.

Digitized by Google

Pleura.—There is evidence of recent pleurisy over the lower parts of both lungs. The serous membrane is dull, opaque, granular, and coated with a very thin layer of recent lymph. This recent pleurisy is confined to an area of about the size of a sixpenny-piece, and is situated immediately over one of those circumscribed yellow bodies which appear to be the remains of pustules. There is also a little similar recent pleurisy on the costal pleura, and it is situated over one of the yellow bodies which had formed in the cartilage of one of the ribs.

Lungs.—On looking at the surface of the lungs a number of circumscribed yellow bodies are seen about the size of duck shot. These bodies are depressed below the surface. When cut into they are seen to consist of a soft yellow substance of the consistence of cream cheese. This yellow matter is very circumscribed, and readily shells out, leaving a very thin transparent sac. These bodies vary in size, and are situated immediately under the pleura. There are similar bodies on the thymus gland, and two minute collections of pus in this gland.

The microscope shows that these bodies consist of a number of pus-like corpuscles, fat granules, and dark granular matter. Similar yellow bodies are seen in the ribs, as already mentioned above, near their surfaces immediately beneath the periosteum. When cut into they present the same appearances as the yellow bodies seen in the lungs.

Surrounding these yellow bodies is a dark red, hæmorrhagic-looking substance. The yellow bodies situated in the intercostal regions are surrounded by effused blood, corresponding in many respects with the crushed bodies, and the bodies in both situations were surrounded by similar blood effusion.

Pericardium healthy. Peritoneum healthy.

Several minute yellow bodies are seen in the liver immediately under the peritoneum. These bodies present the same appearances as those in the lung.

Kidneys healthy; spleen healthy. Stomach and intestines normal.

The yellow substance forming the bodies in the lungs consisted of granular matter, of fat granules, and dark granules. The so-called fat-granules were aggregated in masses in some parts. Besides this granular matter there were a number of irregular-shaped corpuscles, which contained a quantity of granular matter. The corpuscles were about the size of pus-corpuscles. Some of them were larger and some smaller than ordinary pus-corpuscles.

Digitized by Google

Clinical history.—The mother had been vaccinated in infancy, and had scars on the arms. She had not seen any one, as far as she and her friends knew, who had smallpox. She had been an out-patient of the London Hospital for cough for a short time before her confinement. She had not been feverish. No history could be elicited, either from her or her husband, of syphilis. When the child was born it had the eruption over the body, which did not undergo much alteration during its life. The child lived two days.

The mother was carefully examined, but there was not the slightest evidence that she had then, or at any previous time, had smallpox. *December 20th*, 1870.

Report on Dr. Sutton's case of supposed smallpox at the time of birth.—We have examined the fœtus exhibited by Dr. Sutton, which was supposed to have presented evidence of smallpox at the time of birth. We find that the eruption in the same portions of skin has all the appearances of successive evolutions, some large and obvious cicatrices being interspersed with recent pustular elevations. In this and other minor characters, such as the form of the cicatrices, the eruption, in our opinion, differs from that of smallpox. The opaque patches in the lungs appear to be identical with those of ordinary pyæmia, and having no specific characters, do not, we think, support the view of the variolous nature of the disease. Further, there is no evidence that the mother had smallpox at any time of her life.

Although the characters of the cutaneous eruption are not sufficiently definite to enable us to say positively what it is, yet the eruption and the morbid patches in different organs suggest some common constitutional cause.

CHARLES MURCHISON.
H. CHARLTON BASTIAN.

May 16th, 1871.

Digitized by Google

6. *A hand completely flayed by machinery.*

By George Lawson.

Mr. George Lawson exhibited a hand which he had amputated at the Middlesex Hospital on account of the following extraordinary injury it had received from machinery. The boy was engaged feeding a paper-rolling machine, when his hand was caught between the rollers, which were sufficiently close to grip the skin without seizing fast hold of the hand. Instead of the hand and arm being drawn in between the rollers and crushed, the skin was torn as if by a clean cut just above the wrist, and drawn off from the hands and fingers as far as the last phalanges, to which it remained attached, and from which it hung like an inverted glove. Several of the phalanges were considerably crushed. The preparation is now in the Museum of the Middlesex Hospital. *April* 18*th*, 1871.

Digitized by Google

XII. SPECIMENS FROM THE LOWER ANIMALS.

1. *Ruptured stomach of dog.*

By Richard Davy.

A terrier was run over, while micturating, by a surgeon's cab. One large and many small rents were found at the posterior aspect and lesser curvature of the stomach, through which the contents (about half a pound of meat and garbage) had passed into the peritoneal cavity.

The dog died in an hour from internal hæmorrhage.

November 15*th*, 1870.

---

2. *Lungs and heart of a porpesse.*

By William Ogle, M.D. (introduced by Dr. Whipham).

Dr. William Ogle exhibited the lungs and heart of a porpesse, with the following remarks:

"The specimen came from a porpesse, which Dr. Cavafy and I dissected recently, and in which all the parts excepting those now exhibited were in the normal condition of health. The lungs are studded with hard nodules, some of which lie superficially just below the pleura, while others are deeply imbedded in the substance of the organs. These nodules were at first supposed to be tuberculous; but on opening the trachea and bronchi, I found a vast number of nematoid worms occupying the right and left bronchus, and extending down the secondary bronchial tubes. These worms were so numerous that the right bronchus was completely blocked with them.

Digitized by Google

On cutting across the supposed tuberculous nodules, I found the centre of each occupied by a similar worm, which had plainly made its way down the smaller bronchial tubes and coiled itself up in the lung substance, where its presence had caused induration of the surrounding tissue.

None of the worms were to be found in the stomach, nor in the intestine. It appears probable, therefore, that they had made their way into the air-passages from without through the blowhole on the top of the head.

The worms are each about as thick as a large darning needle and six or seven inches in length. They are not perfectly cylindrical, but somewhat flattened, presenting, however, no trace of segmentation. I shall be glad if any member of the Society can give me any information as to the species of nematoids to which they belong.

The heart also presents an interesting anomaly. It is bifid at the apex, each ventricle having a distinct point. This peculiarity was much more marked in the fresh condition of the organ than it is now that the organ has shrivelled to a considerable extent. It is well known that in all mammalia at a certain period of embryonic life, namely, that which follows the appearance of the ventricular partition, the heart presents a similar bifid condition at its apex. But in most mammalia this condition is a temporary one, the dugong and other sirenia alone furnishing exceptions; the organ retaining its bifid character permanently in these animals.

A similar abnormal condition of the heart has already been noticed as occurring occasionally in the porpesse by Meckel ('Anat. Com.,' ix, 382), and once he noticed a similar occurrence in a seal.

It is remarkable that this bifid condition of the heart, whether normal as in the sirenia, or exceptional as in the porpesse and the seal, has never yet been found in any but aquatic mammalia. It is difficult to see any connection between this structural peculiarity and aquatic life. Perhaps it may be nothing more than an accidental coexistence. One cannot, however, but suspect that some hidden correlation may exist; and I would suggest that the arrangement may possibly give greater force to the ventricular contractions; which would clearly be of advantage to animals whose bodies are subjected to great external pressure, and where consequently there is an increased hindrance to the circulation. *December* 20*th*, 1870.

Digitized by Google

3. *Growths in the larynx of a dog.*

By Morell Mackenzie, M.D.

The history of the case was as follows:—

Dash, æt. 3½ years, a cross-breed of lively disposition, enjoyed good health till the spring of 1870, when it was noticed that his bark was weak. The bark grew more feeble in the summer, and in the autumn his respiration became difficult, especially when he underwent exertion or was excited, or when he passed from a warm into a cold atmosphere. In these attacks his inspiration was stridulous, as in child-crowing; and he always lay flat on his belly, with his head stretched straight out, resting on the floor. He became much thinner and weaker towards the end of the year; and in December a veterinary surgeon who was called in said that "the lungs were so extensively diseased that little remained of them." As the case was hopeless, he prescribed hydrocyanic acid. On *post-mortem* examination the lungs were perfectly healthy, but several neoplasms were found completely blocking up the subglottic region; one of these, the size of a small bean, was situated at the posterior part of the left vocal cord, and a smaller one was seen on the same part of the right vocal cord; there was also a fringe of very minute growths along the ventricular bands. On microscopical examination the growths were found to consist of minute granular cells, probably epithelial cells undergoing degenerative metamorphosis.

This specimen is believed to be unique, though there are examples of laryngeal growth in the horse and cow in the museums of Dresden and Fribourg, and there is one specimen of a growth in the larynx of a horse in the museum of the Royal Veterinary College, of London. There is little doubt, however, that if these growths were searched for in the larynx of dogs they would be frequently found.

As the foregoing case reflects somewhat unfavorably on the veterinary art, it is only fair to observe that in two of the cases occurring in animals, and referred to by Ehrmann, the situation of the obstruction was accurately diagnosed during life, and that

Digitized by Google

tracheotomy was successfully performed. It may also be added, that at the time those animals were operated upon no case had been recorded in which tracheotomy had been performed in the human subject on account of a laryngeal growth. *February* 21*st*, 1871.

---

4. *Specimens of cataract, and of opacities of the cornea, in the lower animals.*

By Edwards Crisp, M.D.

I exhibit seven specimens of hard cataract from the lower animals, in spirits, with several examples of cataract in wax, and several of opacity of the cornea, which I have imitated in animals affected with these lesions.

The specimens of cataract in spirits, are from the Bear, Lion, Wolf, Dog, Goat, and Harnessed Antelope. Those in wax, from the Chacma, and Baboon, Cebus Monkey, Lemur, Civet Cat, Kangaroo, Wombat, Heron, Curassow Turkey, and Goose. The opacities of the cornea are in the Lion, Sambur Deer, Goat, Boa Constrictor, Glass Snake, Pike, Perch, and Roach.

The cataracts in spirits are all hard; in three, the lens is altered in shape, of a dirty amber-like colour, and the capsule thickened; in the other specimens the lens is white and opaque, but not much altered in form. In the antelope, as shown by the cast and drawing, the eye is of a pointed form (conical cornea), the lens hard, and of a very irregular shape; the conjunctiva very vascular, with large vessels extending over the transparent cornea.

In this communication I confine myself to cataract and to opacities of the cornea. For several years I have examined the eyes of our domestic animals, and foreign animals in confinement, for the purpose of studying the colour of the iris, and the abnormal conditions of the eye structures. On two occasions, after an interval of four years, I have examined the eyes of nearly all the animals at the Regent's Park Gardens, and taken drawings and notes of the diseases of these organs. I have, moreover, had many opportunities

Digitized by Google

of inspecting diseased eyes after death. On this occasion, as I before observed, I speak only of cataract and of opacity of the cornea: as regards the latter affection, it is remarkable that it is not of more frequent occurrence, considering the injuries to which the eyes of some of the rapacious animals especially are exposed; but the beautiful provision furnished by means of the nictitating membrane in quadrupeds and birds, will serve in a great measure, to explain the exemption. The opacities of the cornea that I have met with do not appear to have been the result of mechanical causes, as far as I could ascertain. Among fishes, opacities of the cornea and muddiness of the *liquor morgagni* are often due to entozoa, as was well shown by Nordmann many years since. Fishes, such as the Perch, Pike, and Carp, when kept in close places, with a limited supply of water, are very liable to these opacities from the cause named.

Cataract.—Among our domestic animals, the horse is far more liable to this lesion; and, strange to say, that whilst in man it is generally a disease of advanced life, in this animal it occurs at an early period. Close, ill-ventilated stables with the abundant exhalation of ammonia, and badly regulated light, are probably the main causes. Next to the Horse, the Dog is most subject to cataract; the Hog too is not unfrequently affected. Sheep are sometimes blind from this cause; but I think, judging from the inquiries I have made among flock masters, that the disease is not very prevalent among Sheep in the southern and eastern counties. Youatt, however, in his work on the 'Sheep,' p. 406, says that in exposed, cold districts it is very prevalent, and the right eye is more frequently affected than the left." Our domestic birds are but rarely troubled with this lesion.

Among foreign animals in confinement, the Lemurs are far more frequently affected with cataract than the Apes or Monkeys. I have seen many examples among the former, and a few only in the Monkey. At the present time, there is a Cebus monkey at the Regent's Park Gardens that performed for twelve years in the London streets, that is blind from a cataract in each eye. But among foreign animals in confinement, the marsupials are more liable to cataract, Kangaroos, Wombats, Dasyures, and Opossums especially. The Wombat is seldom long in confinement without losing the sight of one, or both eyes from cataract. Among the (so-called) carnivora, the Bears (chiefly vegetable feeders) are most liable to cataract. Of sixteen of these animals now at the Regent's

Digitized by Google

Park Gardens, four have cataract. I believe in the purely animal feeders it is far less prevalent, although I have seen it in the Lion, Tiger, Wolf, and Civet cat. Among the larger pachyderms and ruminants, the disease is less frequent, judging from the few examples afforded. Among the rodents I have met with a few cases. Foreign birds in confinement are seldom blind from this cause. In reptiles in confinement I have seen several opacities of the eye, but whether from cataract or opacity of the cornea I have been unable to determine during life. There is one circumstance worthy of notice, that night animals (such as the marsupials) that have the lens proportionately large, are more frequently blind from cataract. I have made extensive observations respecting the relative size of the eye to the body in different mammals, birds, and reptiles, and of

WOODCUT 36.

The above sketches that I have taken represent—1. Cataract in the Bear. 2. Harnessed Antelope. 3. Kangaroo. 4. Heron.

the relative weight of the lens to the eye. In man, the lens forms the proportion of about $\frac{1}{30}$ to the eye; in the quadrumana the proportion is nearer to that of man; in the Lion $\frac{1}{70}$, but in some of the small night-feeding carnivora the lens is very large, as it is in many of the rodents; in the marsupiata it is also large—thus, in the Kangaroos about $\frac{1}{5}$ the weight of the eye; in the Tasmanian devil (D. ursina) it is more than $\frac{1}{4}$ the weight of the eye; in the larger ruminants and pachyderms it varies from $\frac{1}{60}$ to $\frac{1}{20}$; in the Elephant it is $\frac{1}{18}$. I think that animals with a large crystalline lens are more subject to cataract: but I speak guardedly upon this point.

But what practical deduction can be drawn from the above? Unfortunately from the present limited state of our knowledge, but

Digitized by Google

little useful information can be gained; but hereafter, when diseases of the lower animals are better understood and more minutely investigated, much practical good may result from more extensive investigation. There is one fact, I think, established, viz. that vegetable feeders are more liable to cataract: whether the amount of saccharine food has any influence in the production of this opacity when it occurs spontaneously, I am unable to say. As is well known, Craigie, von Gräfe, Richardson, and others have traced the connection between cataract and diabetes, but I am unable to discern that any of the animals in question had saccharine urine; indeed, I fail to find a single suspected case of diabetes in any of the animals since the establishment of the Gardens: but the disease is very likely to be overlooked. There is this fact, however, that is indisputable, that most animals with cataract, appear to be in good health, and live for many years. *May* 16*th*, 1871.

Digitized by Google

APPENDIX.

History, by Dr. Sieveking, of the case recorded by Dr. Payne, p. 283.

MRS. W—, æt. 60 (in 1870) first came under my care in 1866 for a febrile attack with hepatic congestion and dyspepsia. She had at that time a slight enlargement of the thyroid, but this was stated to have been larger formerly, and caused no uneasiness. I saw her frequently from that time, and she suffered from various apparently neuralgic attacks affecting different parts of the body. In the month of March, 1867, she had what appeared to be a slight attack of laryngitis, with croupy breathing; she recovered from this, but every now and then, up to the time of her last illness, she had stridulous breathing. Her last severe illness came on after a visit to Dover during the cold weather of January, 1870; from that time the stridulous breathing was persistent, and dyspnœa set in, which became increasingly severe, and was relieved by none of the remedies that were suggested. The speaking voice, at the same time, though at times feeble, remained clear almost to the last. It was evident that the vocal cords themselves were not the seat of mischief. Dysphagia also supervened, and increased gradually up to the time of death; still a certain amount of liquid food was always taken, almost to the last, and no marked emaciation resulted. Excepting that there was slight bronchitis, no organ of the body appeared to be involved, and it is especially to be mentioned that no further enlargement about the neck and no tumour in the thorax could be traced. Consciousness was retained to within a few hours of death, which appeared to result from the increasing dyspnœa rather than from actual inanition. Mrs. W— died on the 29th June, 1870.

Digitized by Google

INDEX.

Abdominal parietes, biliary fistula in, discharging bile . . . 152
„ ditto, gallstones discharged by . 154
Abdominal walls, papillary growth of 229
Absorbent Glands, diseases of 287-304
Adams (Mr. J. E.), congenital dislocation of wrist 197
„ large and multiple exostoses of the skull with hyperostosis . . 204
„ fracture of head of radius . 205
Adams (Mr. W.), hard fibrous tumours of the palate 272
„ *report* on, by Mr. H. Arnott . 273
Addison's disease, see *Supra-renal capsules.*
Air, cysts containing, from the peritoneum 336
Allbutt (Dr. Clifford), on the changes of the spinal cord in tetanus . 27
„ *report* on ditto by Dr. L. Clarke and Dr. W. H. Dickinson . . 31
Alopecia, general, with microscopic specimens of the hair and nails 305
Andrew (Dr.), see *Committee* on Lardaceous Disease.
Aneurism of the arch of the aorta bursting into the œsophagus . . 102
„ of the thoracic aorta, cured popliteal aneurism 100
„ of abdominal aorta, which had burst into peritoneal cavity . . 104
„ of the coronary artery . . 106
„ ditto, table of cases . . . 109
„ of a branch of the pulmonary artery in a phthisical lung . . 37
„ double subclavio-axillary . . 111
„ dissecting, of the arch of the aorta 113
Aneurism, sacculated, of the arch of the aorta; simulating aneurism of the innominate 95
Animals, specimens from the lower 347-353
Aorta arising equally from the two cavities 88
„ rupture of, and tumour of brain 115
„ aneurism of, see *Aneurism.*
Aphasia, in case of scirrhus of brain and breast 261
Aponeurosis of subscapular muscle 194
Appendix vermiformis, concretions in perforation, fatal peritonitis . 146
Arachnoid, extravasation of blood beneath, in caries of vertebræ, &c. 188
Arnott (Mr. H.), cancer of imperfectly descended testicle, with thickened peritoneum 182
„ scrotal tumour, hæmorrhage into cellular tissue, &c. . . . 184
„ malignant osteoid tumour of fibula 214
„ epithelioma of heart and lungs secondary to that of clitoris . 231
„ epulis tumours of the jaw . 256
„ soft cancer of the female breast 264
„ *report* on Mr. W. Whitehead's case of peculiar sputum . . 84
„ *report* on Dr. Whipham's case of columnar epithelioma of the liver 169
„ *report* on Mr. De Morgan's case of lymphadenoma of the axilla . 242
„ *report* on Mr. T. Smith's case of cystic tumour of breast with calcareous degeneration . . 268
„ *report* on Mr. W. Adams's case of hard fibrous tumour of the palate . 273
„ aneurism of, see *Aneurism.*

Digitized by Google

Arteries, carotid, embolism of, sudden death 119
,, common carotid, death by perforation of, in cancer of œsophagus 134
,, left middle cerebral, embolism of 13
,, pulmonary, atresia of the orifice and trunk of 85
,, pulmonary, great contraction or stenosis of 88
,, subclavian, ligature on right side for aneurism 111
,, vertebral, embolism of, sudden death 119
Ataxy, motor, spinal cord from a case of 14
Atrophy of the cerebellum . . 20
Axilla, fibro-cystic tumour from . 233
,, lymphadenoma of 236
Axis, dislocation of, in caries of the vertebræ 192
Bastian (Dr.), *report* on Dr. Sutton's case of supposed smallpox at the time of birth 345
Beck (Mr. M.), spindle-celled sarcoma connected with the posterior tibial nerve 18
,, myeloid tumour of the head of the tibia 210
Bennett (Dr. Risdon), intra-thoracic growth, enlarged thymus; Hodgkin's disease or lymphadenoma 70
,, — autopsy and microscopical examination by Dr. Sutton . . 73
,, secondary scirrhous or fibro-cancerous infiltration of connective tissue of lungs, &c., primary cancer of mamma removed . . . 76
,, — microscopical examination by Dr. Sutton 80
,, *report* on ditto, by the Committee on Morbid Growths (Dr. Bristowe and Mr. Pick) 82
Biliary fistula in abdominal parietes, discharging bile 152
,, ditto, gall-stones discharged by 154
Bladder, diseases of . . 171–181
Blood, extravasation of, beneath arachnoid in caries of vertebræ, &c. 188
Blood-vessels, diseases, &c., of 85-127
Bones, diseases, &c., of . 188-217
Bone, gunshot injuries of . . 199
Bony deposit in the eye . 225, 226
Bowels, see *Intestines.*
Brain, tumour of, in a case of rupture of aorta 115
Brain, venous vascular tumour of . 22
Breast, primary cancer of, removed 76
,, soft cancer of the female . . 264
Breast, tumour of 230
Bristowe (Dr.), cancer involving pharynx, larynx, neighbonring lymphatic glands and lungs . 132
,, cancer of œsophagus, free communication between œsophagus and trachea, death by perforation of common carotid, paralysis of left vocal cord 134
,, cancer of stomach, liver, lungs, lymphatics of the thorax, &c., and paralysis of larynx . . . 137
,, *report* on Dr. R. Bennett's case of secondary scirrhus of the lung 82
,, *report* on Dr. Moxon's case of osteo-colloid tumours 210
,, *report* on Dr. Payne's specimen of tumour of thyroid 286
,, *report* on Dr. Dickinson's tumour of the lumbar glands . . . 293
,, *report* on Dr. Dickinson's mesenteric tumour 302
,, *report* on Dr. T. Fox's case of fungus or madura foot of India . 320
,, see *Committee* on lardaceous disease.
Bronchial tubes, extension of diphtheritic membrane to . . . 35
Bronchitis, &c., death from, in subclavian aneurism 111
Bronchocele, cancer of thyroid body, subsequent to 283
Cæcum, see *Appendix vermiformis.*
Calcareous degeneration of scirrhous carcinoma 267
Calculus, biliary, passed from the umbilicus 157
,, — jaundice from, and acute atrophy of the liver, &c. 159
Cancer, facts as to the general diffusion of 260
,, primary of mamma removed . 76
,, of the œsophagus, with fistulous opening into the trachea . 129
,, — free communication between œsophagus and trachea, &c. . 134
,, involving pharynx, larynx, lymphatic glands, and lungs . . . 132
,, of stomach, liver, lungs, &c., and paralysis of larynx . . . 137
,, of imperfectly descended testicle 182
,, of thyroid body, subsequent to bronchocele 283
,, of the tongue, and simple stricture of the œsophagus . . . 128
Cancer, see *Tumours.*
,, medullary, of liver, lungs, and left kidney 171
,, osteo-colloid, of the skeleton . 206

Digitized by Google

Cancer, scirrhous, with calcareous degeneration 267
„ soft, of the female breast . . 264
Cancerous growths on endocardium, in liver, lymphatic glands, &c. . 125
„ see *Scirrhus*.
Cancrum oris, death from . . 85
Carcinoma, scirrhous, with calcareous degeneration 267
„ see *Cancer*.
Caries of vertebræ, causing ulceration of transverse ligament, &c. . . 188
„ — with dislocation of the axis . 192
Cataract in the lower animals . 350
Cayley (Dr.), *report* on Dr. Murchison's case of paralysis agitans . 25
„ *report* on Dr. Whipham's case of columnar epithelioma of the liver 169
„ *report* on Mr. De Morgan's case of lymphadenoma of the axilla . 242
„ *report* on Mr. T. Smith's case of cystic tumour of breast with calcareous degeneration . . 268
Cellular tissue, hæmorrhage into, in scrotal tumour . . . 184
Cerebellum, atrophy of the . . 20
Cheek, cystic epithelioma of . . 262
Cholesterine in lardaceous liver . 5
Chordæ tendineæ, destruction of, in a case of pleurisy . . . 117
Chorea in a case of sudden death from embolism 119
Church (Dr.), *report* on Dr. Moxon's case of osteo-colloid tumours . 210
„ *report* on Dr. Walker's case of spindle-celled recurrent sarcoma of the leg 246
„ *report* on Mr. Sp. Watson's cystic epithelioma of the cheek . 263
Churchill (Mr. Fred.), compound pedunculated growths of the skin developed from moles (melanotic and warty) 314
„ effects of ether spray upon the skin in Addison's disease . . 317
Circulation, organs of, diseases, &c., of 85–127
Clapton (Dr. E.), atrophy of the cerebellum 20
Clarke (Dr. Lockhart), *report* on Dr. Allbutt's cases of changes of the spinal chord in tetanus . 31
Clitoris, epithelioma of . . . 231
Colitis, phlegmonous . . . 139
Colloid cancer, osteo-, of the skeleton 206
Colon, fistulous communication of gall-bladder and 158
Committee on Lardaceous Disease, report of . . . 1–12
Committee on Morbid Growths, reports of.
„ on Dr. R. Bennett's case of secondary scirrhus of the lung (Dr. Bristowe and Mr. Pick) . . 82
„ on Dr. Whipham's case of columnar epithelioma of the liver (Dr. Cayley and Mr. H. Arnott) . . 169
„ on Dr. Moxon's case of osteo-colloid tumours (Dr. Bristowe and Dr. Church) 210
„ on Mr. Morris's case of sarcoma of the fibula (Dr. B. Sanderson and Dr. Green) 214
„ on Mr. De Morgan's specimen of lymphadenoma of the axilla (Dr. Cayley and Mr. Arnott) . . 242
„ on Dr. Walker's case of recurrent tumour of the leg (Dr. Church) 246
„ on Mr. Wagstaffe's cystic sarcoma of the lower jaw (Mr. Sibley and Mr. Hulke) 252
„ on Mr. West's tumour of upper jaw (Mr. Hulke and Mr. Sibley) . 256
„ on Mr. S. Watson's case of cystic epithelioma of cheek (Dr. Church) 263
„ on Mr. Thomas Smith's case of large cystic tumours of breast (Mr. Arnott and Dr. Cayley) . . . 268
„ on Mr. W. Adam's case of fibrous tumour of palate (Mr. Arnott) 273
„ on Dr. Payne's specimen of tumour of thyroid (Dr. Bristowe and Mr. Pick) 286
„ on Dr. Dickinson's tumour of the lumbar glands (Dr. Bristowe and Mr. Pick) 293
„ on Dr. Dickinson's mesenteric tumour (Dr. Bristowe and Mr. Pick) 302
Concretions in appendix vermiformis, perforation, fatal peritonitis . 146
Cooke (Mr. Weeden), facts as to the general diffusion of cancer . 260
Cornea, peculiar deposit on the . 225
„ opacities of, in the lower animals 350
Corpus striatum, yellow induration of, with surrounding white softening 13
Cranium, large and multiple exostosis of, with hyperostosis . . . 204
Crisp (Dr.), aneurism of the coronary artery 106
„ ditto, table of cases . . . 109
„ cancer of the tongue and simple stricture of the œsophagus . 128

Digitized by Google

Crisp (Dr.), fatal hæmorrhage from simple ulcer of the stomach . . 141
„ general alopecia, with microscopical specimens of the hair and nails 305
„ specimens of cataract and opacities of the cornea in the lower animals 350
Croft (Mr.), aneurism of the thoracic aorta, cured popliteal aneurism 100
Crucknell (Dr.), malformation of gall-bladder and hepatic duct . 163
Cyanosis in a case of atresia of the pulmonary artery . . . 85
„ in a case of stenosis of the pulmonary artery . . . 88
„ in a case of malformation of the heart 92
Cysts containing air from the peritoneum 336
„ see *Tumours*.
„ ovarian, see *Ovarian*.

Davy (Mr. R.), destructive and reparative processes in two hip-joints 198
„ ruptured stomach of dog . . 347
Dr Morgan (Mr. C.). large lymphoma in the pectoral region . . 236
„ *report* on ditto by the Committee 242
Deposits, puriform, in acute atrophy of the liver 159
Dickinson (Dr.), tumour of the lumbar glands 287
„ *report* on ditto by Dr. Bristowe and Mr. Pick 293
„ mesenteric tumour . . . 296
„ *report* on ditto by Dr. Bristowe and Mr. Pick 302
„ *report* on Dr. Allbutt's cases of changes of the spinal cord in tetanus 31
„ *report* on Dr. Hawkes' case of rupture of aorta 116
„ see *Committee* on Lardaceous Disease.
„ see *Liebreich*.
Digestion, organs of, diseases, &c., of. 128-170
„ — a. Tongue and digestive canal 128-151
„ — b. Liver . . . 152-170
Diphtheria, case of, with extension of the membrane to the bronchial tubes 35
Diseases, &c., of the nervous system 13-32
„ of the organs of respiration 33-84
„ of the organs of circulation 85-127
Diseases, &c., of the organs of digestion 128-170
„ — a. Tongue and digestive canal 128-151
„ — b. The liver . . 152-170
„ of the genito-urinary organs 171-187
„ — a. Kidneys, bladder, &c. 171-181
„ — b. Genital organs, male 182-185
„ — c. Ditto, female . . 186,187
„ of the osseous system . 188-217
„ of the organs of special sense 218-228
„ — a. The eye . . 218-228
„ — b. The ear . . . —
„ tumours 229-273
„ of ductless glands . . 274-304
„ — a. The spleen . . 274-279
„ — b. Supra-renal capsules 280-283
„ — c. Thyroid . . 283-286
„ — d. Absorbent glands . 287-304
„ of the skin . . . 305-319
„ miscellaneous specimens . 320-346
„ specimens from the lower animals 347-353
Dislocation of the axis in caries of the vertebræ 192
„ of the head forwards, in caries of vertebræ, &c. . . . 188
„ congenital, of wrist . . . 197
Dog, larynx of, growth in . . 349
„ ruptured stomach of . . 347
Duckworth (Dr.), biliary calculus passed from the umbilicus . 157
Ductus arteriosus deficient . . 88
Dysentery, acute, recent specimens of, from Sedan 142

Ear, diseases of . . . . . —
„ keloid tumours from the . . 313
Embolism of carotid and vertebral arteries, sudden death from . 119
„ of left middle cerebral artery, &c. 13
Encephaloid disease of the kidneys 173
Endocardium, cancerous growths on 125
Epithelioma of head and lungs secondary to that of clitoris . . . 231
„ columnar, of the liver . . 164
„ cystic, of the cheek . . . 202
Epulis tumours of the jaw . . 256
Ether spray, effects of, on the skin, in Addison's disease . . . 317
Exostosis, ivory, growing from sclerotic coat of the eye . . . 227
Exostoses, large and multiple, of cranium 204

Digitized by Google

Eye, diseases of . . . 218-228
„ demonstration of diseases of . 221
„ bony deposit in the . . . 225
„ ditto, causing sympathetic ophthalmia 226
„ ivory exostosis growing from sclerotic coat of 227
Eyeball, gliomatous disease of, with deposits in facial and cranial bone 218

Fagge (Dr. H.), embolism of left middle cerebral artery, yellow induration of the corpus striatum, with surrounding white softening . . 13
„ skin and liver from a case of diffused scleriasis 309
Fatty masses contained in a ranula. 258
Fever, enteric, with constipated bowels, fatal by intestinal hæmorrhage 144
Fibroma from inferior costa of scapula. 194
Fibula, malignant osteoid tumour of 214
„ medullary sarcoma of . . 212
Fistula, biliary in abdominal parietes discharging bile . . . 152
„ ditto, gall-stones discharged by 154
Foot, fungus, of India . . . 320
Foster (Mr. John), see *Thompson*.
Fox (Dr. Tilbury), keloid tumour from the ear 313
„ case of Devergie's pityriasis pilaris. 313
„ fungus foot of India. . . 320
„ *report* on ditto by Dr. Bristowe 320
Fracture of head of radius . . 205
Fungus foot of India . . . 320

Gall-stones, see *Calculus* (biliary).
Gall-bladder, fistulous communication with colon 158
„ malformation of . . . 163
Gay (Mr. John), double subclavio-axillary aneurism, ligature of right subclavian, death from bronchitis and pulmonary congestion . 111
„ myxoma 269
Generation, organs of, diseases, &c. of. 182-187
Glands, ductless, diseases of 274-304
„ lumbar, tumour of the . . 287
Gliomatous disease of eyeball, with secondary deposits in periosteum of facial and cranial bones . . 218
Gout in the stomach, case of, and phlegmonous colitis . . . 139
Green (Dr. Henry), aneurism of a branch of the pulmonary artery in a phthisical lung . . . 37
„ *report* on Mr. Morris's case of sarcoma of the fibula . . . 214
Greenhow (Dr. E. H.), spinal cord from a case of motor ataxy . 14
„ cancer of the œsophagus, with fistulous opening into the trachea. 129
Growths, see *Tumours*.
Gunshot injuries of bone . . 199

Hæmoptysis, fatal, cases of, in advanced phthisis 41
„ *table* of cases 58
Hæmorrhage into cellular tissue, with thickening of parts, in scrotal tumour 184
„ intestinal, fatal, in a case of enteric fever 144
„ fatal, from simple ulcer of the stomach 141
Hæmothorax in a case of pleurisy . 117
Hand, completely flayed by machinery 346
Hawkes (Dr. John), rupture of aorta, tumour of brain . . . 115
„ *report* on ditto, by Dr. Dickinson and Dr. Powell . . . 116
Head, dislocation of, forwards in caries of vertebræ, &c. . . . 188
Heart, epithelioma of . . . 231
„ malformation of the . 92, 95
„ — cases of 85
„ fibrous tumour of . . . 121
„ see *Ventricles, Auricles*.
„ and lungs of a porpesse . . 347
Heath (Mr. C.), sacculated aneurism of the arch of the aorta, simulating aneurism of the innominate . 95
„ procidentia uteri, with ovarian cyst 186
„ fibro-cystic tumour from the axilla 233
„ lipoma of nose . . . 242
Hepatic duct, malformation of . 163
Hernia, strangulated femoral, reduction en masse 148
„ direct inguinal, in the female . 148
Hill (Mr. J. D.), fibroma from inferior costa of scapula and aponeurosis of subscapular muscle . . 194
Hip-joints, destructive and reparative processes in two . . . 198
Hodgkin's disease or lymphadenoma 70
„ with acute tuberculosis . . 278
Holmes (Mr. T.), see *Martyn*.

Digitized by Google

HULKE (Mr.), polypus of the rectum 146
„ scirrhus beginning in lower lip and extending to the jaw . . 248
„ *report* on Mr. Wagstaffe's case of cystic sarcoma of lower jaw . 252
„ cases of rodent ulcer . . 326
Hyperostosis with large exostoses of the skull 204

India, fungus foot of . . . 320
INTESTINES, diseases of . 128-151
Intestines, constipated in a case of enteric fever, fatal by intestinal hæmorrhage 144

Jaundice, from gall-stones, and acute atrophy of liver, &c. . . 159
Jaw, epulis tumours of . . . 256
„ upper, tumour of . . . 255
„ lower, cystic sarcoma of . . 249

KELLY (Dr.), malformation of the heart, transposition of the great vessels, cyanosis 92
„ malformed heart, defective septum ventriculorum . . . 95
„ necrosis of the patella . . 198
Keloid tumours from the ear . 313
KIDNEYS, BLADDER, &c., diseases of 171-181
Kidney, atrophied, causing fatal uræmia 177
„ medullary cancer of left . . 171
„ cyst connected with left . . 171
„ encephaloid disease of . . 173
„ unnatural extension of . . 174
„ lymphadenoma of . . . 68
„ syphilitic deposits in . . 33

Lardaceous disease, General Report of the Committee upon . . 1-12
Larynx, cancer of 132
„ paralysis of left side of . . 137
„ of a dog, growths in . . 349
LAWSON (Mr. G.), a hand completely flayed by machinery . . 346
Leg, recurrent tumour of the front of 243
LIEBREICH (Dr.), *per Dr. Dickinson*, demonstrations of diseases of the eye 221
Ligament, transverse, ulceration of from caries of vertebræ, &c. . . 188
Lip, lower, scirrhus beginning in, and extending to jaw . . . 248
Lipoma of nose 242
Liver, composition of healthy human 6
„ composition of healthy sheep's . 6
Liver, composition of the aqueous extract of 7
„ examination of the precipitate obtained by addition of iodine to healthy sheep's liver and a human lardaceous and fatty liver . 9
„ &c., diseases of . . 152-170
„ acute atrophy of, with puriform deposits 159
„ cancer of 137
„ cancerous growths in . . 125
„ medullary cancer of . . . 171
„ columnar epithelioma of . . 164
„ lardaceous disease of, report of Committee on 1-12
„ — saline constituents of healthy and lardaceous 3
„ lardaceous, cholesterine in . 5
„ — character of those, also fatty 5-7
„ syphilitic deposits in . . 33
Lungs, cancer of . . . 132, 137
„ medullary cancer of . . . 171
„ epithelioma of 231
„ phthisical, aneurism of a branch of the pulmonary artery in . . 37
„ secondary. scirrhous, or fibro-cancerous infiltration of connective tissue of 76
„ and heart of a porpesse . . 347
Lymphadenoma 70
„ of the mediastinum and kidneys 68
LYMPHATIC GLANDS, diseases of 287-304
Lymphatic glands, cancer of . . 132
„ cancerous growths in . . 125
„ of the thorax, cancer of . . 137
Lymphoma, large, in the pectoral region 230
MACCORMAC (Mr. W.), *per Dr. Quain*, gunshot injuries of bone . . 199
Machinery, hand completely flayed by 346
MACKENZIE (Dr. Morell), constriction of the trachea, syphilitic deposits in the liver and kidney . . 33
„ growths in the larynx of a dog 349
Madura foot 320
Malformation of the heart, cases of 85
„ — cyanosis 92
„ — ditto 95
Malignant disease, see *Cancer*.
Mammary tumour, see *Tumours*.
MARCET (Dr.), chemical reports on lardaceous disease of the liver (in report of the Committee) . 3-12
MARTYN (Dr.), *per Mr. Holmes*, exostosis 253
MASON (Mr. F.), papillary growth of abdominal walls . . . 229

Digitized by Google

Mediastinum, lymphadenoma of . 68
Mesenteric tumour . . . 296
Mitral valve, old disease of, in case of sudden death from embolism . 119
Moles, pedunculated growth of the skin developed from . . . 314
MORRIS (Mr. H.), venous vascular tumour of cerebrum . . . 22
„ strangulated femoral hernia, reduction en masse . . . 148
„ medullary sarcoma of fibula . 212
„ *report* on ditto by the Committee 214
„ see *Shout*
MORRIS (Mr.), of Petworth, *per Mr. Henry Morris*, cysts of left kidney, with medullary cancer of liver, &c. 171
MOXON (Dr.), peculiar pneumonia in a syphilitic subject . . . 38
„ case to show identity of gray and yellow tubercles . . . 66
„ case of gout in the stomach, and phlegmonous colitis . . 139
„ osteo-colloid cancer of the skeleton 206
„ *report* on ditto by the Committee 210
„ case of acute splenitis in a syphilitic 274
MURCHISON (Dr.), case of paralysis agitans 24
„ *report* on ditto by Dr. Cayley . 25
„ case of diphtheria, with extension of the membrane to the bronchial tubes 35
„ lymphadenoma of the mediastinum and kidneys 68
„ sudden death from embolism of the carotid and vertebral arteries, chorea, and old mitral disease . . 119
„ case of enteric fever with constipated bowels, fatal by intestinal hæmorrhage on the twenty-seventh day 144
„ concretions in the appendix vermiformis, causing ulceration, perforation, and fatal peritonitis . 146
„ biliary fistula in the abdominal parietes discharging bile . 152
„ sequel of a case of gall-stones discharged by a fistulous opening through abdominal parietes . 154
„ fistulous communication between the gall-bladder and colon . . 158
„ jaundice from gall-stones, followed by acute atrophy of the liver, with puriform deposits . . . 159
MURCHISON (Dr.), atrophied kidneys, causing fatal uræmia . . 177
„ *report* on Dr. Sutton's case of supposed smallpox at the time of birth 345
MURRAY (Dr. John), recent specimens of acute dysentery from Sedan 142
Muscle, subscapular, aponeurosis of 194
Myeloid tumour of the head of the tibia 210
Myxoma 269

Necrosis of the patella . . . 198
Nerve, left recurrent laryngeal, cancer of 137
Nerve, posterior tibial, spindle-celled sarcoma connected with . . 18
NERVOUS SYSTEM, diseases of 13-32
Nose, lipoma of 242

Œsophagus, cancer of the, with fistulous opening into the trachea . 129
„ — a free communication between œsophagus and trachea . . 134
„ simple stricture of . . . 128
OGLE (Dr. W.), *per Dr. Whipham*, lungs and heart of a porpesse . . 347
Ophthalmia, sympathetic, from bony deposit in the eye . . . 226
ORGANS OF SPECIAL SENSE, diseases, &c., of 218-28
OSSEOUS SYSTEM, diseases, &c., of 188-217
Osteo-colloid cancer of the skeleton 206
Ovarian cyst, and procidentia uteri . 186

Palate, hard fibrous tumour of . 272
Papillary growth of abdominal walls 229
Paralysis of left side of larynx . 137
„ of left vocal cord . . . 134
Paralysis agitans, case of (Dr. Murchison) 24
Patella, necrosis of the . . . 198
PAYNE (Dr.), cancerous growths on endocardium, in liver, lymphatic glands, &c., thrombus in iliac vein 125
„ morbid growths in the spleen, &c., Hodgkin's disease, with acute tuberculosis 278
„ Addison's disease, pigmentation of pia mater, spinal chord, and skin of genitals 281
„ cancer of the thyroid body, subsequent to bronchocele . . 283
„ history of the case by Dr. Sieveking 354
„ *report* on ditto by Dr. Bristowe and Mr. Pick . . . 286

Digitized by Google

PAYNE (Dr.), two cases of pyæmia 332
„ cysts containing air from the peritoneum 336
PEACOCK (Dr.), cases of malformation of the heart 85
Peritoneum, cysts containing air from the 336
„ thickened, in a case of cancer of imperfectly descended testis . 182
Peritonitis, fatal, from concretions in appendix vermiformis . . 146
Pharynx, cancer of 132
Phthisis, cases of fatal hæmoptysis in advanced 41
„ *table* of cases 58
PICK (Mr.), *report* on Dr. R. Bennett's case of secondary scirrhus of the lung 82
„ *report* on Dr. Payne's specimen of tumour of thyroid . . . 286
„ *report* on Dr. Dickinson's tumour of the lumbar glands . . . 293
„ *report* on Dr. Dickinson's mesenteric tumour 302
Pityriasis pilaris (Devergie's), case of 313
Pleurisy with hæmothorax, complicated by ulceration of tricuspid valve, &c. 117
Pneumonia, peculiar, in a syphilitic subject 38
Polypus of the rectum 146
Porpesse, lungs and heart of, bifid condition of heart, &c. 347
POWELL (Dr. D.), cases illustrating the pathology of fatal hæmoptysis in advanced Phthisis 41
„ *table* of cases 58
„ see *Quain* (Dr.).
„ *report* on Mr. W. Whitehead's case of peculiar sputum 84
„ *report* on Dr. Hawkes' case of rupture of aorta 116
Puriform deposits in acute atrophy of the liver 159
Pyæmia, two cases of 332

QUAIN (Dr.), *per Dr. D. Powell*, caries of the vertebræ, with dislocation of the axis 192
„ see *McCormac*, *Silver*.

Radius, fracture of head of . . 205
Ranula, fatty masses contained in a 258
Rectum, polypus of 146
Reduction *en masse*, in strangulated femoral hernia 148
Regeneration, see *Bone*.
Renal disease, see *Kidneys*.
Resection, see *Excision*.
RESPIRATION, organs of, diseases, &c., of 33-84
Rodent ulcer, cases of 326

SANDERSON (Dr. B.), *report* on Mr. Morris's case of sarcoma of the fibula 214
Sarcoma, cystic, of lower jaw . 249
„ medullary, of cranial bones associated with scirrhus of the breast . 260
„ — of fibula 212
„ spindle-celled, connected with the posterior tibial nerve . . 18
Scapula, fibroma from inferior costa of 194
Scirrhous infiltration of connective tissue of lung 76
Scirrhus of the brain and breast with aphasia 261
„ of breast, medullary sarcoma of cranial bones, associated with . 260
„ beginning in lower lip and extending to the jaw 248
„ see *Cancer*.
Scleriasis, diffused, skin and liver, from a case of 309
Sclerotic coat of the eye, ivory exostosis growing from 227
Scrotal tumour, hæmorrhage into cellular tissue, &c. 184
SENSE, ORGANS OF SPECIAL, diseases, &c., of 218-228
Septum ventriculorum, defective . 95
SHOUT (Mr.), *per Mr. H. Morris*, aneurism of abdominal aorta which had burst into the peritoneal cavity 104
SIBLEY (Mr.), *report* on Mr. Wagstaffe's case of cystic sarcoma of lower jaw 252
„ *report* on Mr. West's case of tumour of upper jaw 256
SIEVEKING (Dr.), history of Dr. Payne's case of cancer of thyroid body 354
SILVER (Dr.), *per Dr. Quain*, Addison's disease 280
SKIN, diseases of 305-319
Skin, &c., pigmentation of, in Addison's disease 281
„ compound pedunculated growths of, developed from moles . . 314
„ effects of ether spray on, in Addison's disease 317
Skull, see *Cranium*.
Smallpox, supposed case of, at time of birth 343

Digitized by Google

SMITH (Dr. Heywood), unnatural extension of kidney . . . 174
SMITH (Mr. T.), large cystic tumour of breast, with scirrhous carcinoma with calcareous degeneration . 267
„ *report* on ditto by the Committee 268
Softening, white, surrounding yellow induration of corpus striatum . 13
SPECIMENS, MISCELLANEOUS 320-346
SPECIMENS FROM THE LOWER ANIMALS 347-353
Spinal cord from a case of motor ataxy 14
„ changes of, in tetanus . . 27
SPLEEN, diseases of . . 274-279
Spleen, enlarged 276
„ morbid growths in, Hodgkin's disease, &c. 278
Splenitis, acute, in a syphilitic . 274
Sputum, peculiar 82
SQUIRE (Mr.), direct inguinal hernia in the female 148
„ specimen of enlarged spleen . 276
STOMACH, INTESTINES, &c., diseases of 128-151
Stomach, cancer of . . . 137
„ gout in the 139
„ ruptured, of dog . . . 347
„ ulcer of the, fatal hæmorrhage from 141
Stomach-pump, employment of, in a case of cancer of œsophagus, &c. . 134
Stricture, see *Œsophagus*.
SUPRA-RENAL CAPSULES, diseases of 280-283
Supra-renal capsules, Addison's disease 280
„ ditto, pigmentation of pia mater, spinal cord and skin of genitals 281
„ effects of ether spray on the skin in Addison's disease of . . 317
SUTTON (Dr.), autopsy and microscopical examination in Dr. Bennett's case of lymphadenoma . . . 73
„ microscopical examination of Dr. Bennett's case of fibro-cancerous infiltration of connective tissue of lung 80
„ supposed case of smallpox at time of birth 343
„ *report* on ditto by Dr. Murchison and Dr. Bastian . . . 345
Syphilitic deposits in the liver and kidney 33
Syphilitic subject, peculiar phenomena in 38
„ acute splenitis in . . . 274
TAY (Mr. Waren), fatty masses contained in a ranula . . . 258
Testis, cancer of imperfectly descended 182
Tetanus, changes of the spinal cord in 27
Thickening, inflammatory, of parts, in a case of scrotal tumour . . 184
THOMPSON (Mr. Joseph) *per Mr. John Foster*, tumour of breast . 230
Thrombus, organized, perhaps cancerous in iliac vein 125
Thymus, enlarged, &c. . . . 70
Thyroid body, cancer of, subsequent to bronchocele 283
Tibia, myeloid tumour of the head of the 210
TONGUE and DIGESTIVE CANAL, diseases, &c., of 128-151
Tongue, cancer of 128
Trachea, free communication between œsophagus and . . . 134
„ constriction of the . . . 33
„ fistulous opening into the . 129
Tricuspid valve, ulceration of, in a case of pleurisy with hæmothorax . 117
TROTTER (Mr. J. W.), encephaloid disease of the kidneys . . 173
Tubercles, case to show identity of gray and yellow 66
Tuberculosis, acute, with morbid growths in the spleen, &c. . . . 278
TUMOURS, &c. 229-73
Tumour of breast 230
„ of the upper jaw . . . 255
„ of the lumbar glands . . 287
„ mesenteric 296
„ scrotal, hæmorrhage into cellular tissue, &c. 184
„ cystic, of breast, with scirrhous carcinoma 267
„ epulis, of the jaw . . . 256
„ fibrous, of the heart . . . 121
„ hard fibrous, of the palate . 272
„ fibro-cystic, from the axilla . 233
„ keloid, from the ear . . . 313
„ myeloid, of the head of the tibia 210
„ malignant osteoid, of fibula . 214
„ recurrent, of front of the leg (spindle-celled sarcoma) . . . 243
„ venous vascular, of the brain . 22

Ulcer of the stomach, fatal hæmorrhage from 141
„ of transverse ligament, from caries of vertebræ, &c. . . . 188
„ rodent, cases of . . . 326

Digitized by Google

Umbilicus, biliary calculus passed from 157
Uræmia, fatal, caused by atrophied kidneys 177
URINARY ORGANS, diseases, &c., of 171-181
Uterus, procidentia of, with ovarian cyst 186

Valve, see *Mitral, Tricuspid.*
VASCULAR SYSTEM, diseases, &c., of 85-127
Vein, iliac, organized thrombus, perhaps cancerous in 125
Ventricles, defect in the septum of 88
Vertebræ, cancerous growths in body of 125
„ caries of, with dislocation of the axis 192
„ — causing ulceration of transverse ligament 188
Vessels, transposition of the great . 92
Vocal cord, left, paralysis of . . 134

WAGSTAFFE (Mr,), fibrous tumour of the heart 121
„ cystic sarcoma of lower jaw . 249
„ *report* on ditto by Mr. Sibley and Mr. Hulke 252
WALKER (Dr. Swift), *per Mr. Spencer Watson*, recurrent tumour of the front of the leg (spindle-celled sarcoma) 243
„ subsequent history of the case . 245
„ *report* on ditto by Dr. Church . 246
WATSON (Mr. Spencer) gliomatous disease of eyeball with deposits in periosteum of facial and cranial bones 218
WATSON (Mr. Spencer), bony deposit in the eye, and peculiar deposit in the cornea 225
„ — causing sympathetic ophthalmia 226
„ ivory exostosis growing from sclerotic coat of the eye . . . 227
„ cystic epithelioma of the cheek . 262
„ *report* on ditto by Dr. Church . 263
„ see *Walker* (Swift).
WEST (Mr. J. F.), tumour of the upper jaw 255
„ *report* on ditto by Mr. Sibley . 256
WHIPHAM (Dr.) dissecting aneurism of the first portion of the arch of the aorta 113
„ pleurisy with hæmothorax, complicated by ulceration of the tricuspid valve, and consequent destruction of many of the chordæ tendineæ . 117
„ columnar epithelioma of the liver 164
„ *report* on ditto by the Committee 169
„ ulceration of transverse ligament from caries of vertebræ, &c. . 188
„ see *Ogle* (W.).
WHITEHEAD (Mr. W.), peculiar sputum 82
„ *report* on, by the Committee on Morbid Growths (Dr. Powell and Mr. Arnott) 84
WILKS (Dr.), see *Committee* on Lardaceous Disease.
WILLIAMS (Dr. C. T.), aneurism of the arch of the aorta bursting into the œsophagus 102
Wounds, gunshot of bone . . 199
Wrist, congenital dislocation of . 197

PRINTED BY J. E. ADLARD, BARTHOLOMEW CLOSE.

Digitized by Google

Digitized by Google

Digitized by Google

UNIVERSITY OF MICHIGAN
3 9015 04774 9521

Digitized by Google

Digitized by Google